
Skeletal Class II open-bite malocclusion with idiopathic condylar resorption: a case report

Ayaka Oka,* Hiroshi Kurosaka,* Kohtaro Yashiro,* Seiji Haraguchi,* Donghoon Lee,* Tomonao Aikawa,† Mikihiko Kogo† and Takashi Yamashiro*
Department of Orthodontics and Dentofacial Orthopedics* and The First Department of Oral and Maxillofacial Surgery,†
Osaka University Graduate School of Dentistry, Osaka, Japan

Background: The orthodontic treatment of patients with idiopathic condylar resorption (ICR) remains controversial. The effect of molar intrusion using temporary anchorage devices (TADs) and the consequential gradual counterclockwise rotation of the mandible in patients with ICR remains unclear.

Aims: To present the long-term treatment result of an adult skeletal Class II open-bite malocclusion with a history of ICR corrected by the combination of orthognathic surgery and TADs.

Methods: After six months of occlusal splint therapy, a surgically-assisted intrusion of the maxillary molars was performed using TADs, followed by a bilateral sagittal split osteotomy (BSSO) and genioplasty.

Results: The five-year post-treatment records showed a good facial appearance, occlusion and mandibular/condylar position with no progress in the condylar resorption.

Conclusion: Based on a single case, this treatment option is an effective alternative to a bimaxillary osteotomy for patients presenting with ICR.

[Aust Orthod J 2018; 34: 85-93]

Received for publication: June 2017

Accepted: November 2017

Ayaka Oka: aina@dent.osaka-u.ac.jp; Hiroshi Kurosaka: kurosaka@dent.osaka-u.ac.jp; Kohtaro Yashiro: yashiro@dent.osaka-u.ac.jp; Seiji Haraguchi: shara@orthobrain.com; Donghoon Lee: lee@dent.osaka-u.ac.jp; Tomonao Aikawa: aikawat@dent.osaka-u.ac.jp; Mikihiko Kogo: kogo@dent.osaka-u.ac.jp; Takashi Yamashiro: yamashiro@dent.osaka-u.ac.jp

Introduction

The orthodontic treatment of patients with idiopathic condylar resorption (ICR), also known as progressive condylar resorption (PCR), remains controversial.¹⁻³ Because most patients with ICR have a high mandibular plane angle and a progressively retruding chin, it has been suggested that optimal aesthetic and functional results are achieved by bimaxillary surgery incorporating a counterclockwise rotation of the maxillomandibular complex and advancement of the mandible.¹ However, several reports have noted that a large mandibular advancement, counterclockwise rotation and the posterior repositioning of the condyle were associated with an increased risk of condylar resorption (CROS).^{1,4,5} The reports indicate that increased postoperative stress to the

temporomandibular joints (TMJs) could initiate or accelerate the condylar effects.^{1,2,4-6}

Descriptions of treatment in order to manage ICR have included splint therapy,⁶ maxillary surgery alone,⁶ and two-jaw orthognathic surgery with a condylectomy.^{1,2} However, further investigation is necessary to establish a treatment protocol that can result in an ideal facial profile and occlusion with minimal postoperative stress to the TMJs.

Alternatively, the effect of molar intrusion using temporary anchorage devices (TADs), which induce a gradual counterclockwise rotation of the mandible in patients affected by ICR, is uncertain. Several publications have indicated that molar intrusion using TADs is effective in treating patients with temporomandibular disorders.⁷⁻⁹

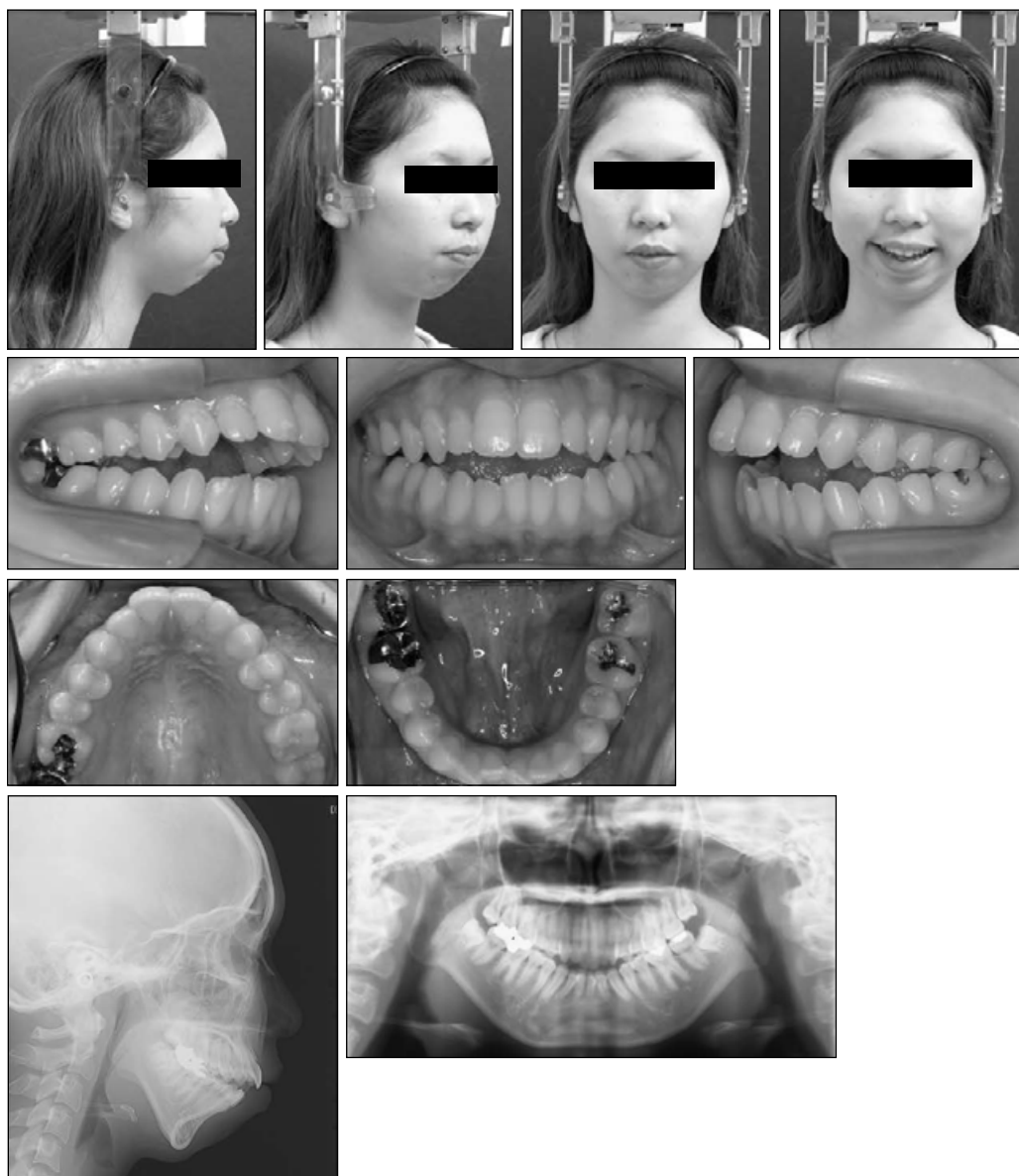

Figure 1. Pretreatment photographs and radiographs.

The present case report describes the successful treatment of an adult patient who presented with a skeletal Class II open-bite malocclusion and revealed a history of ICR. A surgically-assisted intrusion of the maxillary molar was performed using TADs, followed by a bilateral sagittal split osteotomy (BSSO) and genioplasty. By using this method, the gradual intrusion of the upper molars was achieved, which allowed optimal autorotation of the mandible and reduced the surgical movement of the mandible via the BSSO. The post-treatment records after five years of retention showed a good facial appearance, occlusion and mandibular/condylar position with no progress in the condylar resorption.

Diagnosis and etiology

A female patient, 19 years and one month of age, was referred to the orthodontic department in order to manage a skeletal Class II malocclusion with an anterior open bite. The chief complaints were her facial aesthetics related to a lack of chin prominence and the inability to occlude her anterior teeth. There was no remarkable medical history. The patient exhibited a severe retrognathic and convex facial profile (Figure 1). Lip incompetence at rest position was obvious, and hypertonicity of the perioral musculature was noted upon lip closure. Differences were apparent between the mandibular position at the initial contact

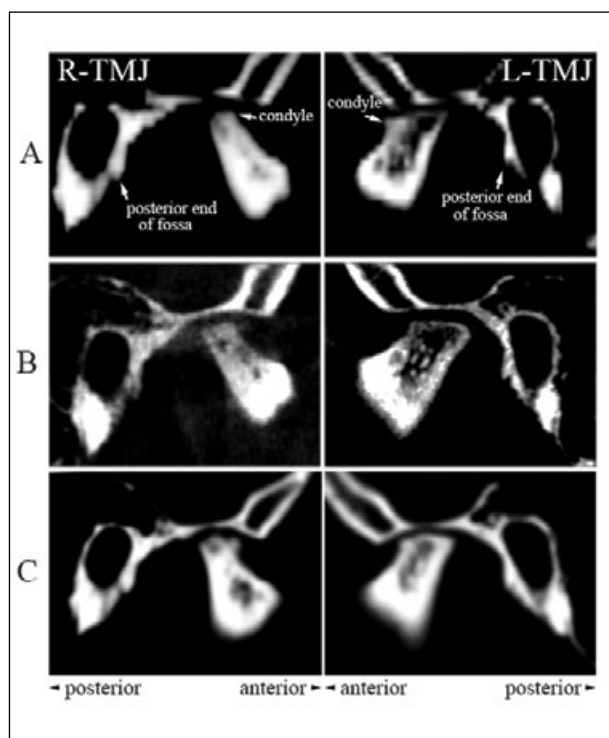


Figure 2. Sagittal CT images of the TMJ (A) pretreatment; (B) post-active treatment; (C) post-five-year retention.

of the teeth when the condyle was in centric relation (CR) and at the habitual maximal intercuspal position (centric occlusion; CO). At CR, the mandible was displaced posteriorly. Computed tomography (CT) showed a dramatically shortened and flattened condyle with irregular articular surfaces and bilateral lipping of the margin (Figure 2A). The MRI showed anteriorly displaced disks. A lateral cephalometric analysis indicated a significantly retruded mandible (SNB angle, 72.3°) and a well-positioned maxilla (SNA angle, 82.9°), indicating a skeletal Class II relationship (ANB angle, 10.6°). A hyper-divergent profile was evident with a high mandibular plane angle (FMA, 51.8°) and a facial height ratio of 50.0%. The upper incisors were normally inclined (U1 to FH angle, 109.9°), while the lower incisors were proclined (FMIA angle, 31.7° ; IMPA angle, 96.5°). The panoramic radiograph revealed no missing teeth or sign of root resorption (Figure 1). The patient had no history of oral-facial trauma. She recognised that some symptoms, including the anterior open bite and a retrognathic appearance, had worsened during adolescence, but that stability was evident over the past three years. A clinical exam showed no sign of PCR and the patient was negative for diagnostic markers of rheumatoid arthritis.

Treatment objective

The main treatment objectives were to (1) correct the Class II relationship with the associated anterior open-bite malocclusion, and (2) improve the facial aesthetics.

Treatment alternatives

The first treatment option was bimaxillary surgery, involving the impaction of the maxilla by a Le Fort I procedure and a resultant counterclockwise rotation/advancement of the mandible by a bilateral sagittal splitting osteotomy (BSSO) or by distraction osteogenesis. However, maxillary molar intrusion using TADs and a corticotomy was considered followed by a BSSO and genioplasty. The patient wanted to avoid conventional bimaxillary surgery because of the invasiveness of the individual surgical procedures. It was decided to perform upper molar intrusion using TADs to induce autorotation of the mandible before a BSSO in order to reduce the level of the advancement and rotation of the mandible. A corticotomy was planned to enhance the intrusion of the upper molars. The patient was advised and understood the risks associated with treatment and agreed to the orthognathic treatment plan.

Treatment plan and progress

An occlusal splint was placed for six months before the commencement of active orthodontic treatment to achieve optimal repositioning of the condyle within the glenoid fossae and to monitor occlusal and skeletal changes. Orthodontic treatment began at the age of 19 years seven months with 0.022 inch pre-adjusted edgewise appliances after extractions of the first premolars in both arches as well as the lower third molars. At the age of 19 years 10 months, a bilateral maxillary posterior corticotomy was performed (Figure 3A)¹⁰⁻¹² during which the upper third molars were extracted. At the age of 21 years and seven months, a BSSO was performed. The mandible was repositioned anteriorly by 8.0 mm on both sides, and with a 5° counterclockwise rotation (Table I). Rigid fixation was applied between the mandibular bone segments. TADs were also placed on the buccal aspect of the lower first molars in order to use intermaxillary fixation. All appliances were removed at age 22 years four months (Figure 4). After active treatment, a tooth positioner and wrap-around type of retainers were

Table 1. Cephalometric analysis at pretreatment, pre-one-jaw-surgery, postactive treatment, and post-retention stages.

Measurement	Pretreatment (19 y, 1 mo)	Pre-one-jaw surgery (21 y, 7 mo)	Postactive treatment (22 y, 4 mo)	Post-5-year- retention (27 y, 4 mo)	Normative mean* (adult, female)	
					Mean	SD
<i>Angular (degrees)</i>						
SNA	82.9	81.8	81.8	81.8	80.8	3.6
SNB	72.3	69.3	74.3	74.0	77.9	4.5
ANB	10.6	12.5	7.5	7.8	2.8	2.4
FMA	51.8	52.4	47.3	48.0	30.5	3.6
IMPA	96.5	82.5	82.3	84.0	93.4	6.8
FMIA	31.7	45.1	50.4	48.0	56.0	8.1
U1-FH	109.9	103.7	102.0	103.0	112.3	8.3
IIA	101.8	121.3	128.4	125.0	123.6	10.6
<i>Linear (mm)</i>						
N-Me	131.4	129.9	134.6	134.6	125.8	5.0
N/PP	54.0	54.0	54.0	54.0	56.0	2.5
Me/PP	70.9	67.3	77.8	77.8	68.6	3.7
Ptm-A/PP	55.2	55.2	55.2	55.2	41.8	2.8
Ar-Me	96.1	90.8	108.1	107.9	106.6	1.1
U6/PP	24.4	21.3	21.3	21.3	25.2	2/7
Overjet	9.0	10.9	2.0	2.2	3.1	1.1
Overbite	-6.0	0.0	2.0	1.5	3.3	1.9

*Japanese normative mean (Wada et al., 1977) A = subspinale; Ar = articulare; B = supramentale; FH = Frankfort horizontal; FMIA = Frankfort mandibular incisor angle; FMFA = Frankfurt mandibular plane angle; IIA = interincisal angle; IMPA = incisor mandibular plane angle; MASDO = maxillary anterior segmental distraction osteogenesis; Me = menton; N = nasion; PP = palatal plane; Ptm = pterygomaxillary fissure; S = sella; U1 = upper incisor plane.

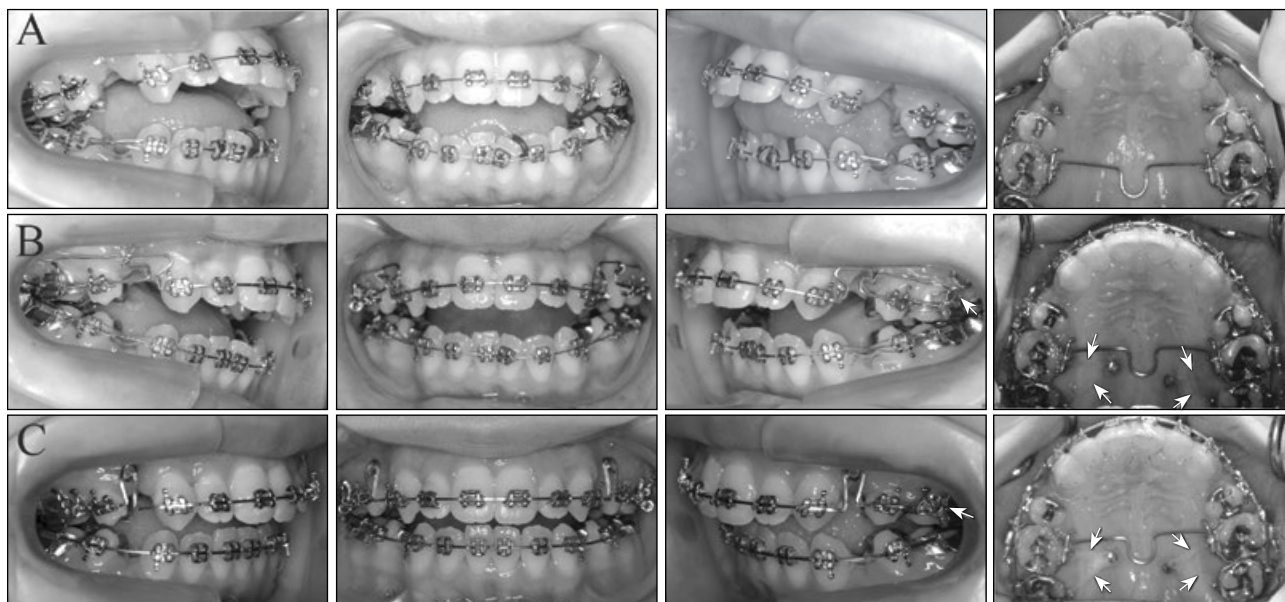


Figure 3. Intraoral photographs (A) just before corticotomy; (B) one month after corticotomy; (C) two months after corticotomy. White arrows shows the placement of elastics.

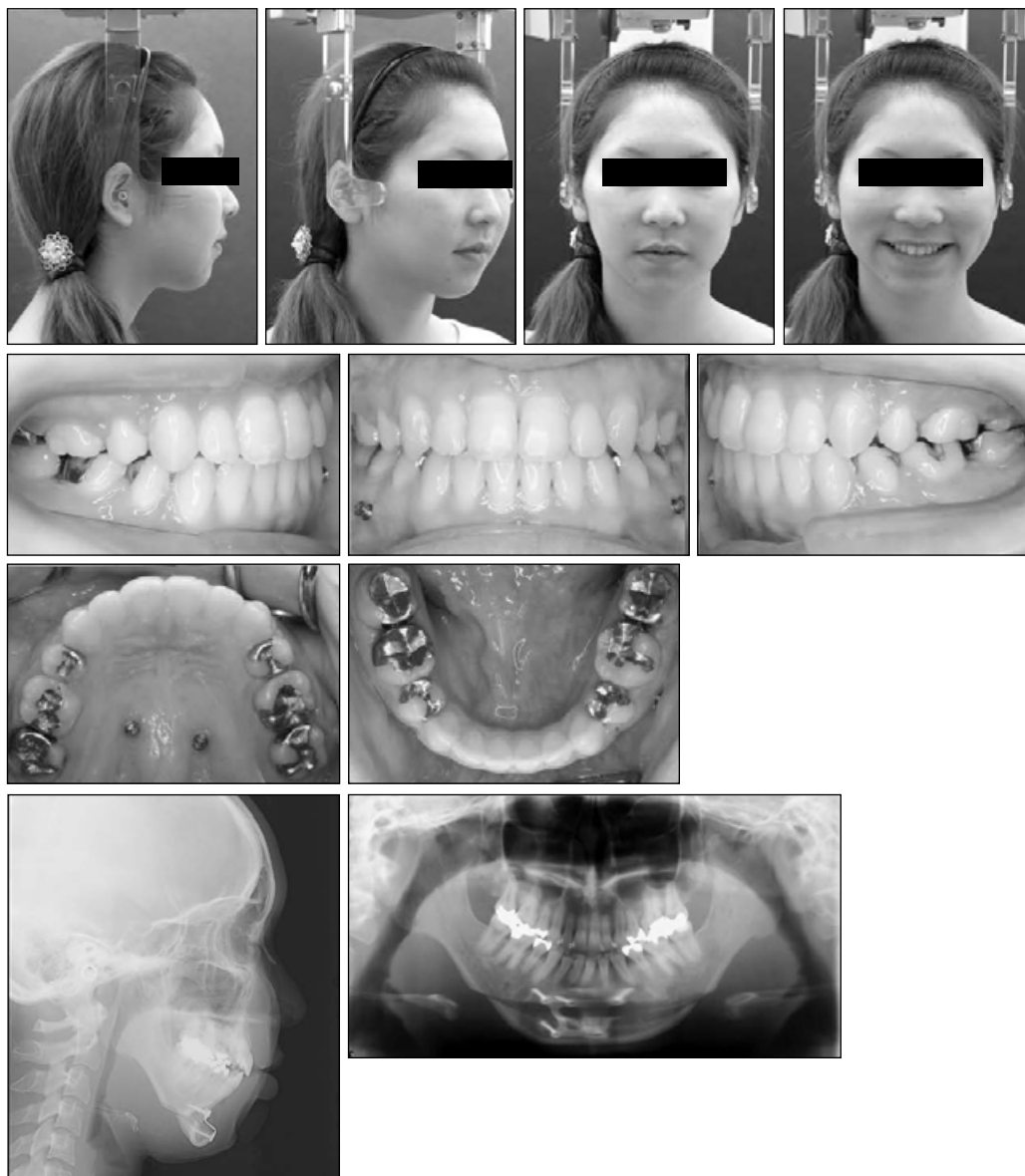

Figure 4. Post-active treatment photographs and radiographs.

delivered. A gum-chewing exercise was prescribed for 15 minutes daily and lip closure training was also employed to strengthen the masticatory muscles, with the expectation that natural retention would be reinforced in the long term. A genioplasty was performed at 22 years three months to advance pogonion by 9 mm.

Surgical procedure

The corticotomy and extraction of the upper third molars were performed under general anaesthesia. Mucoperiosteal incisions were located on the buccal

aspects of the upper premolars and molars and a horizontal osteotomy was performed 5 mm above the apices of the molars. Vertical bone cuts were made on the lateral side of the upper first premolars as well as at the distal portion of the upper molars at the site of the third molar extraction. An adequate bone gap was created to decrease obstruction between the bone edges during impaction. Anchorage plates (SMAP System; Dentsply Sankin, Tokyo, Japan) were attached on the buccal aspect between the first and second molars in the upper arch. The horizontal palatal bone cuts were carried through the buccal osteotomy spaces. Two miniscrews (1.6 mm diameter,

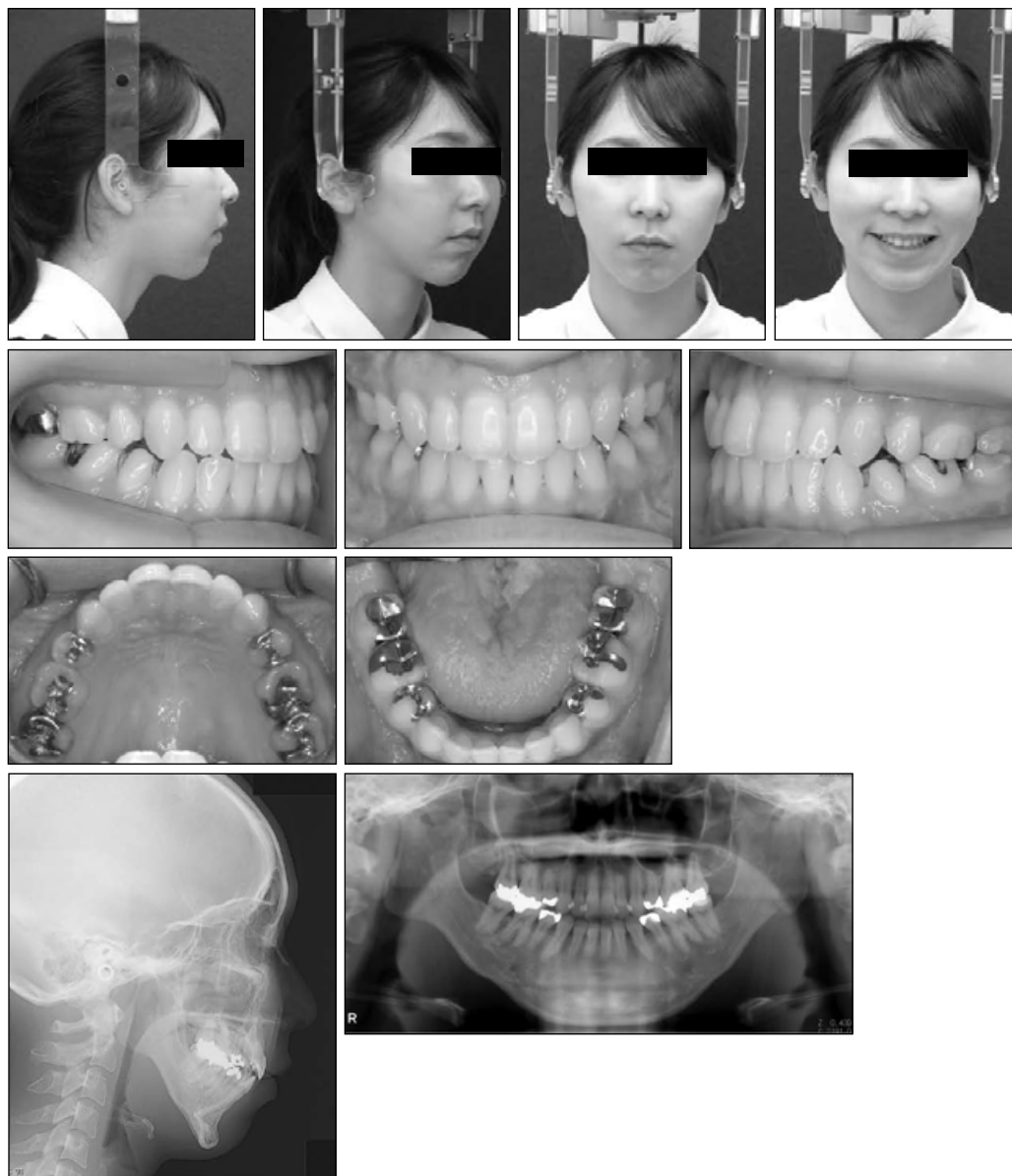


Figure 5. Post-five-year retention photographs and radiographs.

8 mm length; Dualtop autoscrews; Proceed Co. Ltd, Tokyo, Japan) were inserted on the palatal aspect as shown in Figure 3B. The miniplates and screws were loaded two weeks after the surgery to reposition the corticotomised posterior segment with a force of 200 g using 0.019 × 0.025 beta-titanium archwires and elastics (Figures 3B and 3C).

Treatment results

At the completion of treatment, the hyper-divergent profile had considerably improved. Class I canine and molar relationships and normal overjet and overbite

relationships were obtained (Figure 4). The intruded upper molars produced no gingival recession or periodontal damage. Minor root resorption of the upper incisors was evident (Figure 4). Cephalometric analysis and superimposition showed a 3.0 mm impaction of the posterior maxilla and a 5.0° auto-rotation of the mandible prior to the BSSO. The 8.0 mm advancement of the BSSO and 9.0 mm advancement genioplasty also improved the prominence of the chin. Uprighting of the lower incisors was achieved by 9.0° of lingual tipping (Table I).

After a five-year retention period, ideal occlusion as well as the profile had been well maintained (Figure

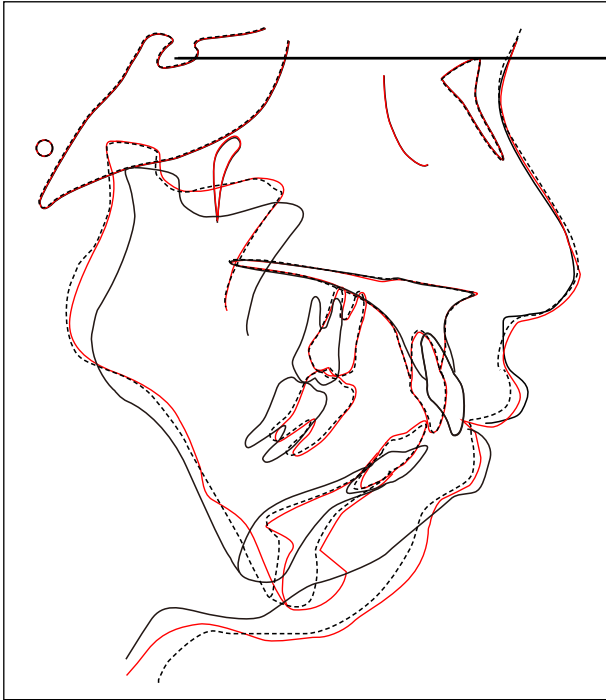


Figure 6. Superimposed lateral cephalometric tracings on the SN plane at S; pretreatment (solid line), post-active treatment (red line) and post-five-year retention (dotted line).

5). A slight relapse was noted in the proclination of the upper and lower incisors, curve of Spee in the lower arch, and crowding of the lower incisors. Minimal change was identified in the BSSO surgical effects and the maxillary molar intrusion (Figure 6 and Table I). Partial bone resorption occurred in the anterior segment advanced by the genioplasty (Figure 6).

A comparison of condylar positions at CO before and after active treatment revealed that both condyles had shifted posteriorly and superiorly, while the entire mandible had adopted a symmetrical position. As a result, the condyles were positioned into the central area of the fossae (Figure 2B), where they remained stable during the years following the removal of the orthodontic appliances (Figures 2B and 2C). Throughout treatment, no continuation of resorption of the condyle head was noted on CT images, and there were no CO-CR discrepancies, indicating stability of mandibular position at five-year recall.

Discussion

It is important to approach active ICR before starting orthodontic treatment in order to obtain a stable treatment outcome.^{1,2} Although it appeared that the ICR was not progressive in the present case, splint

therapy was applied for six months before active treatment to minimise joint loading.

Previous studies have shown a lack of long-term stability of orthodontic treatment in ICR patients treated with conventional orthognathic surgery.^{2,3,6} Crawford et al. reviewed a group of seven patients with PCR who were treated by orthognathic surgery and found that five of the seven cases had further PCR and subsequent skeletal relapse after their second osteotomies.³ Arnett and Tamborello reported six patients with PCR who were treated by orthognathic surgery and found that five of the patients had further postoperative resorption.¹³ Arnett and Tamborello recommended the avoidance of mandibular surgery and the application of maxillary surgery alone in order to decrease the load on the TMJs.¹³ However, isolated maxillary surgery was not sufficient to correct patients with ICR who also had a retrognathic mandible. Huang et al. reported that condylectomy and costochondral grafting before orthognathic surgery appeared to produce stable and functional results.² Wolford and Cardenas also reported that the removal of hyperplastic synovial and bilaminar tissue and disk repositioning and repair followed by orthognathic surgery provided stable results.¹

Little is known about the long-term results of upper molar intrusion using TADs applied to induce a counterclockwise rotation of the mandible before orthognathic surgery in the treatment of patients with ICR. Reports have shown that molar intrusion using TADs is effective in the treatment of patients with temporomandibular disorders.⁷⁻⁹ It is suggested that the condyle is repositioned, and that a functional adaptation in the circumoral musculature is achieved as a result of the counterclockwise rotation of the mandible through molar intrusion.⁷⁻⁹ The present case procedure also likely facilitated the patient's mandible to autorotate and allowed the flattened condyle to adopt an improved position¹⁴ in the glenoid fossa following the corticotomy-assisted impaction of the maxillary molars (Figure 2).

The major risk factors for CROS include a posterior condylar displacement and mandibular advancement with a counterclockwise rotation during surgery.¹⁴⁻¹⁷ The magnitude of mandibular advancement is significantly correlated with a postoperative clockwise rotation of the mandible.^{5,18} A mandibular advancement of more than 10 mm coupled with a counterclockwise rotation and a posteriorly repositioned condyle are

associated with an increased risk of CROS.⁴ One reason for postoperative stability in the present case may be the relatively small forward movement (8 mm) of the mandible, due to preoperative mandible anti-clockwise repositioning supported by corticotomy/skeletal anchorage-assisted movements of maxillary molar intrusion. The aesthetic issue of the chin was effectively resolved by the advancement genioplasty.

No progress of resorption or remodelling of the condylar head was noted on CT assessment (Figure 2). No CO-CR discrepancy was observed after the five-year retention period. Condylar remodelling might result from an acquired functional occlusion producing balanced mechanical loading on the TMJ after correction of the mandibular retrognathism.²¹ The postoperative seating position of the condyle in the fossae and the consequent occlusion likely gave rise to an antero-superiorly directed loading vector at the TMJ that was biomechanically optimal.²² The positioning of the condyle^{14,16} before the BSSO is noted to prevent postoperative structural changes in the TMJ.²³ Previous reports revealed that stabilisation of the TMJs with splints was important for the patients with ICR before initiation of orthodontic treatment.^{1,6,9} It may be inferred that stability can be induced by condylar repositioning toward a centric position using an occlusal splint.²⁴ Carefully managed mandibular advancement did not subsequently influence the TMJ with its pre-existing displaced disk, crepitus, clicking, and arthralgia.^{25,26}

Conclusions

A 19-year-old female who presented with a skeletal Class II open-bite malocclusion with ICR was treated by the surgical-assisted intrusion of maxillary molars using TADs followed by mandibular advancement and genioplasty. The post-treatment records after five years of retention showed an acceptable facial appearance, occlusion and mandibular/condylar position with no progress of the condylar resorption. Based only on this single case, these findings indicate that the presented treatment is an effective alternative to bimaxillary osteotomy for patients affected by ICR.

References

1. Wolford LM, Cardenas L. Idiopathic condylar resorption: diagnosis, treatment protocol, and outcomes. *Am J Orthod Dentofacial Orthop* 1999;116:667-77.

2. Huang YL, Pogrel MA, Kaban LB. Diagnosis and management of condylar resorption. *J Oral Maxillofac Surg* 1997;55:114-9; discussion 119-20.
3. Crawford JG, Stoelinga PJ, Blijdorp PA, Brouns JJ. Stability after reoperation for progressive condylar resorption after orthognathic surgery: report of seven cases. *J Oral Maxillofac Surg* 1994;52:460-6.
4. Catherine Z, Breton P, Bouletreau P. Condylar resorption after orthognathic surgery: A systematic review. *Rev Stomatol Chir Maxillofac Chir Orale* 2016;117:3-10.
5. Kobayashi T, Izumi N, Kojima T, Sakagami N, Saito I, Saito C. Progressive condylar resorption after mandibular advancement. *Br J Oral Maxillofac Surg* 2012;50:176-80.
6. Arnett GW, Milam SB, Gottesman L. Progressive mandibular retrusion-idiopathic condylar resorption. Part II. *Am J Orthod Dentofacial Orthop* 1996;110:117-27.
7. Tanaka E, Yamano E, Inubushi T, Kuroda S. Management of acquired open bite associated with temporomandibular joint osteoarthritis using miniscrew anchorage. *Korean J Orthod* 2012;42:144-54.
8. Kaku M, Koseki H, Kawazoe A, Abedini S, Kojima S, Motokawa M et al. Treatment of a case of skeletal class II malocclusion with temporomandibular joint disorder using miniscrew anchorage. *Cranio* 2011;29:155-63.
9. Song F, He S, Chen S. Temporomandibular disorders with skeletal open bite treated with stabilization splint and zygomatic miniplate anchorage: a case report. *Angle Orthod* 2015;85:335-47.
10. Kanno T, Mitsugi M, Furuki Y, Kozato S, Ayasaka N, Mori H. Corticotomy and compression osteogenesis in the posterior maxilla for treating severe anterior open bite. *Int J Oral Maxillofac Surg* 2007;36:354-7.
11. Akay MC, Aras A, Günbay T, Akyalçin S, Koyuncue BO. Enhanced effect of combined treatment with corticotomy and skeletal anchorage in open bite correction. *J Oral Maxillofac Surg* 2009;67:563-9.
12. Tuncer C, Ataç MS, Tuncer BB, Kaan E. Osteotomy assisted maxillary posterior impaction with miniplate anchorage. *Angle Orthod* 2008;78:737-44.
13. Arnett GW, Tamborello JA. Progressive Class II development: female idiopathic condylar resorption. *Oral Maxillofac Surg Clin North Am* 1990;2:699-716.
14. Ikeda K, Kawamura A. Assessment of optimal condylar position with limited cone-beam computed tomography. *Am J Orthod Dentofacial Orthop* 2009;135:495-501.
15. Gill DS, El Maaytah M, Naini FB. Risk factors for post-orthognathic condylar resorption: a review. *World J Orthod* 2008;9:21-5.
16. Ikeda K, Kawamura A, Ikeda R. Assessment of optimal condylar position in the coronal and axial planes with limited cone-beam computed tomography. *J Prosthodont* 2011;20:432-8.
17. Hwang SJ, Haers PE, Zimmermann A, Oechslin C, Seifert B, Sailer HF. Surgical risk factors for condylar resorption after orthognathic surgery. *Oral Surg Oral Med Oral Pathol Oral Radiol Endod* 2000;89:542-52.
18. Yang HJ, Hwang SJ. Bone mineral density and mandibular advancement as contributing factors for postoperative relapse after orthognathic surgery in patients with preoperative idiopathic condylar resorption: a prospective study with preliminary 1-year follow-up. *Oral Surg Oral Med Oral Pathol Oral Radiol* 2015;120:112-8.
19. Ellis E 3rd. Bimaxillary surgery using an intermediate splint to position the maxilla. *J Oral Maxillofac Surg* 1999;57:53-6.
20. Gil JN, Claus JD, Manfro R, Lima SM. Predictability of maxillary repositioning during bimaxillary surgery: accuracy of a new technique. *Int J Oral Maxillofac Surg* 2007;36:296-300.
21. You MS, Yang HJ, Hwang SJ. Postoperative functional remodeling of preoperative idiopathic condylar resorption: a case report. *J Oral Maxillofac Surg* 2011;69:1056-63.
22. Koriath TW, Hannam AG. Deformation of the human mandible

- during simulated tooth clenching. *J Dent Res* 1994;73:56-66.
23. Saka B, Petsch I, Hingst V, Härtel J. The influence of pre- and intraoperative positioning of the condyle in the centre of the articular fossa on the position of the disc in orthognathic surgery. A magnetic resonance study. *Br J Oral Maxillofac Surg* 2004;42:120-6.
 24. Freihofer HB, Petrešević D. Late results after advancing the mandible by sagittal splitting of the rami. *J Maxillofac Surg* 1975;3:250-7.
 25. Valladares-Neto J, Cevidanes LH, Rocha WC, Almeida GeA, Paiva JB, Rino-Neto J. TMJ response to mandibular advancement surgery: an overview of risk factors. *J Appl Oral Sci* 2014;22:2-14.
 26. Gonçalves JR, Cassano DS, Wolford LM, Santos-Pinto A, Márquez IM. Postsurgical stability of counterclockwise maxillomandibular advancement surgery: affect of articular disc repositioning. *J Oral Maxillofac Surg* 2008;66:724-38.