

# Management of multiple adjacent asymmetric intruded teeth by differential curve of Spee mechanics: a case report

Heng-Ming Mark Chang,\* Chao-Wen Ting,† Kai-Lung Wang,\* Kwok-Hing Ho,† Shun-Chu Hsieh\* and Hsueh-Jen Lin†

Orthodontic and Dental Department, Chang Bing Show Chwan Memorial Hospital\* and Orthodontic and Dental Department, Show Chwan Memorial Hospital,† Changhua, Taiwan

*Introduction:* Of the types of dental trauma, intrusive luxation is considered to have the worst prognosis. When forceful intrusion affects multiple adjacent teeth, orthodontic repositioning may be required; however, orthodontic treatment can be complicated by the development of a cant in the occlusal plane, especially when the affected teeth are not symmetrically located from the midline and corrective forces and anchorage are unbalanced. Designing an appropriate mechanism to overcome this problem is essential.

*Case presentation:* The present case report describes a 28-year-old male who suffered the traumatic intrusion of multiple teeth, with accompanying alveolar bone fractures, following a road traffic accident. The intruded teeth were repositioned using orthodontic traction, following which, endodontic treatment was performed. After initial alignment, differential curve of Spee mechanics were applied to correct the occlusal plane and an acceptable result was achieved. The overall outcome was maintained at a 24-months review.

*Conclusion:* This report demonstrates the importance of the early repositioning of intruded teeth to avoid dento-alveolar ankylosis, as well as the use of differential curve of Spee mechanics which provides effective force application in the management of a canted occlusal plane.

(Aust Orthod J 2018; 34: 78-84)

Received for publication: June 2017

Accepted: September 2017

Heng-Ming Mark Chang: [markortho@gmail.com](mailto:markortho@gmail.com); Chao-Wen Ting: [jwd@mail2000.com.tw](mailto:jwd@mail2000.com.tw); Kai-Lung Wang: [chordater@hotmail.com](mailto:chordater@hotmail.com); Kwok-Hing Ho: [yatpong@gmail.com](mailto:yatpong@gmail.com); Shun-Chu Hsieh: [markortho@yahoo.com.tw](mailto:markortho@yahoo.com.tw); Hsueh-Jen Lin: [hseuhjen@ms12.hinet.net](mailto:hseuhjen@ms12.hinet.net)

## Introduction

Dental trauma is a complicated issue faced in dental practice because many treatment disciplines are often involved. Of the different types of trauma, intrusive luxation is arguably considered the most severe and associated with late sequelae.<sup>1</sup> Fortunately, intrusive luxation is uncommon, occurring in 0.3% to 3% of all dental injuries.<sup>2-4</sup> The intruded teeth sometimes herald other types of dental injuries or complications, such as pulp obliteration, pulp necrosis, rapid inflammatory root resorption (IRR), ankylosis, or marginal alveolar bone loss. A multi-disciplinary approach to treating the traumatised dental patient is imperative.

Alveolar process fracture is found in less than 3% of dental injuries presenting at a hospital clinic.<sup>5</sup> In the past, clinicians have advocated the extraction of teeth in the fracture line in order to prevent infection;<sup>6</sup> however, studies have noted that the risk of infection is low.<sup>7,8</sup> Only one case of infection was reported by Krenkel and Grunert,<sup>7</sup> and none were reported by Andreasen.<sup>8</sup>

Several management approaches may be considered for patients with traumatised intruded teeth and alveolar bone fractures, including no treatment (spontaneous re-eruption), orthodontic extrusion, surgical repositioning, or a combination of the above. According to

the guidelines published by the International Association of Dental Traumatology (IADT),<sup>9</sup> the management of intrusive luxation should be considered on an individual basis, including the severity of intrusion, stage of root formation and complications during the review stage. Nevertheless, active treatment should be carried out within four weeks, otherwise ankylosis of the affected teeth may develop.<sup>9</sup>

When attempting orthodontic repositioning of multiple intruded teeth that are not symmetrical relative to the midline, the occlusal plane will inevitably cant toward the affected side. The correction of a canted occlusal plane may be a challenging task for the orthodontist. Some approaches have involved the use of intermaxillary elastics to enhance dental extrusion, but this may produce simultaneous extrusion of the opposing teeth and cause further occlusal plane disharmony.<sup>10</sup> The design of an intra-arch mechanism to correct a canted occlusal plane may be relative to the specific needs of a case. Several intra-arch methods, including skeletal anchorage, have been reported;<sup>11-15</sup> however, none have been applied to traumatised intruded teeth. The present case report details the use of a reverse and asymmetrical intra-arch force couple called 'differential curve of Spee mechanics' to correct an occlusal plane cant after dental repositioning.

### ***Diagnosis and aetiology***

A 28-year-old male suffered an injury to the right side of his face during a road traffic accident. After primary care of the wound in an emergency setting, the patient was admitted to hospital for further observation. There was no relevant medical history and an examination revealed no evidence of brain damage or other cranio-facial bone fracture. The patient was referred to the orthodontic department one week later for consultation.

An extra-oral examination revealed bruising over the right lateral canthus area, and subconjunctival haemorrhage (Figure 1a, b). The skeletal pattern was class I with an average Frankfort-mandibular plane angle and balanced lower facial height proportion (Figure 1c). An intraoral assessment showed multiple severely intruded teeth in the lower right quadrant (Figure 1d-h). Three of the lower incisors, the lower right canine and first premolar were intruded and, of these, the first premolar and canine were the most severely affected teeth by more than 10 mm

of displacement (Figure 1i). The lower incisors were intruded and proclined with an alveolar process fracture. The fracture line was apparent on the cephalogram (Figure 1c) and adjacent to the apical third of the lower right canine and first premolar on the periapical films (Figure 1j).

### ***Treatment objectives***

At the initial orthodontic consultation, no auto-eruption of the intruded teeth was observed. In order to reposition the intruded teeth, orthodontic repositioning was considered. The severely affected canine and first premolar were almost submerged below the gingiva, making endodontic treatment problematic. Therefore, the treatment objectives for this patient were: (1) to reposition the intruded teeth for better occlusion, (2) to provide clear access for endodontic treatment, and (3) to improve facial profile and symmetry.

### ***Treatment alternatives***

Since no spontaneous eruption had been noted, an active approach to repositioning the intruded teeth was discussed. Surgical repositioning was an option, but after maxillofacial surgical consultation, it was considered that surgical repositioning would be difficult and splinting would not be stable when multiple teeth were involved. It was concluded that a greater chance of success would be provided by orthodontic repositioning in this case and therefore the orthodontic option was chosen.

During treatment, applying inter-arch elastics for dental extrusion was considered. However, this would largely rely on patient compliance and would potentially cause an occlusal cant in the upper arch.<sup>10,16,17</sup> Therefore, a reverse and asymmetrical intra-arch force couple delivered by a differential curve of Spee mechanic was developed for the occlusal plane correction.

### ***Treatment progress***

The lower arch was bonded first using a 0.022" slot preadjusted edgewise brackets and a 0.014" heat-activated NiTi was used for initial alignment. The most displaced canine and premolar were loosely tied to the main wire using stainless steel ligatures. The intruded teeth were significantly and sufficiently

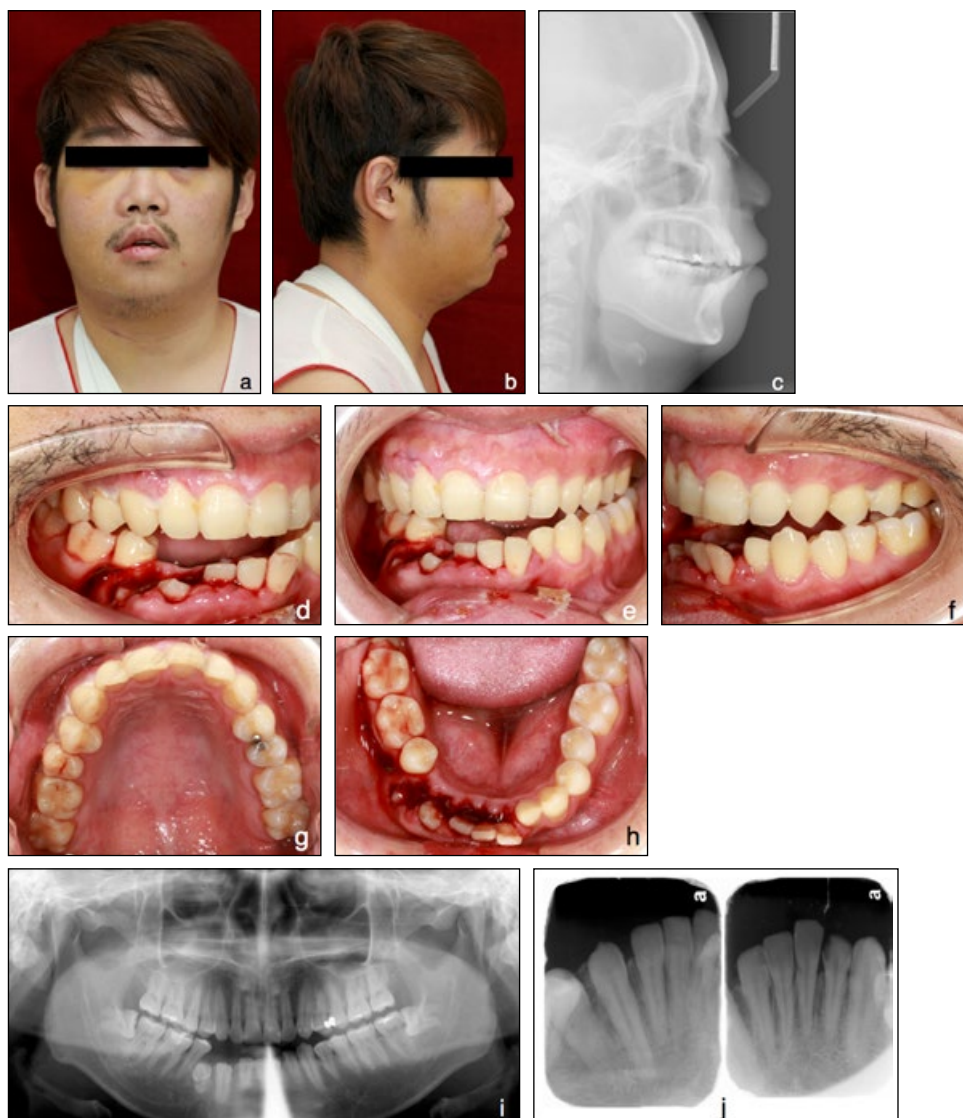


Figure 1. Extra-oral photos showed bruising over the right lateral canthus area and subconjunctival haemorrhage (a,b). Skeletal pattern was Class I with an average FMA and face height from the cephalometric radiograph (c). Intraoral photos showed extensive dental intrusion with alveolar bone fracture from LL 2 to LR 4 and open bite (d-h). Initial panorex demonstrated severe dental intrusions on multiple sites (i). Lower right canine and premolar were intruded for more than 10 mm and lower incisors were intruded and proclined after trauma (j).

extruded in three months and so the patient was referred for endodontic treatment. Pulp sensitivity was assessed with an electric pulp test (EPT) and negative findings were revealed on the lower left (LL) 1 and 2, and lower right (LR) 3 and 4 but, curiously, the proclined LR 1 and 2 still reacted positively (reading 2,3 respectively). Endodontic treatment was thus carried out on the affected teeth apart from the LR 1 and 2.

After endodontic therapy, orthodontic treatment continued and the upper arch was bonded. Because of a tendency for occlusal plane canting during the levelling stage, differential curve of Spee mechanics were incorporated into the 0.019" × 0.025" S.S. wire

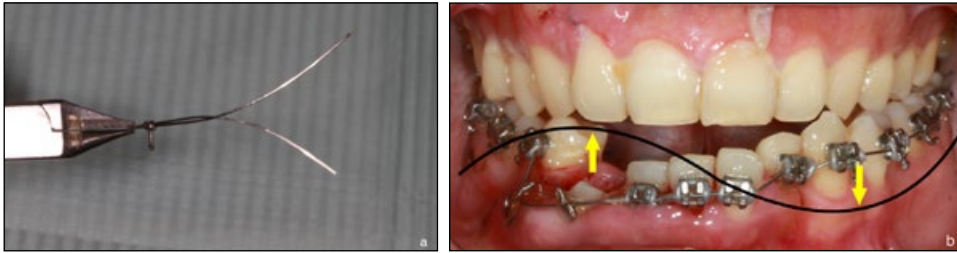
for occlusal plane correction. The differential curve of Spee was comprised of a reverse curve of Spee on the affected side and increased curve of Spee on the contralateral side (Figure 2a). Force magnitude was maintained at approximately 400 g (200 g on either side) and this provided an effective force couple for the tooth extrusion and occlusal plane correction (Figure 2b). During the finishing stage, the patient was instructed to wear inter-arch elastics for occlusal settling. After 28 months, including four months of endodontic treatment, the patient was debonded and clear vacuum-formed retainers were fitted for retention.

### Treatment results

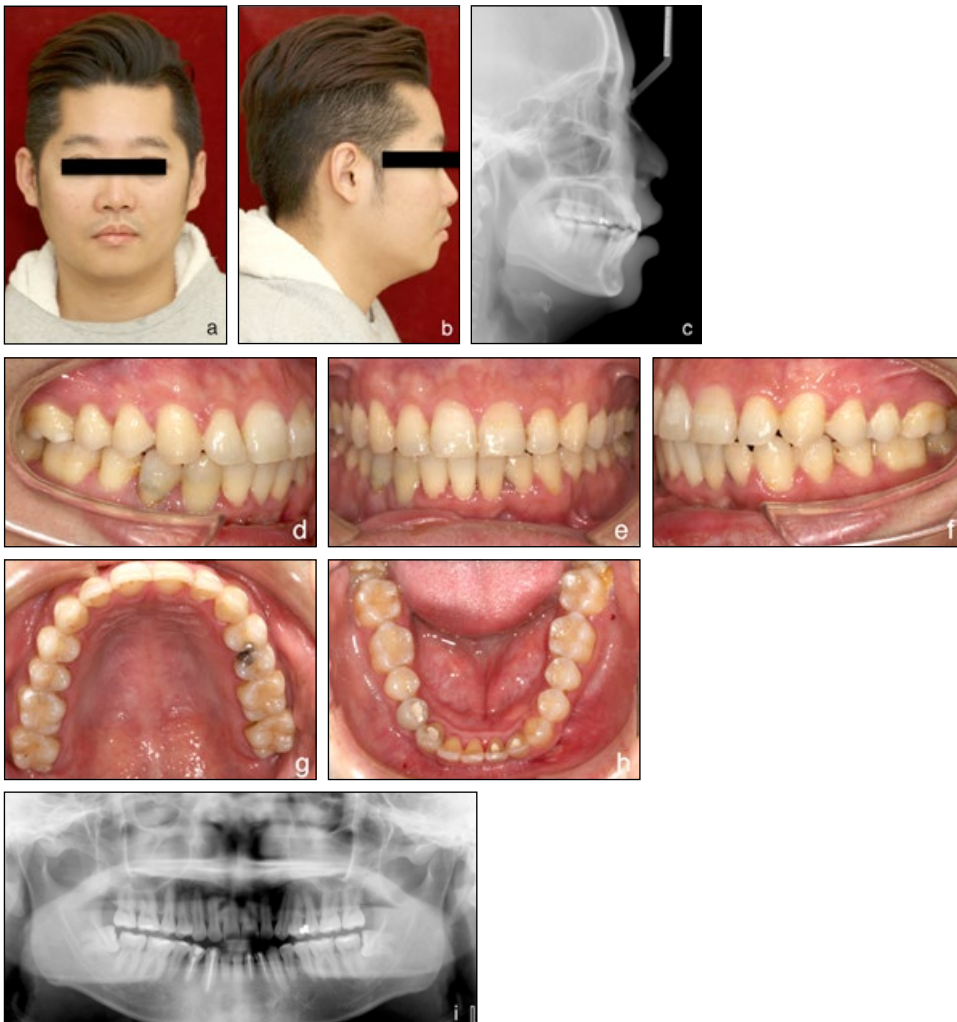
At the end of treatment, a pleasant facial profile with good vertical proportions was achieved (Figure 3a-c). Intraorally, solid occlusal interdigitation was established in both buccal segments and no occlusal plane cant was evident (Figure 3d-h). Good root

parallelism was noted from the final panoramic radiograph (Figure 3i). The lower third molars were impacted and extraction of these teeth was advised.

After 24 months of follow-up, the treatment results had been maintained (Figure 4a-h). Radiographs showed no evidence of periapical pathology associated

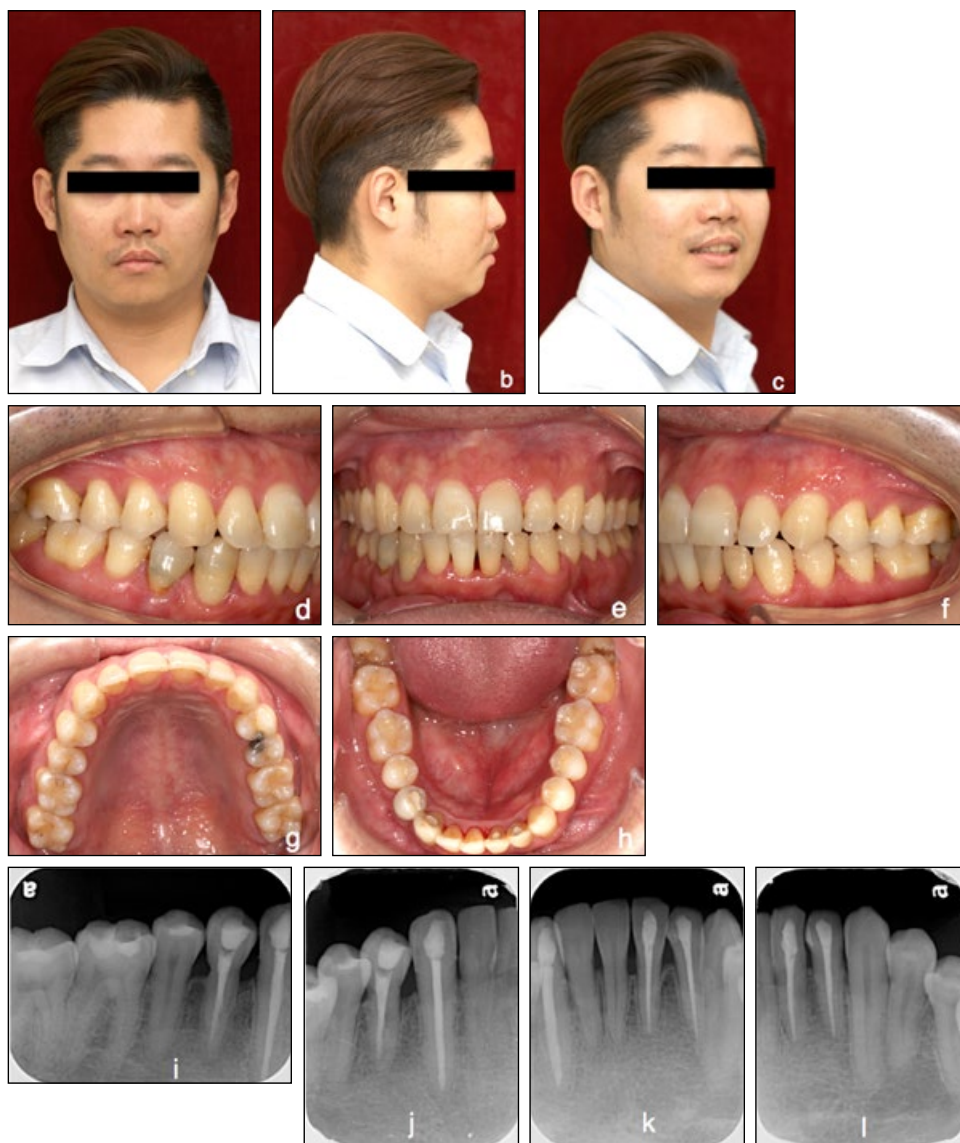

**Figure 2.** The 'differential curve of Spee' wire bending comprises reverse curve of Spee on one side and increased curve of Spee on the other (a). The reverse and asymmetrical force couple may provide an effective mechanism for the teeth lifting and occlusal plane correction (b).



**Figure 3.** Records at the debonding appointment. Extra-oral photos and cephalometric radiograph showed good facial profile and vertical proportions (a-c). Intraoral photos presented solid occlusal interdigitations in both buccal segments and no occlusal plane cant (d-h). Panoramic radiograph showed good root parallelism (i). The lower third molars showed mesio-angular impaction.





**Figure 4.** Records of 24-month follow-up. Extra-oral and intraoral photos showed treatment results were still maintained (a-h). Mild gingival inflammation was noted at this appointment and oral hygiene was re-instructed. Endodontic results were still stable from the radiographs (i-l). The absence of PDL space was noted on the LR4, and ankylosis was suspected. Cervical root resorption was also noted on the mesial and distal sites of this tooth (i).

with the endodontically-treated teeth (Figure 4i-l). However, the absence of the lamina dura and the PDL space was noted on the LR4, and dento-alveolar ankylosis was suspected. Cervical root resorption was also found on the mesial and distal surfaces of this tooth (Figure 4i).

The EPT results remained positive (reading 5, 6 respectively) for the LR 1 and 2 during the review period and no signs or symptoms of periapical pathology were reported. The lamina dura of the teeth were intact and no PDL widening was radiographically found (Figure 4k). Although the EPT readings

were higher than the initial status, it was decided to regularly review these teeth.

### Discussion

When facing severe trauma involving dental displacement and alveolar bone fractures, clinicians are often concerned about complications such as pulp canal obliteration, pulp necrosis, root resorption, dento-alveolar ankylosis, and marginal bone loss. Of these and according to a 10-year review study,<sup>18</sup> pulp necrosis is the most frequent complication and the risk is much higher in mature rather than

immature root form. Additional factors, related to age (>30 years), fracture line level (passing through the root apex), fracture displacement (over 2 mm in the horizontal part) and incomplete repositioning of the bone and teeth, also increase the risk of pulp necrosis. In the presented case, pulp vitality of the displaced teeth was checked once the teeth had been extruded sufficiently to facilitate endodontic treatment. The endodontic results of the intruded teeth remained stable throughout orthodontic treatment and the follow-up stage.

Ankylosis is a common complication following traumatic luxation due to local destruction of the periodontal ligament or cementum. The repair process of the damaged tissue involves replacement resorption from the adjacent bone.<sup>19-22</sup> Although reported surgical luxation prior to orthodontic treatment would aid the ankylosed maxillary incisor in movement, the outcome is still uncertain.<sup>23</sup> In an animal study, intruded teeth that were moved immediately following trauma showed reduced replacement resorption compared to those extruded seven days later.<sup>24</sup> Therefore, early repositioning of intruded teeth prior to endodontic treatment is indicated and supported by the International Association of Dental Traumatology.<sup>9</sup>

In the present case, surgical reposition was not feasible due to the number of teeth involved and the difficulties of dental splinting. It was therefore decided to reposition the intruded teeth by orthodontic means. The teeth were extruded and levelled significantly within three months to allow endodontic therapy to take place. The rapid movement may possibly be ascribed to a regional acceleratory phenomenon (RAP), which is a local response of tissues to noxious events that subsequently stimulates tissue to regenerate faster than normal in a regional regeneration/remodelling process.<sup>25</sup> After the initial levelling and alignment of the injured teeth, good root canal access was obtained for endodontic treatment. This avoided an unnecessary gingivectomy for the purpose of creating access.<sup>26</sup>

The correction of an occlusal plane cant is always a challenging procedure for orthodontists. Most of the suggested orthodontic methods incorporate skeletal anchorage to intrude/extrude teeth for occlusal plane management.<sup>12-15</sup> However, placing skeletal anchorage may not be feasible for traumatised patients with dental displacement. Burstone advocated the use of a lingual arch combined with tip-back activation on the canted side and tip-forward activation on the

contralateral side to correct a mandibular occlusal plane cant.<sup>11</sup> This concept inspired the design of a reverse and asymmetrical force system, labelled 'differential curve of Spee mechanics', to correct the occlusal plane cant in the present intrusive luxation case. The differential curve of Spee was incorporated into a 0.019" × 0.025" stainless steel (S.S.) archwire with a generated force magnitude of approximately 400 g (200 g per side). The properties of S.S. wire provide a rigid and robust force couple to overcome occlusal forces and make correction effective. In addition, according to Proffit, the optimum force level for single tooth extrusion is from 35 to 60 g<sup>27</sup> and so it was considered that the 200 g force level generated on the affected side of the differential curve of Spee would effectively erupt the intruded teeth (LR 1 to 4). The S.S. archwire curvature of Spee magnitude was increased incrementally and once the occlusal cant was corrected a flat and plain 0.019" × 0.025" S.S. archwire was inserted to maintain the arch form and occlusal plane level. If the differential curve of Spee wire had not been replaced, there might have been an unwanted side effect of exaggerated overcorrection. It is recommended that regular and close review and adjustment is applied when using this type of mechanics.

Interestingly, the EPT results of the LR 1 and 2 remained positive at the follow-up stage, and this may be attributed to the type of dental luxation. From the initial cephalometric radiograph (Figure 1c), the two incisors were more labially proclined rather than intruded and so the apices were not displaced significantly. In addition, the bone fracture line did not pass through the apices of these teeth, which might explain why the blood supplies were not occluded or totally disrupted. The healing process of fractured alveolar bone is similar to a Le Fort I osteotomy, which has shown pulp necrosis in fewer than 1% of cases one and two years after surgery.<sup>28,29</sup> However, regular review of the vitality remains necessary.

## Conclusion

The present case report demonstrates the successful treatment of an adult patient with multiple intruded teeth and alveolar bone fractures as a result of trauma. Early repositioning of the intruded teeth may reduce the risk of an open bite caused by dento-alveolar ankylosis during healing. Of all treatment methods, orthodontic repositioning is more beneficial when

multiple teeth are intruded or when splinting is not stable. During orthodontic therapy, the use of a differential curve of Spee archwire can provide an effective force couple to aid in occlusal plane correction. Long-term follow-up of the traumatised teeth, as well as the treatment outcomes, is advised.

## Acknowledgments

I would like to express my sincere gratitude to Professor Philip E. Benson, the head of the Academic Unit of Oral Health and Development, School of Dentistry, University of Sheffield, for his expert advice and encouragement throughout this case report. I also appreciate Dr. Ming-Tsung Lee's kind assistance in the submission process.

## Corresponding author

Hsueh-Jen Lin  
Dental Department  
Show Chwan Memorial Hospital  
Changhua  
Taiwan, R.O.C.  
Email: hseuhjen@ms12.hinet.net

Mailing address: No. 2, Guang-Fu Road, Changhua, Taiwan, R.O.C.

## References

1. Tsilingaridis G, Malmgren B, Andreasen JO, Malmgren O. Intrusive luxation of 60 permanent incisors: a retrospective study of treatment and outcome. *Dent Traumatol* 2012; 28:416-22.
2. Neto JJ, Gondim JO, de Carvalho FM, Giro EM. Longitudinal clinical and radiographic evaluation of severely intruded permanent incisors in a pediatric population. *Dent Traumatol* 2009;25:510-4.
3. Skaare AB, Jacobsen I. Dental injuries in Norwegians aged 7-18 years. *Dent Traumatol* 2003;19:67-71.
4. Oulis C, Vadiakas G, Siskos G. Management of intrusive luxation injuries. *Endod Dent Traumatol* 1996;12:113-9.
5. Borum MK, Andreasen JO. Therapeutic and economic implications of traumatic dental injuries in Denmark: an estimate based on 7549 patients treated at a major trauma centre. *Int J Paediatr Dent* 2001;11:249-58.
6. Freihofer HP Jr. [Results of treatment of fractures of the alveolar process]. *SSO Schweiz Monatsschr Zahnheilkd* 1969;79:623-9. German.
7. Krenkel C, Grunert I. [Teeth in and around fracture lines treated with bonded silca wire splints]. *Dtsch Z Mund Kiefer Gesichtschir* 1987;11:208-10. German.
8. Andreasen JO. Fractures of the alveolar process of the jaw. A clinical and radiographic follow-up study. *Scand J Dent Res* 1970;78:263-72.
9. Diangelis AJ, Andreasen JO, Ebeleseder KA, Kenny DJ, Trope M, Sigurdsson A et al. International Association of Dental Traumatology guidelines for the management of traumatic dental injuries: 1. Fractures and luxations of permanent teeth. *Dent Traumatol* 2012;28:2-12.
10. Sxenısık NE, Hasıpek S. Occlusal cant: etiology, evaluation, and management. *Turkish J Orthod* 2015;27:174-80.
11. Burstone CJ. Precision lingual arches, active applications. *J Clin Orthod* 1989;23:101-9.
12. Kang YG, Nam JH, Park YG. Use of rhythmic wire system with miniscrews to correct occlusal-plane canting. *Am J Orthod Dentofacial Orthop* 2010;137:540-7.
13. Jeon YJ, Kim YH, Son WS, Hans MG. Correction of a canted occlusal plane with miniscrews in a patient with facial asymmetry. *Am J Orthod Dentofacial Orthop* 2006;130:244-52.
14. Ko DI, Lim SH, Kim KW. Treatment of occlusal plane canting using miniscrew anchorage. *World J Orthod* 2006;7:269-78.
15. Yáñez-Vico RM, Iglesias-Linares A, Cadenas de Llano-Pérula M, Solano-Reina A, Solano-Reina E. Management of occlusal canting with miniscrews. *Angle Orthod* 2014;84:737-47.
16. Mostafa YA, Tawfik KM, El-Mangoury NH. Surgical-orthodontic treatment for overerupted maxillary molars. *J Clin Orthod* 1985;19:350-1.
17. Yao CC, Wu CB, Wu HY, Kok SH, Chang HF, Chen YJ. Intrusion of the overerupted upper left first and second molars by mini-implants with partial-fixed orthodontic appliances: a case report. *Angle Orthod* 2004;74:550-7.
18. Lauridsen E, Gerds T, Andreasen JO. Alveolar process fractures in the permanent dentition. Part 2. The risk of healing complications in teeth involved in an alveolar process fracture. *Dent Traumatol* 2016;32:128-39.
19. Andreasen JO. A time-related study of periodontal healing and root resorption activity after replantation of mature permanent incisors in monkeys. *Swed Dent J* 1980;4:101-10.
20. Andreasen JO. Analysis of pathogenesis and topography of replacement root resorption (ankylosis) after replantation of mature permanent incisors in monkeys. *Swed Dent J* 1980;4:231-40.
21. Breivik M, Kvam E. Histometric study of root resorption on human premolars following experimental replantation. *Scand J Dent Res* 1987;95:273-80.
22. Lorient LB, Machado AW, Souki BQ, Pereira TJ. Late diagnosis of dentoalveolar ankylosis: impact on effectiveness and efficiency of orthodontic treatment. *Am J Orthod Dentofacial Orthop* 2009;135:799-808.
23. Lin F, Sun H, Yao L, Chen Q, Ni Z. Orthodontic treatment of severe anterior open bite and alveolar bone defect complicated by an ankylosed maxillary central incisor: a case report. *Head Face Med* 2014;10:47.
24. Gomes JC, Gomes CC, Bolognese AM. Clinical and histological alterations in the surrounding periodontium of dog's teeth submitted for an intrusive luxation. *Dent Traumatol* 2008;24:332-6.
25. Frost HM. The regional acceleratory phenomenon: a review. *Henry Ford Hosp Med J* 1983;31:3-9.
26. Wigen TI, Agnalt R, Jacobsen I. Intrusive luxation of permanent incisors in Norwegians aged 6-17 years: a retrospective study of treatment and outcome. *Dent Traumatol* 2008;24:612-8.
27. Proffit WR, Fields HW, Sarver DM. *Contemporary Orthodontics*, 5th Edition. Amsterdam: Elsevier, 2012;287.
28. Pepersack WJ. Tooth vitality after alveolar segmental osteotomy. *J Maxillofac Surg* 1973;1:85-91.
29. Vedtofte P, Nattestad A. Pulp sensibility and pulp necrosis after Le Fort I osteotomy. *J Craniomaxillofac Surg* 1989;17:167-71.