

Evaluation of the posterior airway space following orthopaedic treatment of mandibular deficient Class II malocclusion – a pilot study

Christopher J. Costello,* John Sambevski,* Lam L. Cheng* and M. Ali Darendeliler†

Faculty of Dentistry* and Discipline of Orthodontics, Faculty of Dentistry,† University of Sydney, Sydney, Australia

Background: The use of Twin Block therapy is a well-accepted functional treatment option for the correction of a Class II malocclusion. In addition to skeletal and dental changes, its use may also promote changes in airway structure and dimension, including the size of the posterior airway space (PAS). This may be of importance in reducing the risk of developing obstructive sleep apnoea syndrome (OSAS).

Materials and methods: Sixteen (16) subjects (eight females and eight males) underwent treatment of a Class II division 1 malocclusion via the use of a Sydney Bonded Twin Block (SBTB) appliance followed by full fixed orthodontic therapy (FFOA). Pretreatment (T1), post-twin block (T2) and post-fixed appliance (T3) lateral cephalograms were taken and skeletal and soft tissue landmarks were hand traced. A pairwise comparison was used to assess whether there were any significant differences in the cephalometric variables between each phase of treatment (T1, T2, T3).

Results: The skeletal variables SNB and ANB revealed a significant change between T1-T2 ($p < 0.01$). The sagittal size of the nasopharynx (RPAS) also recorded a significant change between T1-T3 ($p < 0.05$). There was no significant change in the PAS at any stage of treatment. There was an average reduction in the ANB angle of 2° ($p < 0.01$) between T1-T3.

Conclusions: There was no significant change in the size of the PAS following SBTB treatment. However, an increase in RPAS was recorded following SBTB treatment which continued to improve during FFOA therapy. (Aust Orthod J 2018; 34: 11-16)

Received for publication: August 2015

Accepted: August 2017

Christopher J. Costello: cozza123@hotmail.com; John Sambevski: jsambevski@gmail.com; Lam L. Cheng: lam.cheng@sydney.edu.au; M. Ali Darendeliler: ali.darendeliler@sydney.edu.au

Introduction

A Class II malocclusion, especially as a result of a mandibular deficiency, has been implicated in contributing to the severity of Obstructive Sleep Apnoea Syndrome (OSAS).¹ It has been hypothesised that this is a result of a concomitant reduction in the posterior airway space (PAS) in Class II patients.¹

Treatments available for OSAS involve either surgical or non-surgical alterations in the relationship of the maxillo-mandibular complex. A mandibular advancement splint (MAS) is a common initial line of treatment used to achieve forward repositioning of the mandible. Studies have shown that the use of MAS

has the potential to significantly enlarge the PAS^{2,3} and improve the apnoea-hypopnea index.⁴ Similarly, anterior repositioning of the mandible using various surgical techniques has been claimed to increase the PAS while demonstrating a 50% effectiveness rate in eliminating the symptoms of OSAS.⁵

The correction of a Class II malocclusion through functional appliance therapy occurs as a result of changes to the jaw musculature and soft tissues to maintain the appliance-generated anterior repositioning of the mandible. This has been reported to result in a reduction of the anteroposterior apical base discrepancy, an increase in effective mandibular

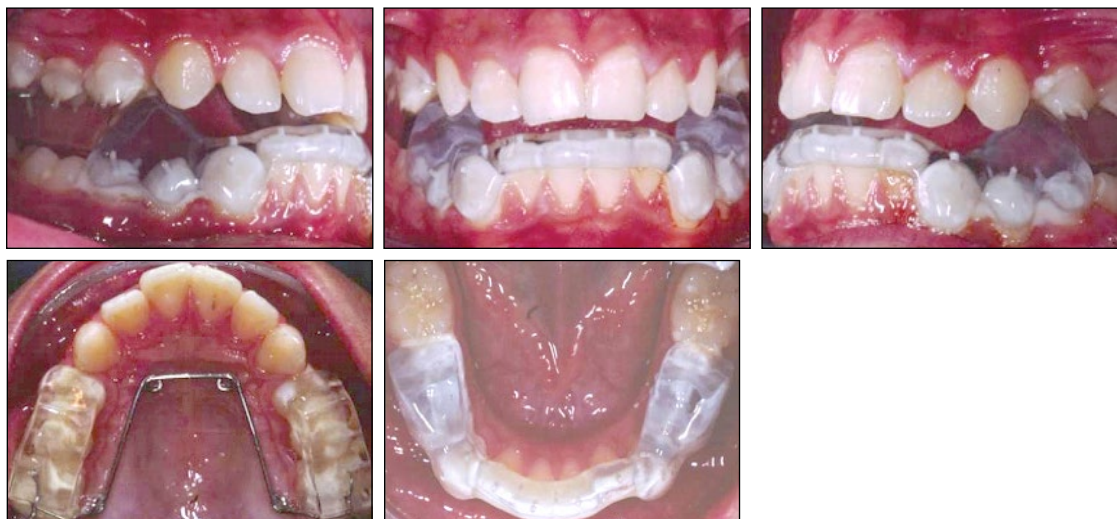

Figure 1. SBTB clinical photographs.

length, an increase in length of the facial axis, an increase in facial height and a reduction in facial convexity.⁶ As functional appliance therapy promotes anterior mandibular repositioning during adolescent growth, it appears reasonable to suggest that there may be an associated increase in the size of the PAS as a result.

The Twin Block is a commonly-used Class II functional appliance. It can either be removable or fixed, and its versatility allows the incorporation of active components such as expansion screws. It is a two-piece appliance, comprising acrylic blocks made for the upper and lower arches. The design incorporates a guide plane that only allows the patient to close in a protrusive fashion, and it has the benefit of allowing the patient to function with the appliance in place.⁷

The aim of the present study was to evaluate the effects of the Sydney Bonded Twin Block (SBTB) on the PAS following orthopaedic treatment of Class II division 1 malocclusions. The size of the PAS was also assessed at the completion of fixed appliance (FFOA) therapy to investigate the stability of the changes.

Materials and methods

Subjects

The sample consisted of 16 (eight females and eight males) Class II division 1 malocclusion patients with mandibular deficiency who received functional appliance therapy at the Discipline of Orthodontics, University of Sydney. All subjects were treated with SBTB as a first phase of treatment (nine months) and

FFOA therapy in the second phase. Pretreatment (T1), end of SBTB therapy (T2) and end of FFOA therapy (T3) records, which consisted of lateral cephalograms, were obtained within 21 days prior to appliance placement and on the day of appliance removal. The mean ages of the patients at pretreatment, end of SBTB therapy and end of FFOA therapy were 12.24 ± 1.05 years, 12.98 ± 1.08 years and 15.30 ± 1.45 years, respectively.

Appliance design

The SBTB is a modification of the original Clark Twin block^{8,9} and cemented onto the maxillary and mandibular dentition with glass ionomer cement (Unitek™ Multi-Cure Glass Ionomer Band Cement, 3M Unitek™, CA, USA) (Figure 1). The construction bite was taken with the mandible postured to an edge-to-edge and/or a super Class I molar relationship. The maxillary bite block was not trimmed and no compensatory transverse expansion or incisor alignment was performed during the SBTB phase. Immediately after SBTB therapy, FFOA were placed. A self-ligating SPEED® (Strite Industries, Cambridge, Ontario, Canada) 0.022 inch slot bracket system was applied during the fixed appliance therapy to standardise the method of ligation.

Cephalometric analysis

Skeletal and soft tissue changes were assessed on lateral cephalograms. All radiographs were taken with the subjects in natural head position using the

same Cephalostat (Cranex Tome, Soredex, Orion Corporation Helsinki, Finland) with the left side of the patient's face orientated towards the tube. The exposure factors, kVp, mA, exposure and time were kept constant for the T1, T2 and T3 films.

Radiographs were hand traced on 0.03 matte acetate paper with a 0.5 mm HB pencil over a one-week period by the same operator (JS). The T1, T2 and T3 radiographs were traced simultaneously. Measurements were recorded to the nearest 0.5 mm.

Measurement landmarks

Standard cephalometrics

Changes in the sagittal skeletal relationships were assessed using the standard cephalometric variables of SNA, SNB and ANB.

Cephalometric soft tissue measurements

Changes in airway dimension were assessed using soft tissue cephalometric variables that included H-MP, PAS, RPAS and NPAS (Figure 2).

Statistical analysis

The means and standard deviations were calculated for all cephalometric variables at T1, T2 and T3. A statistical analysis was undertaken using SPSS (IBM SPSS Statistics for Windows, Version 23.0, IBM Corp, NY, USA). *P*-values less than 0.01 were deemed to be significant (**) and those between 0.01 and 0.05 marginally significant (*) as this was due to the large number of tests undertaken. The statistical analysis consisted of repeated measure Analysis of Variance, partitioned into linear and quadratic forms and used to test within subject contrasts. A pairwise comparison was applied to determine any significant differences between pretreatment (T1) to end of SBTB (T2), end of SBTB (T2) to end of FFOA (T3) and pretreatment (T1) to end of FFOA (T3). Resultant *p*-values were adjusted for multiple comparisons using the Bonferroni correction. Profile plots were also created to illustrate data trends over time.

Method error

Tracings were repeated on 10 of the original 48 radiographs selected at random. To quantify the level of random errors, all hand-tracings were replicated

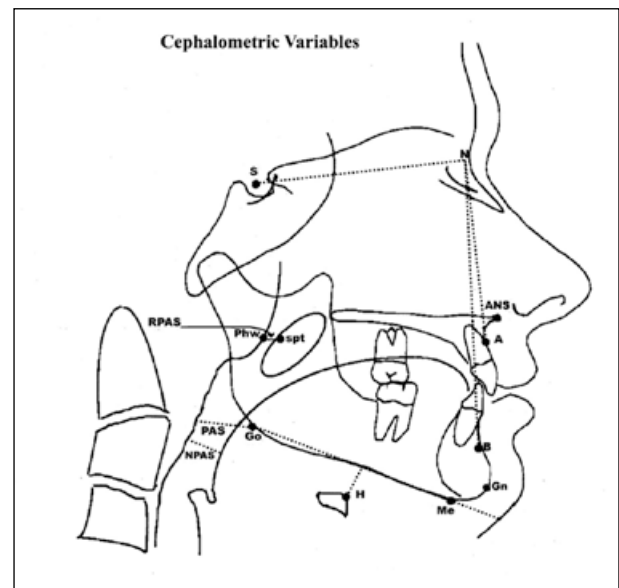


Figure 2. Cephalometric landmarks and measurements.

Definitions of cephalometric landmarks and measurements.

Anatomical landmarks: A point = deepest midline point on the maxillary alveolus between ANS and maxillary alveolar crest. B point = deepest midline point between the mandibular alveolar crest and the gnathion. N = Nasion, the most anterior part of the frontonasal suture. S = Sella, the centre of the sella turcica. Gn = Gnathion, the most anterior-inferior point on the bony mandibular symphysis. Go = Gonion, the most lateral external point at the junction of the horizontal and ascending rami of the mandible. H = Hyoidale, the most superior-anterior point on the body of the hyoid bone. Me = Menton, the lowest point on the bony outline of the mandibular symphysis. spt = tangent point on a line parallel to the long axis of the soft palate at the maximum width. Phw = Posterior pharyngeal wall, the point on the posterior pharyngeal wall at the same horizontal level as spt. MP = Mandibular plane, line joining Me and Go.

Measurements: SNA (degrees) = angle from S to N to A point. SNB (degrees) = angle from S to N to B point. ANB (degrees) = angle from A to N to B point. H-MP (mm) = perpendicular distance from the MP to H. RPAS (mm) = width of nasopharynx from Phw to spt. PAS (mm) = distance between the posterior pharyngeal wall and the dorsal surface of the base of the tongue, measured on the line that intersects Go and B point. NPAS = The most narrow region of the posterior airway above the epiglottis and below the soft palate.

and measured under the same conditions one month later. The method error in locating landmarks, superimposing and measuring the variables was evaluated by the coefficient of variation (CV). The CVs for all re-measurements were less than 1%.

Results

Table I displays the marginal mean, standard error and standard deviation for the cephalometric variables calculated at the three time-points (T1, T2 and T3). There was a reduction in the ANB angles from T1-T2 and T1-T3. SNB, however, demonstrated an increase from T1-T2 followed by a statistically

Table I. Descriptive data of the result.

Variable	Marginal mean			Std. error		
	T1	T2	T3	T1	T2	T3
SNA (°)	82.44	82.56	81.84	0.84	0.93	1.08
SNB (°)	75.25	77.41	76.63	0.67	0.72	0.88
ANB (°)	7.19	5.16	5.22	0.39	0.52	0.60
H-MP (mm)	17.28	18.31	17.75	1.29	1.76	1.50
RPAS (mm)	13.66	15.38	15.56	0.75	0.96	0.85
PAS (mm)	11.25	11.94	11.63	0.93	1.13	0.86
NPAS (mm)	8.34	9.84	9.34	0.58	0.88	0.87

Table II. Pairwise comparison between time-points (T1-T2, T2-T3, T1-T3).

Variable	T1-T2			T2-T3			T1-T3		
	Mean Diff. (T2-T1)	Std. Error	p ^a	Mean Diff. (T3-T2)	Std. Error	p ^a	Mean Diff. (T3-T1)	Std. Error	p ^a
SNA (°)	0.13	0.42	ns	-0.72	0.53	ns	-0.59	0.53	ns
SNB (°)	2.15	0.42	**	-0.78	0.46	ns	1.38	0.43	*
ANB (°)	-2.03	0.35	**	0.06	0.46	ns	-1.97	0.42	**
H-MP (mm)	1.03	1.34	ns	-0.56	1.57	ns	0.47	1.27	ns
RPAS (mm)	1.72	0.77	ns	0.19	0.82	ns	1.91	0.61	*
PAS (mm)	0.69	0.81	ns	-0.31	1.00	ns	0.38	0.80	ns
NPAS (mm)	1.50	0.66	ns	-0.50	1.12	ns	1.00	0.96	ns

*p < 0.05 **p < 0.01 *** p < 0.001 ns = not significant ^a = Bonferroni correction

insignificant decrease. The soft tissue measurement, NPAS, indicated an increase from T1-T2 and a continued increase during T2-T3. The other soft tissue measurements, H-MP and PAS, showed an increase from T1-T2 and a relapse back towards values calculated before treatment commenced.

Table II is a summary of the pairwise comparison analysis between the time-points. There was a statistically significant (**) difference from T1-T2 for SNB and ANB. Of the soft tissue variables, only RPAS demonstrated a marginally significant (*) difference between T1-T3. In a consideration of all variables, there was no significant difference between T2-T3, except the ANB angle was shown to have decreased significantly (**) between T1-T3, by an average of 2.0°, and a marginally significant increase in the SNB angle between T1-T3, by an average of 1.4°.

Figure 3 provides a graphical representation of the trend found in the marginal mean of RPAS over the course of treatment. There was an increase in the sagittal size of the nasopharynx following the use of

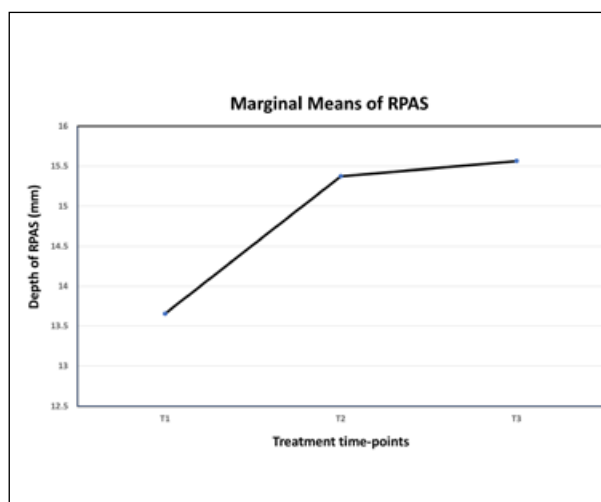


Figure 3. Marginal Means of RPAS.

SBTB appliance that was statistically insignificant. However, following FFOA therapy there was a continual increase in nasopharyngeal width, which made the change in RPAS from T1 to T3 statistically significant.

Discussion

Although SNA did not demonstrate a statistically significant change from T1 to T3, there was a significant reduction in the ANB angle by an average of 2° and a marginally significant increase in the SNB by 1.4°, which suggested a correction of the pretreatment maxillo-mandibular discrepancy. Several previous studies have found that patients with large ANB angles have a reduced PAS compared with control subjects.¹⁰⁻¹² In addition, maxillomandibular retrognathia appears to be a contributing factor related to airway constriction.¹³ Tangugsorn et al.¹ demonstrated that patients with severe sleep apnoea compared with non-severe sleep apnoea tended to display increased maxillo-mandibular retrognathism and a reduced airway space as a result. This suggested that the degree of retrognathia may be correlated with the severity of OSAS symptoms.

The results of the present study indicated that there was no statistically significant change in the size of the PAS following functional appliance therapy. This correlated with the results found in a study by Kinzinger et al.,¹⁴ in which insignificant change in PAS depth was detected with both Herbst and Functional Mandibular Advancement appliances. However, this differed from the results of an earlier study by Ozbek et al.,¹⁵ who demonstrated a significant increase of approximately 20% in the PAS following treatment with an activator device ($p < 0.001$). The findings of this study were also at variance to those of Singh et al.,¹⁶ who found that the use of a Bioblock resulted in an 8–9% increase in the PAS ($p < 0.01$). The difference in result could be explained by the different types of functional appliance used, and occipital high pull headgear was also used in the Ozbek et al.¹⁵ study. In addition, it was conceded that these studies could not accurately account for any increase that may have occurred because of normal growth. The present study cannot make the same distinction, and further investigation is needed with an age matched control group. In fact, the Cochrane Database of Systemic Reviews showed that there was a lack of evidence to confirm that oral or functional orthopaedic appliances are effective in the treatment of OSAS in children.¹⁷ However, oral or functional orthopaedic appliances are indicated in children with craniofacial anomalies who are at risk of OSAS.^{17,18}

The sagittal size of the nasopharynx as described by the variable RPAS was shown to significantly

increase from T1 to T3. The net result demonstrated an increase of approximately 2 mm compared with pretreatment measurements. Recent studies using two-dimensional or three-dimensional imaging have shown similar results.^{19,20} This indicated that the use of SBTB could alter the sagittal dimension of the nasopharynx, similar to MAS used in OSA patients. There seemed to be a continued increase in RPAS during the FFOA. This could be due to the use of Class II mechanics during FFOA and/or the corrective normal growth. Long-term follow-up is required to assess whether this increase remains stable over time. This may be of clinical importance for future sleep apnoea risk reduction efforts in growing patients.

A significant limitation of the present study was the inability to three-dimensionally assess the size of the PAS via the use of cone beam computerised tomography (CBCT) or magnetic resonance imaging (MRI). These resources would have provided a much more accurate appreciation of the effects of SBTB treatment on the PAS and other airway variables. These imaging techniques have been widely used to assess differences between non-OSAS and OSAS patients,²¹ and should similarly be used to determine the effects that orthopaedic correction of a malocclusion can have on airway size. Moreover, the three-dimensional scans should be conducted with the patient in a supine position, which is of more clinical significance when investigating the potential for OSAS risk reduction. This was confirmed by Pae et al.,²² who found that the thickness of the soft palate increased and the oropharyngeal cross-sectional area decreased when patients changed from an upright to a supine position.

The potential that the SBTB has for initiating a long-term increase in the posterior airway space and reducing the risk and/or symptoms of OSAS needs to be evaluated in young patients who suffer from the condition. A study by Robertson²³ found that, in OSAS patients who underwent mandibular advancement therapy, the posterior airway space increased by 1.28 mm over 12 months. The current study was only able to assess the effects of SBTB for a mean treatment time of approximately nine months and the patients were not diagnosed with OSAS. Perhaps a study of longer duration with a larger patient base and age-matched controls would provide further insight into the clinical relevance of SBTB treatment and OSAS risk reduction. Further studies should also assess the airway three-dimensionally via the use of CBCT or MRI.

Conclusion

The Sydney Bonded Twin Block appliance used in the correction of mandibular deficiency:

1. Significantly reduced ANB;
2. Did not significantly change the size of the PAS;
3. Increased significantly the nasopharyngeal width (RPAS) following the orthopaedic and FFOA treatment.

Corresponding author

M. Ali Darendeliler
Discipline of Orthodontics
Faculty of Dentistry
University of Sydney
Level 2, 2 Chalmers Street
Surry Hills, NSW, 2010
Australia

Email: ali.darendeliler@sydney.edu.au

Reference

1. Tangugsorn V, Skatvedt O, Krogstad O, Lyberg T. Obstructive sleep apnoea: a cephalometric study. Part I. Cervico-craniofacial skeletal morphology. *Eur J Orthod* 1995;17:45-56.
2. Athanasiou AE, Papadopoulos MA, Mazaheri M, Lagoudakis M. Cephalometric evaluation of pharynx, soft palate, adenoid tissue, tongue, and hyoid bone following the use of a mandibular repositioning appliance in obstructive sleep apnea patients. *Int J Adult Orthodon Orthognath Surg* 1994;9:273-83.
3. Schmidt-Nowara WW, Meade TE, Hays MB. Treatment of snoring and obstructive sleep apnea with a dental orthosis. *Chest* 1991;99:1378-85.
4. Villa MP, Bernkopf E, Pagani J, Broia V, Montesano M, Ronchetti R. Randomized controlled study of an oral jaw-positioning appliance for the treatment of obstructive sleep apnea in children with malocclusion. *Am J Respir Crit Care Med* 2002;165:123-7.
5. Pirsig W, Verse T. Long-term results in the treatment of obstructive sleep apnea. *Eur Arch Otorhinolaryngol* 2000;257:570-7.
6. Clark WJ. The twin block technique. A functional orthopedic appliance system. *Am J Orthod Dentofacial Orthop* 1988;93:1-18.
7. Gill D, Sharma A, Naini F, Jones S. The twin block appliance for the correction of Class II malocclusion. *Dent Update* 2005;32:158-60, 63-4, 67-8.
8. Clark W. The twin block technique. *Funct Orthod* 1990;7:24-8, 31.
9. Clark WJ. The twin block traction technique. *Eur J Orthod* 1982;4:129-38.
10. Muto T, Yamazaki A, Takeda S. A cephalometric evaluation of the pharyngeal airway space in patients with mandibular retrognathia and prognathia, and normal subjects. *Int J Oral Maxillofac Surg* 2008;37:228-31.
11. DePonte F, Sassano P, Gennaro P, Pascali M, Marchetti E. Obstructive sleep apnea in a growing patient. *J Craniofac Surg* 1999;10:430-4.
12. Trenouth MJ, Timms DJ. Relationship of the functional oropharynx to craniofacial morphology. *Angle Orthod* 1999;69:419-23.
13. Solow B, Skov S, Ovesen J, Norup PW, Wildschjødzt G. Airway dimensions and head posture in obstructive sleep apnoea. *Eur J Orthod* 1996;18:571-9.
14. Kinzinger G, Czapka K, Ludwig B, Glasl B, Gross U, Lisson J. Effects of fixed appliances in correcting Angle Class II on the depth of the posterior airway space: FMA vs. Herbst appliance--a retrospective cephalometric study. *J Orofac Orthop* 2011;72:301-20.
15. Ozbek MM, Memikoglu TU, Gögen H, Lowe AA, Baspinar E. Oropharyngeal airway dimensions and functional-orthopedic treatment in skeletal Class II cases. *Angle Orthod* 1998;68:327-36.
16. Singh GD, Garcia-Motta AV, Hang WM. Evaluation of the posterior airway space following Biobloc therapy: geometric morphometrics. *Cranio* 2007;25:84-9.
17. Carvalho FR, Lentini-Oliveira D, Machado MA, Prado GF, Prado LB, Saconato H. Oral appliances and functional orthopaedic appliances for obstructive sleep apnoea in children. *Cochrane Database Syst Rev* 2007:CD005520.
18. Villa MP, Miano S, Rizzoli A. Mandibular advancement devices are an alternative and valid treatment for pediatric obstructive sleep apnea syndrome. *Sleep Breath* 2012;16:971-6.
19. Li L, Liu H, Cheng H, Han Y, Wang C, Chen Y et al. CBCT evaluation of the upper airway morphological changes in growing patients of class II division 1 malocclusion with mandibular retrusion using twin block appliance: a comparative research. *PLoS One* 2014;9:e94378.
20. Hourfar J, Kinzinger GS, Meißner LK, Lisson JA. Effects of two different removable functional appliances on depth of the posterior airway space : A retrospective cephalometric study. *J Orofac Orthop* 2017;78:166-75.
21. Bohlman ME, Haponik EF, Smith PL, Allen RP, Bleecker ER, Goldman SM. CT demonstration of pharyngeal narrowing in adult obstructive sleep apnea. *AJR Am J Roentgenol* 1983;140:543-8.
22. Pae EK, Lowe AA, Sasaki K, Price C, Tsuchiya M, Fleetham JA. A cephalometric and electromyographic study of upper airway structures in the upright and supine positions. *Am J Orthod Dentofacial Orthop* 1994;106:52-9.
23. Robertson CJ. The effect of long-term mandibular advancement on the hyoid bone and pharynx as it relates to the treatment of obstructive sleep apnoea. *Aust Orthod J* 2000;16:157-66.