

Growth-enabling modified Groper appliance for the replacement of permanent maxillary incisors: Report of two cases

Volkan Arikan,* Duygu Ocal,† Merve Akcay,+ Ayse Tuba Altug,± Levent Ozer± and Emre Cesur‡

Faculty of Dentistry, Department of Pediatric Dentistry, University of Kirikkale, Kirikkale,* Private Practice, Pediatric Dentistry, Ankara,† Faculty of Dentistry, Department of Pediatric Dentistry, University of Katip Celebi, İzmir,+ Faculty of Dentistry, Department of Orthodontics, University of Ankara, Ankara± and Department of Orthodontics, Medipol Mega University Hospital, İstanbul,‡ Turkey

The aim of this case report is to introduce a modified Groper appliance that enables transverse growth of the maxilla in addition to improving the aesthetics of patients with missing anterior teeth. Patient 1 was a 16-year-old young woman in the late stages of growth who presented with a congenitally missing maxillary lateral incisor. Patient 2 was a nine-year-old girl missing both of her maxillary central incisors due to trauma. The missing teeth were replaced by artificial acrylic teeth bonded onto growth-enabling, maxillary, fixed palatal space maintainers. A tube was soldered onto one of the arch wires of the maintainer and the opposite arch wire was threaded into this tube, allowing it to slide until the patient completed growth. Intermolar width increased by approximately 1.9 mm in Patient 1 and 2.6 mm in Patient 2 over the three-year review period. The in-tube mechanical design of the device allowed transverse growth of the maxilla without interference during and throughout long-term wear. (Aust Orthod J 2020; 36: 108-113)

Received for publication: February 2019

Accepted: November 2019

dt.volkan@yahoo.com; aticiduygu@gmail.com; merve.akcay@ikcu.edu.tr; aysealtug@yahoo.com; ozer@dentistry.ankara.edu.tr; emre-cesur@hotmail.com

Introduction

Treatment planning for patients affected by traumatised or congenitally missing teeth involves a detailed evaluation of the prognosis of the injured tooth and recovery of the edentulous space. Dental injuries most frequently occur in young children and involve the upper incisors.¹ It is functionally, aesthetically and, above all, psychologically crucial to replace the maxillary permanent incisors when they are traumatically lost.^{2,3}

There are several treatment options available for missing anterior teeth. Orthodontic space closure, autotransplantation of avulsed teeth, transplantation of teeth from other sites of the dental arches, fixed dentures, and dental implants are potentially viable options.⁴⁻⁶ However, the majority of these methods

can only be considered if the patient has completed growth.^{7,8} For patients who are still growing, space maintainers are currently the most appropriate appliances available and can be used until the patient is ready for permanent prosthetics.

These case reports describe the treatment of two patients with missing maxillary incisors managed by using a modified growth-enabling Groper appliance as a temporary space-maintaining option.

Subjects and methods

Construction of the space maintainers

At the first appointment, stainless steel molar bands were adjusted to either the maxillary first permanent molars or healthy deciduous molars. Maxillary

impressions and a working cast were obtained with the molar bands fitted onto the plaster. Two segments of 1 mm orthodontic stainless steel wire (Dentaaurum, Remanium) were contoured to follow the palatal gingival margins from the first-molar bands to the anterior edentulous space. The distal ends of the wires were bilaterally soldered to the palatal surfaces of the first-molar bands. A tube with an inner diameter slightly larger than the diameter of the arch wires was soldered onto one of the arch wires, and the end of the opposite arch wire was inserted into this tube, allowing it to slide freely (Figure 1a). The starting position of the sliding wire within the tube was marked with a diamond disk so that growth could be monitored at review appointments. Acrylic teeth of the appropriate colour and shape for the edentulous space were chosen, and pink acrylic resin was applied to adapt the teeth to the gingiva and bond the tooth over the loop (Figure 1b). The resin was polymerised in a hydroflask (Dikan 105 pressure pot, Turkey), and the appliance was removed from the cast and finished. Following satisfactory trials and occlusal adjustments, the appliance was cemented in place at the same appointment using glass ionomer cement (Kavitan CEM, SpofaDental, Czech Republic).

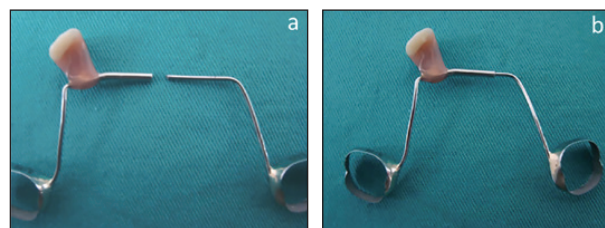


Figure 1. The appliance design (growth-enabling modified fixed palatal space maintainer): a) the appliance in two pieces; b) the appliance before insertion.

Case 1

A 16-year-old girl was referred to the orthodontic clinic following the loss of her right permanent lateral incisor (Figure 2a-b). She was in the late stages of skeletal growth (Figure 2c). A growth-enabling fixed space maintainer was placed (Figure 2d-e) and the patient and her parents were provided with hygiene instructions. The first review appointment was at one week, followed by appointments at one, three, six, 12, 18, 24, and 36 months. The patient did not express any discomfort related to the appliance during the observation period.

At the 18-month clinical examination, 1 mm of expansion was noted on the sliding wire of the space

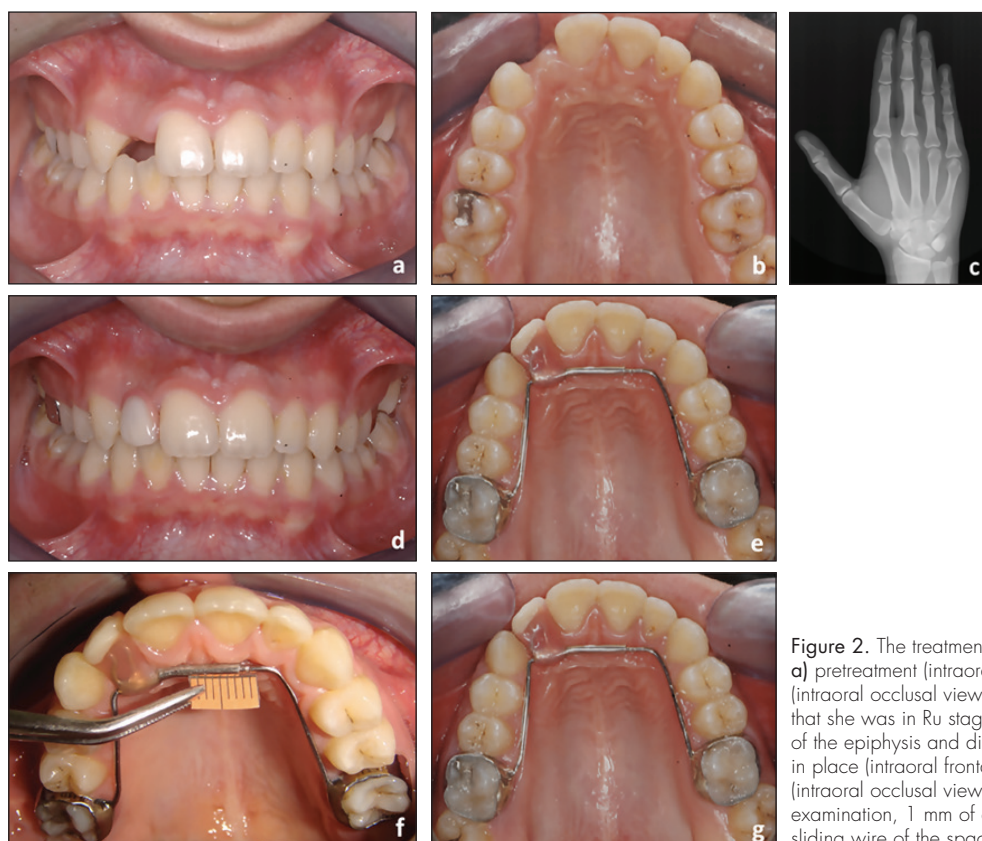


Figure 2. The treatment progress of Patient 1: a) pretreatment (intraoral frontal view); b) pretreatment (intraoral occlusal view); c) hand-wrist radiograph revealed that she was in Ru stage of skeletal development (union of the epiphysis and diaphysis of radius); d) appliance in place (intraoral frontal view); e) appliance in place (intraoral occlusal view); f and g) at 18-month clinical examination, 1 mm of expansion was observed on the sliding wire of the space maintainer.

maintainer (Figure 2f). No significant additional expansion was observed at 24 or 36 months (Figure 2g). Calliper measurements were also taken on study models, and changes in the intercanine and intermolar widths are presented in Table I.

Case 2

A nine-year-old girl was referred to the orthodontic clinic for management of missing central incisors due to avulsion that had occurred two weeks earlier (Figure 3a). She was still in the early stages of skeletal growth (Figure 3b).

The appliance was prepared as described for Patient 1, with two acrylic teeth placed in the edentulous space and stainless steel molar bands fitted to the maxillary deciduous second molars (Figures 3c-e). The review protocol was similar to that of the previous patient.

At the 18-month clinical examination, 1.5 mm of expansion was observed on the sliding wire of the space maintainer (Figure 3f). Calliper measurements were also made on study models. The changes in intermolar widths are presented in Table II. At 24 months, the space maintainer was replaced due to continuing dental development (Figure 3g). The new appliance was designed with the same growth-enabling mechanism (Figure 3h).

Discussion

There is no standard treatment procedure for the replacement of permanent teeth lost due to trauma, especially in cases occurring prior to growth completion.⁷ Following the loss of an anterior permanent tooth, it is important that an immediate replacement is provided in order to avoid aesthetic, masticatory, and speech difficulties and to maintain the edentulous space.²

Transplantation or autotransplantation of the avulsed tooth

In the case of avulsion, replantation of the tooth/teeth is a possible option, although the long-term prognosis is uncertain due to the risks of resorption or ankylosis.⁹ Despite its disadvantages, replantation is still considered an acceptable method for the urgent management of avulsed teeth. Patient 2 had avulsed teeth, but presented two weeks after the incident, by which time the teeth had been lost. Therefore,

Table I. Study model measurements of the intercanine and intermolar widths in Patient 1.

Patient 1	Intercanine width (mm)	Intermolar width (mm)
Beginning	33.6	50.1
6-month follow-up	34.3	51.7
1-year follow-up	34.7	51.9
3-year follow-up	34.9	52.0

Table II. Study model measurements of the intermolar widths in Patient 2. (Note that the patient had no permanent maxillary canines at the time of space maintainer fitting. Therefore, no intercanine measurements were performed.)

Patient 2	Intermolar width (mm)
Beginning	51.2
6-month follow-up	51.4
3-year follow-up	53.8

replantation was not an option for either of the presenting patients. The main challenge in treating patients with missing upper incisors is to achieve the best aesthetic and functional results in the long term.¹⁰ Autotransplantation of premolars to replace missing teeth in growing patients has become a treatment alternative with the potential for bone induction and alveolar process development.¹¹ Czochrowska et al. reported that, with careful interdisciplinary treatment, transplantation of premolars to replace missing incisors has the potential to produce satisfactory results.¹¹ According to an additional study performed by Czochrowska et al., transplantation of developing premolars in children yields successful outcomes decades later.¹² This conclusion was based on the high observed survival rates (90%) of 33 transplanted teeth followed up for a period of 26 years. Jonsson and Sigurdsson also claimed that when there is a choice between dental implants and transplanted premolars, it should be noted that implants are artificial structures that do not have normal periodontal ligaments.¹³ Therefore, autotransplantation may be the best option to obtain an improved functional result. Orthodontic movement of a transplant may optimise its position before restoration of the crown.¹¹ Orthodontic treatment would also be necessary after extracting the transplanted tooth from its donor site in order to detail the occlusion. Both described patients had Class I occlusions with no crowding. Although autotransplantation is a viable option for growing

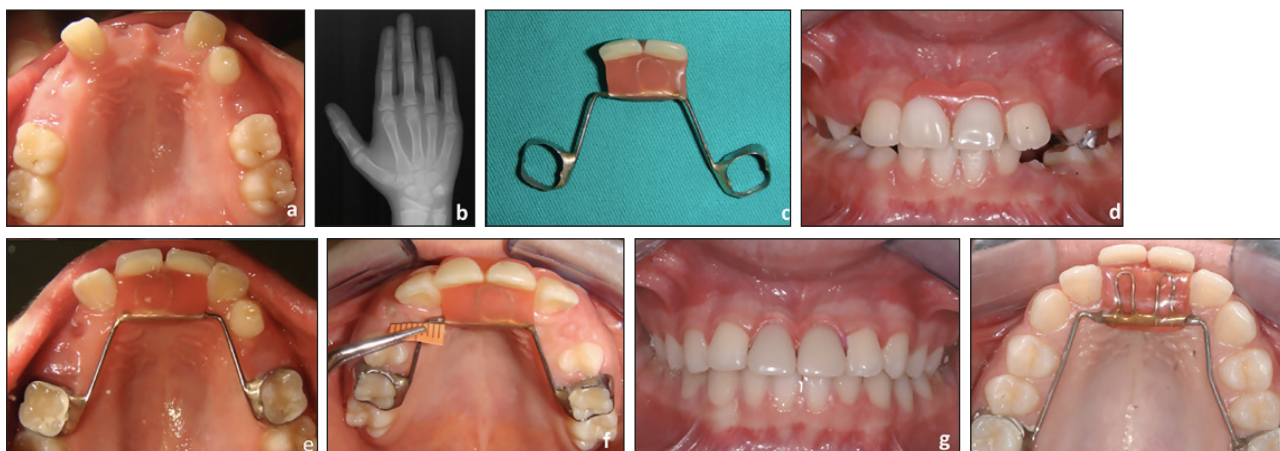


Figure 3. The treatment progress of Patient 2: **a)** pretreatment (intraoral occlusal view); **b)** hand-wrist radiographs showed that the patient was at MP3= stage (epiphysis of the middle phalanx of the middle finger was found to be as wide as the diaphysis); **c)** space maintainer before insertion; **d)** appliance in place (intraoral frontal view); **e)** appliance in place (intraoral occlusal view); **f)** at 18-month clinical examination, 1.5 mm of expansion was observed on the sliding wire of the space maintainer; **g and h)** at 24-month follow-up, a new appliance was designed.

patients, it was preferred that the existing space was maintained to spare the patients from the burden of an unnecessary orthodontic treatment.

Arch width changes

In their milestone implant study, Björk and Skieller demonstrated that transverse growth of the maxilla continued beyond puberty until the completion of growth.¹⁴ Gandini and Buschang reported that there was significant widening of the basal mandibular and maxillary skeletal structures during late adolescence due to growth potential.¹⁵ Hesby et al. evaluated maxillary and mandibular width changes in 36 untreated Class 1 subjects and reported a 0.38 mm annual width increase at the level of the maxillary molars until the age of 26.4 years.¹⁶

Prosthetics

Removable acrylic prostheses, porcelain-fused-metal bridges, resin-bonded fixed partial dentures (Maryland bridges), and fibre-reinforced composite bridges could be considered in similar cases.¹⁷ However, most cannot be used in developing patients due to concerns regarding ongoing maxillary growth.⁸ As the prostheses splint adjoining teeth together, there is a high risk of local growth restriction, especially during the critical period during which a significant increase in intercanine distance occurs.² The disadvantages of removable acrylic prostheses include potential loss or breakage, patient non-compliance and, most importantly, restriction of maxillary or mandibular

growth due to material stiffness. Moreover, the presence of a large palatal acrylic mass makes adaptation to the appliance difficult.¹⁸

Dental implants

Dental implants are a widely accepted method for managing edentulous spaces. However, İşeri and Solow reported that once an artificial tooth implant has osseointegrated into a growing alveolus, there will be no further alveolar development at the implant site, while growth in adjacent regions still continues in the three dimensions.⁷ Artificial teeth on osseointegrated implants behave like ankylosed teeth and, in growing individuals, can result in infra-occlusion due to the continued eruption of neighbouring teeth.^{19,20}

Space maintainers

Space maintenance forms an integral part of preventive and interceptive orthodontics and paediatric dentistry.³ After the premature loss of a tooth, not only do space maintainers preserve function and arch length, they also maintain aesthetics and eliminate any potential psychological damage a child could face as a result of the premature loss of teeth.³ The space maintainer also allows the permanent teeth to erupt unhindered into proper alignment and occlusion.

Removable space maintainers have the advantage of being modifiable by adding or removing acrylic resin.¹⁷ However, they can easily be fractured, and the large acrylic palatal coverage can cause discomfort.^{17,21} Removable maintainers require a high level of patient

compliance, which is difficult to achieve when long-term use is needed. In addition, space maintainers may also have adverse effects on maxillary growth similar to removable prostheses.²²

The Groper appliance was first introduced in 1984 to avoid the negative impact of early anterior tooth loss on aesthetics and function.³ The appliance is similar to a Nance holding arch, but with plastic teeth attached to a wire instead of a palatal acrylic button in the rugae area. A valid reason for replacing missing incisors is to restore a natural and pleasing appearance and thus provide an opportunity for normal psychological development. As children grow and develop, they continually formulate a self-image about their bodies.²³ Other notable advantages of this appliance are that it restores masticatory efficacy, facilitates speech, and prevents the development of abnormal oral habits. The main disadvantage is the accumulation of food debris. Therefore, patients and their parents must be carefully informed about the importance of oral hygiene.²⁴

Effects of space maintainers on arch width in growing children

Changes in intercanine arch width and perimeter mostly occur during the transition from the mixed to the permanent dentition.²² Because removable space maintainers are rigid appliances made of acrylic resin, they are more likely to interfere with the growth of the maxilla and mandible. Dincer et al. investigated the effects of removable space maintainers on the growth of maxillary and mandibular dental arches.²² A significant widening in untreated control subjects was reported, while intercanine width remained unchanged in patients treated with removable space maintainers. In response to these findings, it was recommended that removable maintainers be constructed and modified periodically so that dental and dentoalveolar growth was not inhibited. Several designs for fixed space maintainers with a pontic placed on the anterior part of the wire have also been presented.^{1,9,25} However, these appliances also risk interfering with maxillary growth since they have no expansion capability other than the flexibility of the arch wire used, and they may need to be replaced periodically.

The present study introduces a novel appliance that aims to manage continuing alveolar development changes by passively enabling transverse maxillary

growth for an extended time period, and thereby eliminate the need to remake the appliance.

In the presented cases, varying amounts of expansion of the appliances were observed: 1 mm for Patient 1 and 1.5 mm for Patient 2 over an 18-month review period. The difference in expansion was presumably the result of the patients' different growth rates. The most striking result was observed in the first patient, who was in the later stages of growth, with a 1-mm expansion in an 18-month period. This change in the transverse dimension of the maxilla demonstrates that, at the time of the study, the patient was still growing, and no permanent treatment options should have been considered.

Conclusion

The growth-enabling, modified fixed-palatal retainers presented in these case reports provide a new treatment option for the replacement of missing anterior teeth. The appliances allow unhindered growth, offer increased comfort, and can be considered as a durable provisional treatment option for cases in which implant therapy will be performed at a later date.

Corresponding author

Dr. Emre Cesur
Assistant Professor
Department of Orthodontics
Medipol Mega University Hospital
İstanbul
Turkey
Email: emre-cesur@hotmail.com

References

1. Malmgren O, Malmgren B. Orthodontic management of the traumatized dentition. In: Andreasen JO, Andreasen FM, Andersson L, eds. Textbook and Color Atlas of Traumatic Injuries to the Teeth. 4th edn. Munksgaard: Blackwell Publishing Co., 2007;669-711.
2. Ashley M, Holden V. An immediate adhesive bridge using the natural tooth. Br Dent J 1998;10;184:18-20.
3. Jasmin JR, Groper JN. Fabrication of a more durable fixed anterior esthetic appliance. ASDC J Dent Child 1984;51:124-7.
4. Zachrisson BU. Planning esthetic treatment after avulsion of maxillary incisors. J Am Dent Assoc 2008;139:1484-90.
5. Creugers NHJ, Kreulen CM. Resin-related bridges and conventional bridges in the anterior region. In: Andreasen JO, Andreasen FM, Andersson L, eds. Textbook and Color Atlas of Traumatic Injuries to the Teeth. 4th edn. Munksgaard: Blackwell Publishing Co., 2007;729-39.
6. Andreasen JO, Ödman J, Hämmerle C, Buser D, Von Arx T, Jensen

- J et al. Implants in the anterior region. In: Andreasen JO, Andreasen FM, Andersson L., eds. *Textbook and Color Atlas of Traumatic Injuries to the Teeth*. 4th edn. Munksgaard: Blackwell Publishing Co., 2007;761-90.
7. İşeri H, Solow B. Continued eruption of maxillary incisors and first molars in girls from 9 to 25 years, studied by the implant method. *Eur J Orthod* 1996;18:245-56.
 8. Moorrees CF, Gron AM, Le Bret LM, Yen PK, Fröhlich FJ. Growth studies of the dentition: a review. *Am J Orthod* 1969;55:600-16.
 9. Ulusoy AT, Cehreli ZC. Provisional use of a natural tooth crown following failure of replantation: a case report. *Dent Traumatol* 2008;24:96-9.
 10. Zachrisson BU, Stenvik A, Haanaes HR. Management of missing maxillary anterior teeth with emphasis on autotransplantation. *Am J Orthod Dentofacial Orthop* 2004;126:284-8.
 11. Czochrowska EM, Stenvik A, Zachrisson BU. The esthetic outcome of autotransplanted premolars replacing maxillary incisors. *Dent Traumatol* 2002;18:237-45.
 12. Czochrowska EM, Stenvik A, Bjercke B, Zachrisson BU. Outcome of tooth transplantation: survival and success rates 17-41 years posttreatment. *Am J Orthod Dentofacial Orthop* 2002;121:110-9.
 13. Jonsson T, Sigurdsson TJ. Autotransplantation of premolars to premolar sites. A long-term follow-up study of 40 consecutive patients. *Am J Orthod Dentofacial Orthop* 2004;125:668-75.
 14. Björk A, Skieller V. Normal and abnormal growth of the mandible. A synthesis of longitudinal cephalometric implant studies over a period of 25 years. *Eur J Orthod* 1983;5:1-46.
 15. Gandini LG Jr, Buschang PH. Maxillary and mandibular width changes studied using metallic implants. *Am J Orthod Dentofacial Orthop* 2000;117:75-80.
 16. Hesby RM, Marshall SD, Dawson DV, Southard KA, Casco JS, Franciscus RG et al. Transverse skeletal and dentoalveolar changes during growth. *Am J Orthod Dentofacial Orthop* 2006;130:721-31.
 17. Chafaie A, Portier R. Anterior fiber-reinforced composite resin bridge: a case report. *Pediatr Dent* 2004;26:530-4.
 18. Sharma AB, Vargervik K. Using implants for the growing child. *J Calif Dent Assoc* 2006;34:719-24.
 19. Smith RA, Vargervik K, Kearns G, Bosch C, Koumjian J. Placement of an endosseous implant in a growing child with ectodermal dysplasia. *Oral Surg Oral Med Oral Pathol* 1993;75:669-73.
 20. Thailander B, Odman J, Gröndahl K, Lekholm U. Aspects on osseointegrated implants inserted in growing jaws: A biometric and radiographic study in young pigs. *Eur J Orthod* 1992;14:99-109.
 21. Smidt A. Esthetic provisional replacement of a single anterior tooth during the implant healing phase: A clinical report. *J Prosthet Dent* 2002;6:598-602.
 22. Dincer M, Haydar S, Unsal B, Turk T. Space maintainer effects on intercanine arch width and length. *J Clin Pediatr Dent* 1996;21:47-50.
 23. Waggoner WF, Kupietzky A. Anterior esthetic fixed appliances for the preschooler: considerations and a technique for placement. *Pediatr Dent* 2001;23:14750.
 24. Joybell CC, Ramesh K, Simon P, Mohan J, Ramesh M. Dental rehabilitation of a child with early childhood caries using Groper's appliance. *J Pharm Bioallied Sci* 2015;7:S704-7.
 25. Pithon MM, Mendes EB, de Souza RA, De Freitas LM. A space maintainer for growing patients with avulsed central incisors. *J Clin Orthod* 2012;46:27-30.