

## Extramedullary Plasmacytomas of the Oral Cavity: A Case Report and Review of the Literature

Roxanne Bavarian<sup>1,2</sup>, Nathaniel S. Treister<sup>2,3</sup>

<sup>1</sup>Department of Oral and Maxillofacial Surgery, Massachusetts General Hospital, Boston, Massachusetts, United States, <sup>2</sup>Department of Oral Medicine, Infection, and Immunity, Harvard School of Dental Medicine, Boston, Massachusetts, United States, <sup>3</sup>Department of Oral Medicine and Dentistry, Brigham and Women's Hospital, Boston, Massachusetts, United States

Received: 20 June 2021/Accepted: 25 June 2021



### OPEN ACCESS

**Correspondence:** Roxanne Bavarian, Department of Oral and Maxillofacial Surgery, Massachusetts General Hospital, 55 Fruit St, Boston, Massachusetts 02114, United States. E-mail: Roxanne\_bavarian@hsdm.harvard.edu

**Citation:** Bavarian R, Treister NS. Extramedullary Plasmacytomas of the Oral Cavity: A Case Report and Review of the Literature. J Cancer Allied Spec [Internet]. 2021 May 31;7(2):XXX. <https://doi.org/10.37029/jcas.v7i2.417>

**Copyright:** © 2021 Bavarian and Treister. This is an open access article distributed under the terms of the Creative Commons Attribution License, which permits unrestricted use, distribution, and reproduction in any medium, provided the original author and source are credited.

**Funding:** The authors received no financial support for the research, authorship and/or publication of this article.

**Competing interest:** Nil.

### Abstract

**Introduction:** Multiple myeloma is a haematologic malignancy characterised by the proliferation of plasma cells and typically presents with lesions in bone, known as plasmacytomas. Through haematogenous spread, extramedullary plasmacytomas can develop in soft tissue in any location of the body. This case report describes a patient with multiple myeloma who presented with an extramedullary plasmacytoma on his maxillary gingiva and provides an updated review on the classification and characterisation of extramedullary plasmacytomas of the oral cavity.

**Case Description:** A 53-year-old male with a known diagnosis of multiple myeloma was referred to our clinic for evaluation of a gingival nodule, which was tender to palpation and had been present for a month. Clinical examination revealed a 1.5 cm violaceous, red nodule of the maxillary buccal attached gingiva, which did not blanch on palpation. He had a similar 1 cm, smooth, red nodule of his cutaneous skin on his left arm. Radiographic examination was within normal limits without evidence of dental or bony pathology. An incisional biopsy revealed the diagnosis of plasmacytoma, indicating relapse and progression of the patient's multiple myeloma.

**Practical Implications:** Multiple myeloma can present in the oral cavity either as intrabony plasmacytomas, paraskelatal plasmacytomas or extramedullary plasmacytomas in the soft tissue. Extramedullary disease representative of haematogenous spread is concerning for high-risk disease with a poor risk prognosis.

**Key words:** Case report, multiple myeloma, oral cavity, oral plasmacytoma, oral tumours, plasmacytoma

### Introduction

Multiple myeloma is a haematologic malignancy characterised by the proliferation of clonal plasma cells and represents 2% of all cancers and 19% of

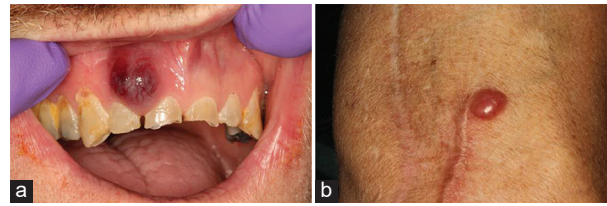
haematologic malignancies in the United States.<sup>[1]</sup> While the condition most commonly presents with multiple lytic lesions in bone, plasma cell neoplasms can also present as a solitary lesion, either in bone, known as a solitary plasmacytoma, or in soft

tissue, known as an extramedullary plasmacytoma. Extramedullary plasmacytomas have recently been classified as being true extramedullary lesions that are completely in soft tissue, or paraskelatal, with evidence of soft-tissue tumour masses developing from underlying bony lesions.<sup>[2]</sup> Extramedullary lesions have been documented in nearly every organ and tissue of the body. They can represent a solitary lesion that will not necessarily be associated with or progress into multiple myeloma or can be a sign of progressive disease with high-risk cytogenetics and resistance to therapy.<sup>[3,4]</sup> We herein present a case of an extramedullary plasmacytoma presenting as a gingival nodule in the oral cavity and provide a review of the literature of the variable presentations of extramedullary plasmacytomas in the oral cavity using the most recent classification scheme of plasmacytomas.

### Case Description

A 53-year-old male was referred to our clinic by his oncologist for evaluation of a nodule on his maxillary gingiva. He reported that the nodule had been present for approximately 1 month and was tender to the touch and on tooth brushing, with a pain intensity of 2/10. He also noticed a similar nodule growing on the skin of his left arm within the past month. His medical history was significant for kappa light chain multiple myeloma, which was diagnosed 7 years before the consult. He had undergone extensive prior treatment, including an autologous stem cell transplant 6 years prior, which was complicated by progressive disease and then treated with salvage chemotherapy followed by a reduced intensity conditioning allogeneic stem cell transplant 2 years before the visit. Due to progressive disease, he was then treated with panobinostat, bortezomib and dexamethasone, which was discontinued 1 month before our consultation due to the development of pneumonia secondary to immunosuppression, as well as progressive disease.

Examination revealed a 1.5 cm diameter nodule on the maxillary gingiva on the buccal aspect of right side maxillary lateral and central incisors [Figure 1a]. The lesion was smooth-surfaced and violaceous in colour,



**Figure 1:** A 53-year-old male with (a) violaceous-red nodule of the maxillary buccal gingiva of the right side maxillary lateral and central incisors and (b) a 1 cm, red, smooth-surfaced nodule of the anterior (flexor) surface of the arm near the elbow

with a vascular appearance with red capillaries visible on the surface. It was firm, non-pulsatile and did not blanch when compressed. Radiographic examination with a full mouth series of dental radiographs showed no periapical radiolucencies of the adjacent teeth and no evidence of bony pathology. The rest of the examination was within normal limits in the head and neck; however, he had a similar smooth-surfaced cutaneous, red nodule measuring 1.5 cm in diameter on the skin of the left arm [Figure 1b]. The differential diagnosis included extramedullary plasmacytoma, pyogenic granuloma, peripheral giant cell granuloma, peripheral ossifying fibroma, vascular tumour (e.g., Kaposi sarcoma) and vascular malformation.

### Diagnosis and management

Incisional biopsy of the oral lesion confirmed the definitive diagnosis of an extramedullary plasmacytoma. Given his refractory multiple myeloma with now extramedullary involvement, the patient received palliative radiation for the extramedullary plasmacytomas (20 Gray units administered in five fractions). For his generalised progression of multiple myeloma, he was enrolled in a clinical trial of daratumumab, a monoclonal antibody that targets CD38 proteins expressed on myeloma cells; however, the patient continued to have progressive disease and passed away 4 months after the consultation visit.

### Discussion

In this case, a patient with progressive multiple myeloma known to be resistant to multiple lines of therapy presented with a gingival nodule that was

biopsy proven to be an extramedullary plasmacytoma. Soft-tissue extramedullary plasmacytomas such as this are proposed to arise from the haematogenous spread of the neoplastic plasma cells. Incidence of extramedullary plasmacytomas (excluding paraskelatal plasmacytomas) ranges from 1.7 to 4.5% at the time of diagnosis, but in patients with progressive disease and relapse has an incidence of up to 10%.<sup>[2]</sup> Lesions most commonly present in the skin, liver pleura, breast, lymph nodes and central nervous system. When visible, lesions most commonly present as nodules that appear highly vascularised with a red-purple appearance, as seen in both the oral and cutaneous nodules in the present case.

In the oral cavity, case reports exist describing both paraskelatal extramedullary lesions and true extramedullary lesions arising in soft tissue without evidence of radiographic involvement. In paraskelatal oral lesions, patients will present with a large mass of the maxillary or mandibular alveolar ridge, with the overlying gingiva and mucosa ranging from pink and healthy in appearance to erythematous, ulcerated or necrotic.<sup>[5-7]</sup> For true extramedullary lesions without underlying bony involvement, lesions have been reported in the gingiva, buccal mucosa, labial mucosa, tongue and uvula.<sup>[8,9]</sup> One report described an extramedullary plasmacytoma that presented as a flat, non-tender erythematous macule, or erythroplakia, of the soft palate.<sup>[10]</sup> While plasmacytomas in the buccal and labial mucosa, tongue and uvula are clearly in soft tissue and represent the haematogenous spread of plasma cells, the gingiva represents a site of soft tissue that is attached to the underlying alveolar bone of the maxilla or mandible. In the case of gingival plasmacytomas, distinguishing between a paraskelatal and extramedullary plasmacytoma based on the most recent definitions is challenging, and a thorough radiographic examination with a computerised tomography (CT) scan would be needed to definitively determine whether there is bony involvement. However, such imaging is not always necessary from a clinical standpoint – diagnosis is typically confirmed with an incisional biopsy in the oral cavity. In lesions where access for

biopsy is not possible, magnetic resonance imaging or fluorodeoxyglucose (FDG)-positron emission tomography/CT (FDG-PET/CT) is recommended to assess the extent of soft-tissue disease.<sup>[2]</sup>

In this case report, the patient had progression of his multiple myeloma despite multiple lines of therapy. The presence of multiple extramedullary plasmacytomas of the skin and oral cavity, revealing the haematogenous spread of clonal plasma cells, represented relapse of his disease and an overall poor prognosis. For patients with relapse of multiple myeloma presenting with extramedullary disease, recommendations include consideration of an allogeneic stem cell transplant or salvage chemotherapy with a lymphoma-like regimen such as cisplatin, doxorubicin, cyclophosphamide and etoposide (PACE). Alternative treatment options include regimens containing novel therapeutics, such as carfilzomib or selinexor. In refractory, relapsed patients, autologous chimeric antigen receptor T-cell treatment is another therapeutic option that utilises a targeted approach to attack malignant plasma cells by modifying T-cells to selectively target the B-cell maturation antigen present on the plasmacytoma surface.<sup>[11,12]</sup> In our case, because the patient had developed resistance to many of the above treatments, he instead received radiation therapy to the extramedullary lesions and enrolled in a clinical trial with daratumumab.

In conclusion, this case report describes an extramedullary plasmacytoma presenting as a violaceous nodule on the maxillary buccal gingiva without radiographic evidence of underlying bony involvement in a 53-year-old man with progressive, treatment-resistant multiple myeloma. Extramedullary plasmacytomas in the oral cavity have been documented as masquerading as benign-appearing, homogeneous pink or red nodules in the gingiva, buccal or labial mucosa and tongue. Patients who present with an extramedullary plasmacytoma as the heralding lesion of multiple myeloma should be considered as having high-risk disease, whereas similarly patients with a known

diagnosis of multiple myeloma presenting with an extramedullary plasmacytoma at relapse have an extremely poor prognosis.

### Disclosure

Drs. Bavarian and Treister have no conflicts of interest or financial ties to disclosure.

### References

1. Siegel RL, Miller KD, Fuchs HE, Jemal A. Cancer statistics, 2021. *CA Cancer J Clin* 2021;71:7-33.
2. Rosiñol L, Beksac M, Zamagni E, Van de Donk NW, Anderson KC, Badros A, et al. Expert review on soft-tissue plasmacytomas in multiple myeloma: definition, disease assessment and treatment considerations. *Br J Haematol* 2021. doi: 10.1111/bjh.17338. Epub ahead of print.
3. Billecke L, Penas EM, May AM, Engelhardt M, Nagler A, Leiba M, et al. Cytogenetics of extramedullary manifestations in multiple myeloma. *Br J Haematol* 2013;161:87-94.
4. Rasche L, Bernard C, Topp MS, Kapp M, Duell J, Wesemeier C, et al. Features of extramedullary myeloma relapse: High proliferation, minimal marrow involvement, adverse cytogenetics: A retrospective single-center study of 24 cases. *Ann Hematol* 2012;91:1031-7.
5. Shetty P, Lobo FD, Arvind R, Shetty SS. Oral extramedullary plasmacytoma in a HIV positive patient. *Oral Oncol* 2017;64:e4-5.
6. Trivedi S, Dixit J, Goel MM. Extramedullary plasmacytoma of the gingiva. *BMJ Case Rep* 2016;2016:211606.
7. Mumtaz S. Plasmacytoma. *Oral Oncol* 2018;82:196-7.
8. Han JH, Woo YJ, Kang H, Kim JE. Primary extramedullary plasmacytoma mimicking oral lichen planus. *Eur J Dermatol* 2017;27:533-4.
9. Basile FG, Shi M, Sullivan M. Solitary plasmacytoma of the uvula. *Am J Hematol* 2014;89:660-1.
10. Lalla F, Vinciguerra A, Lissoni A, Arrigoni G, Luce FL, Abati S. Solitary extramedullary plasmacytoma presenting as asymptomatic palatal erythroplakia: Report of a case. *Int J Environ Res Public Health* 2021;18:3762.
11. Raje N, Berdeja J, Lin Y, Siegel D, Jagannath S, Madduri D, et al. Anti-BCMA CAR T-cell therapy bb2121 in relapsed or refractory multiple myeloma. *N Engl J Med* 2019;380:1726-37.
12. Cohen AD, Garfall AL, Stadtmauer EA, Melenhorst JJ, Lacey SF, Lancaster E, et al. B cell maturation antigen-specific CAR T cells are clinically active in multiple myeloma. *J Clin Invest* 2019;129:2210-21.

### Authorship Contributions

Conceived and designed the analysis: RB and NT, collected the data: RB, contributed data or analysis tools: NT, performed the analysis: N/A, wrote the paper: RB and NT.