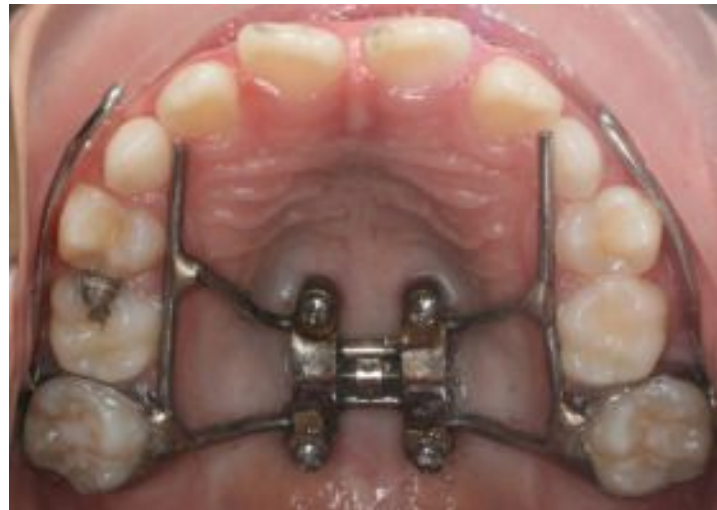

Complications Reported in Maxillary Skeletal Expanders (MSE)

Jacqueline Payne, Kristen Lo, Connor Turley, Elizabeth Yee

Background

- MSE: non-surgical maxillary expander that uses temporary anchorage devices in the palate
 - Alternative: surgically assisted rapid palatal expansion (SARPE)
- Relatively new and therefore there has not been a study thus far on the complications that can occur with this appliance




Clinical Implication

- To make clinicians, who may be adopting skeletal expanders, aware of the possible complications that can occur



Aim of the study

- The aim of this study was to determine the types and prevalence of complications following MSE protocol at University of the Pacific.



Materials

- Retrospective Study
- 97 patients started MSE expansion between November 2015 and July 2020
- 57 females/ 40 Males
- Average Age at beginning of treatment was 16 yo (range 9-32 yo)
- 31 had Facemask + MSE expansion
- Depending on the size of the patient's palate, the patient received 8 mm, 10 mm, or 12 mm MSE
- Used both Type I and Type II MSE

Methods

1 rater read through all chart notes for patients who were reported to have MSE expansion from the clinic's adoption of the device in Fall of 2015 up until July of 2020

Using chart notes and photos, the prevalence of complications relating to MSE expansion were noted

For **inflammation complication**, inflammation ratings were taken using progress photos taken immediately following MSE expansion and pre-removal of MSE. Ratings of Arms vs. MSE body were taken separately. 2 raters scored photos.



Complication Definitions

Diastema-

- **1:** Pt exhibited space between upper incisors either in pictures or recorded in notes.
- **0:** Notes explicitly stated pt did not get a diastema or that skeletal expansion failed

Inadequate expansion

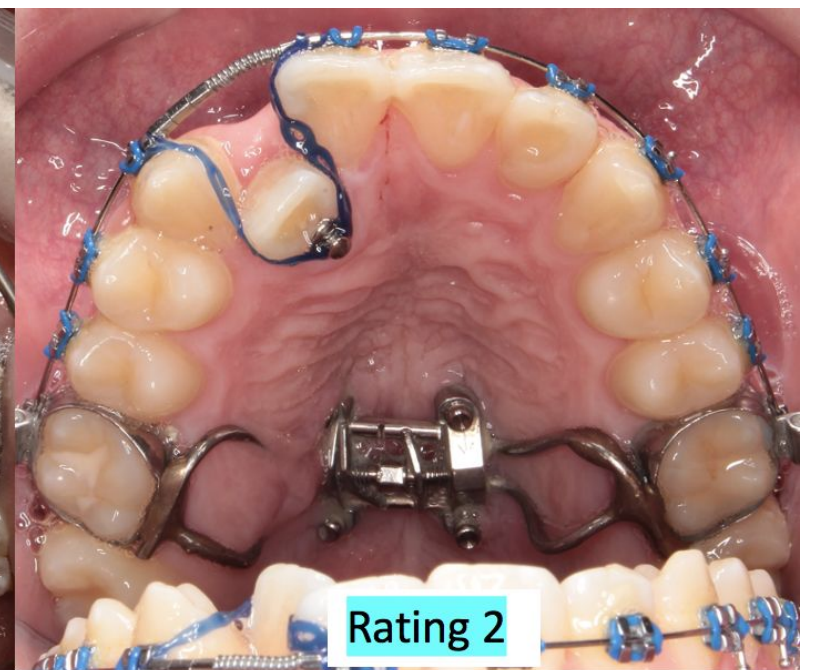
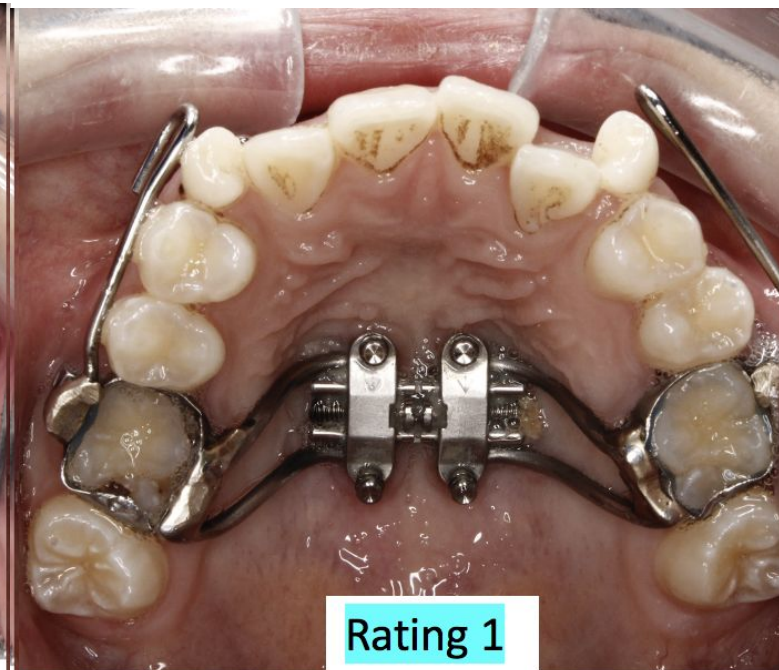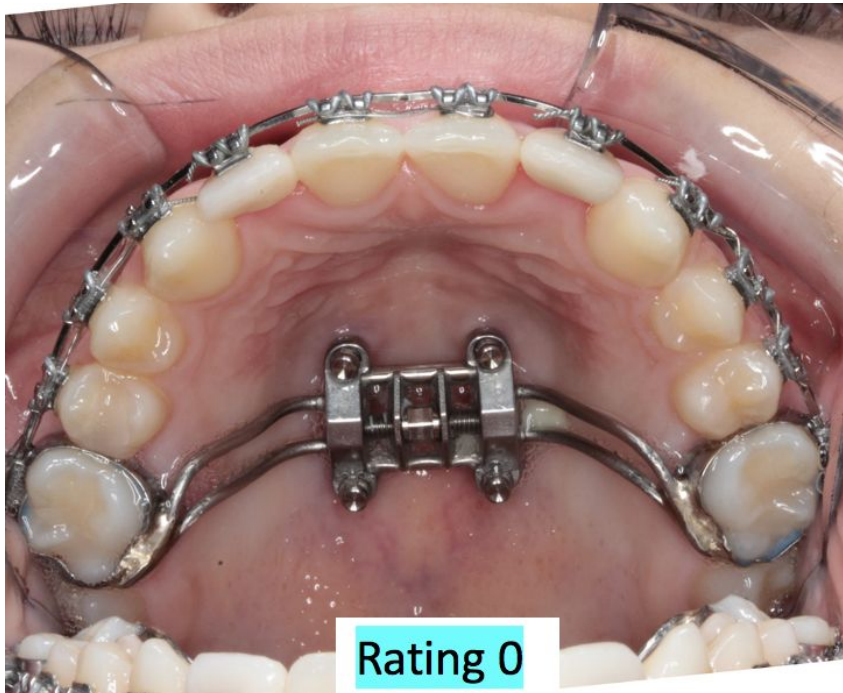
- **1:** a 2nd MSE expander was placed according to notes or the MSE failed and a 2nd expander was not placed
- **0:** no additional expander was placed according to notes/ adequate expansion occurred

Pain

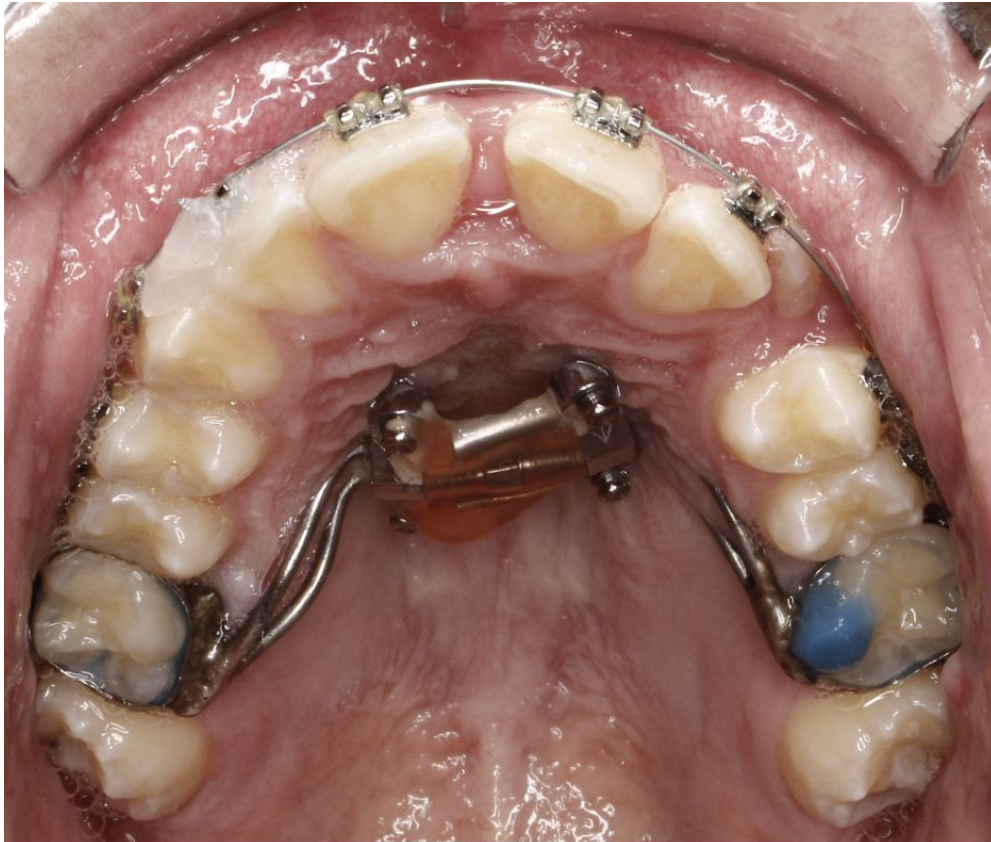- MSE area:
 - **2:** chart note reported pain on the palate near the expander or expander screws that was severe enough causing early removal of MSE
 - **1:** chart note reported transient pain on the palate near the expander or expander screws but expander did not have to be removed
 - **0:** No pain noted in chart
- Nose
 - **2:** chart note reported pain within the nose severe enough causing early removal of MSE
 - **1:** chart note reported transient pain within the nose but expander did not have to be removed
 - **0:** No pain noted in chart
- Headache
 - **2:** chart note reported headache pain causing early removal of MSE
 - **1:** chart note reported transient headache pain but expander did not have to be removed
 - **0:** No pain noted in chart
- Dentition
 - **2:** chart note reported pain in the one or more of the maxillary teeth causing early removal of MSE
 - **1:** chart note reported transient pain in the one or more of the maxillary teeth but expander did not have to be removed
 - **0:** No pain noted in chart
- Other
 - **2:** chart note reported pain in another area of the maxillary complex that was noted noted above, causing early removal of MSE
 - **1:** chart note reported pain in another area of the maxillary complex that was noted noted above, but expander did not have to be removed
 - **0:** No pain noted in chart

Inflammation

- **3:** Chart note reported expander was removed early due to inflammation
- **2:** Using progress photos, gum tissue covered MSE arms or screw
- **1:** Using progress photos, gum tissue was erythematous or hypertrophic but not covering MSE
- **0:** Using progress photos, no inflammation present



Rating 3: According to chart note, MSE had to be removed early due to inflammation or pain from inflammation



Illustrating appliance breakage-- guide rods have come loose from the expander

Loss of Vitality

- **1:** Chart noted miniscrew was in close proximity to root of incisor tooth causing irreversible pulpitis
- **0:** Chart note did not note the above scenario

Broken Screw

- **1:** Chart noted miniscrew broke upon placement or removal of MSE expander
- **0:** Chart note did not note the above scenario

Appliance Breakage/ Malfunction

- **1:** Chart noted MSE expander broke or malfunctioned preventing continuation or stability of expansion
- **0:** Chart note did not note the above scenario



Results

Expansion Data

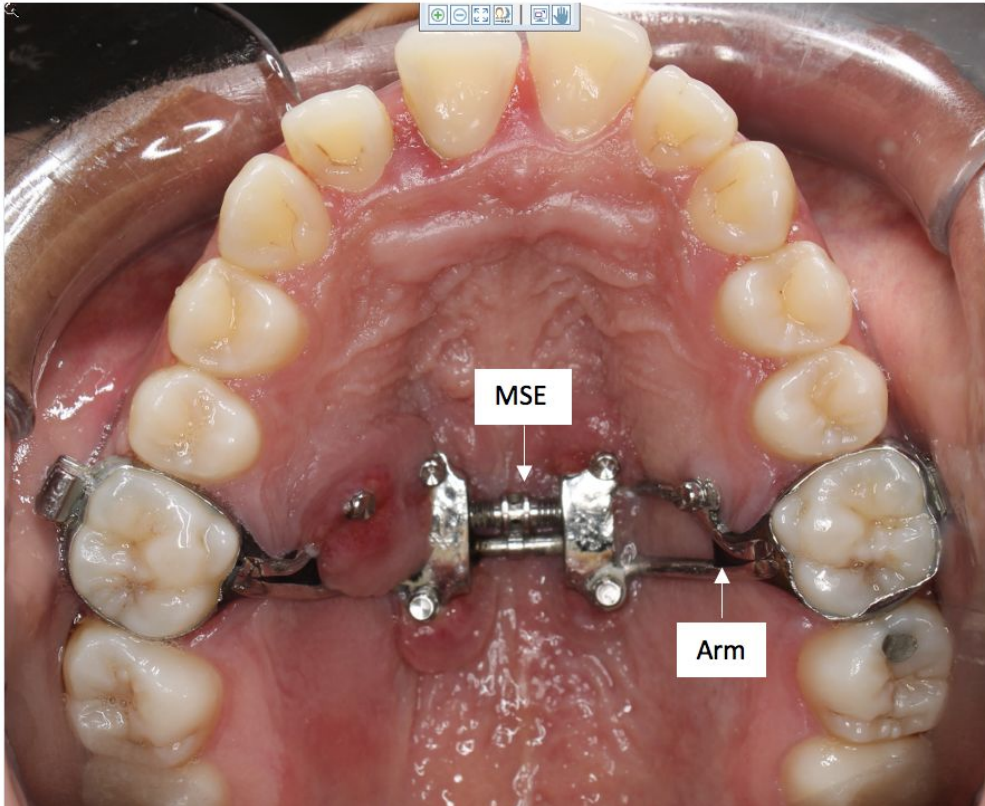
	Mean
Age at T1 (yrs)	16.07 ± 5.32
Age at T2 (yrs)	16.22 ± 4.51
Velocity of Expansion (mm/day)	0.23 ± .15
Total Expansion (mm)	7.24± 2.34

Summary of Complications

- 91% of patients exhibited diastema
- 31% of patients had inadequate expansion after 1st MSE
- Pain
 - 18% exhibited pain in the MSE area
 - 2% of patients exhibited transient pain in the nose, not requiring early MSE removal
 - 3% of patients exhibited transient headaches, not requiring early MSE removal
 - 4% exhibited transient pain in maxillary teeth, not requiring early MSE removal
- 1% exhibited loss of vitality
- 9% exhibited appliance breakage/ malfunction
- 1% exhibited broken screw

Diastema			
	1	88/97	90.72%
	0	9/97	9.28%
Inadequate Expansion			
1st Attempt	1	22/70	31.43%
	0	48/70	68.57%
2nd Attempt	1	5/13	38.46%
	0	8/13	61.54%
Pain-Location			
MARPE area (M)	2	3/97	3.09%
	1	15/97	15.46%
	0	79/97	81.44%
Nose (N)	2	0/97	0.00%
	1	2/97	2.06%
	0	95/97	97.94%
Headache (H)	2	0/97	0.00%
	1	3/97	3.09%
	0	94/97	96.91%
Dentition (D)	2	0/97	0.00%
	1	4/97	4.12%
	0	93/97	95.88%
Loss of Vitality			
	1	1/97	1.03%
	0	96/97	98.97%
Appliance Breakage/ Malfunction			
	1	9/97	9.28%
	0	88/97	90.72%
Broken Screw			
	1	1/97	1%
	0	96/97	98.97%

Inflammation complication



MSE Inflammation Rating over Tx	ARM	MSE	AVG
3	9.38%	3.61%	6.49%
2	17.82%	18.40%	18.11%
1	60.94%	53.73%	57.34%
Total			81.94%

81.94% of patients exhibited some type of inflammation over treatment.
6.5% of patients had MSE remove early due to inflammation.

Conclusion

- The most common complication was inflammation around the MSE site, followed by pain.