

DOI: 10.1111/1756-185X.14200

ABSTRACTInternational Journal of
Rheumatic Diseases

WILEY

POSTER PRESENTATIONS**Advances in Pain Management****Buffered dextrose 5% – an alternative analgesia**M. L. Swee¹, H. E. Liu¹, Y. Y. Jasmine Sze¹, H. N. Kooi¹, H. C. Siew¹,
S. Shantene¹, M. Nadiah¹, M. Asmah¹, C. G. Suk¹¹Hospital Tuanku Ja'afar Seremban, Seremban, Malaysia

Background/Purpose: Chronic pain around neck and upper limbs (NUL) among patients with rheumatic and musculoskeletal disease (RMD) is challenging to handle. Dr John Lyftogt has established the use of buffered dextrose 5% with pH of 7.4 (BD5%) in Perineural injection therapy (PIT) to treat such condition with success.

Our primary objective is to assess pain score reduction (PSR) in Numerical Rating scale (NRS) after PIT in this region. Secondary objective is to assess percentage of patients who achieved at least 50% PSR at the end of treatment.

Methods: Patients with NUL pain who received PIT in 2019 and had followed up for 12 months were reviewed. PIT was performed by serial injection of BD5% along the superficial nerve(s) underneath the skin using 30G, 1cm hypodermic needle. Patients with pain score not recorded or still undergoing PIT were excluded. PSR before and after series of treatments were analysed using paired T test.

Results: 21 patients with NUL pain were treated with total of 61 PIT. Mean age was 58.1. 76.2% (n = 16) were female. 57.1% (n = 12) had shoulder tendinopathy with or without tear, 33.3% (n = 7) had fibromyalgia while 9.5% (n = 2) had cervical spondylosis.

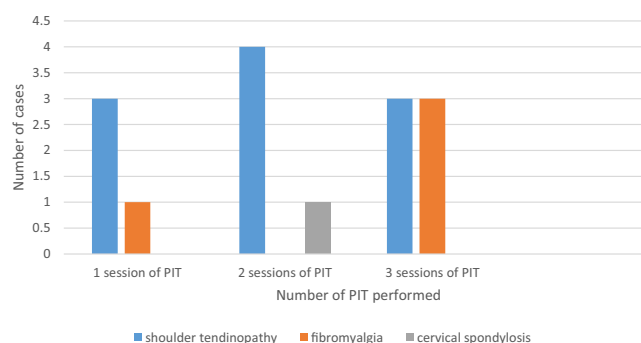
Baseline pain score was 7.0 ± 1.4 , duration of pain was 1.8 ± 1.6 years. Average 2.9 ± 1.5 times of PIT were performed. 19% (n = 4) had one PIT, 23% (n = 5) needed two while 29% (n = 6) needed three PIT. Distribution of cases according to number of PIT as shown in Figure 1.

Pain score reduced to 2.9 ± 1.7 , 2.1 ± 1.4 and subsequently 1.4 ± 1.1 following first, second and third PIT. On average, PSR was 6.0 ± 2.2 (p = 0.0001). The effect lasted for 5.7 ± 4.2 months. No complications were observed.

100% of them demonstrated 50% or more PSR.

Conclusion: Buffered dextrose 5% in perineural injection therapy alleviates NUL pain significantly. This is a good and safe alternative treatment for RMD patients with NUL pain.

Distribution of Cases

**FIGURE 1** Distribution of cases according to number of PIT needed**Buffered dextrose 5% - the sweet solution for chronic low back pain**M. L. Swee¹, S. Shantene¹, H. E. Liu¹, Y. Y. Jasmine Sze¹, H. N. Kooi¹,
H. C. Siew¹, M. Nadiah¹, M. Asmah¹, C. G. Suk¹¹Hospital Tuanku Ja'afar Seremban, Seremban, Malaysia

Background/Purpose: Chronic low back pain (CLBP) is one of the constant struggle among patients with rheumatic and musculoskeletal disease (RMD). Dr John Lyftogt had used buffered dextrose 5% with pH of 7.4 (BD5%) via caudal epidural injection (CEI) to treat CLBP successfully.

Our primary objective is to assess pain score reduction (PSR) in Numerical Rating scale (NRS) after CEI. Secondary objective is to assess percentage of patients who achieved at least 50% PSR at the end of treatment.

Methods: Patients with CLBP who received CEI in 2019 and had followed up for 12 months were reviewed. CEI was performed by giving 10 mL of BD5% at caudal epidural region via 26G, 1cm needle. Patients with pain score not recorded or still undergoing CEI were excluded. PSR before and after series of treatments were analysed using paired T test.

Results: 35 patients received total of 127 CEI for CLBP. Mean age was 62.1 years and 80% (n = 28) were females. 80% (n = 28) had mechanical low back pain due to spondylosis, prolapsed intervertebral disc, spinal stenosis and spondylolisthesis. 14.3% (n = 5) had



Lupus nephritis presenting as a renal hematoma in a Filipino female patient: a case report

R. Ramirez¹

¹Valenzuela Medical Center, Valenzuela City, Philippines

Lupus nephritis is an inflammation of the kidneys caused by systemic lupus erythematosus (SLE). It is the most frequent complication of SLE. There is a wide spectrum of clinical manifestations of lupus nephritis however; renal hematoma is a rare presentation. The author presents a Filipino female patient admitted for flank pain and was subsequently diagnosed with Lupus Nephritis.

Case Presentation: This is a case of a 32-year old Filipino woman, who had presented with a recurrent, progressive flank pain associated with intermittent pedal edema, fatigue, macular rash, and fever. Computed tomography of the abdomen revealed diffuse subacute capsular hematoma of the right kidney. Subsequent diagnostic exams revealed anemia, leucopenia, elevated creatinine, hematuria, low C3, elevated ANA, Anti-dsDNA and Anti-Smith. She was managed as a case of Lupus Nephritis, and was given Methylprednisone pulse 1 gram for 3 days and Cyclophosphamide 750mg IV infusion thereafter. Patient improved with resolution of renal hematoma and pedal edema. She was maintained on Prednisone and IV Cyclophosphamide.

Conclusion: Our experience demonstrates that Lupus Nephritis may present atypically. It exhibits unusual spectrum that may progressed to severe clinical manifestations. Steroids and IV Cyclophosphamide bring on remission of even severe Lupus Nephritis.

Acute pancreatitis as an initial presentation of SLE: a case report

B. Sachdev Manjit Singh¹, C. Teh¹, S. Chuah¹, Y. Cheong¹, S. Wan¹, A. Jobli²

¹Rheumatology Unit, Department Of Medicine, Sarawak General Hospital, Kuching, Malaysia; ²Radiology Department, Faculty of Medicine and Health Science, University Malaysia Sarawak, Kuching, Malaysia

Background: SLE is a complex multi-systemic autoimmune disease capable of affecting any organ system with varying presentations. Abdominal pain is a common manifestation of SLE and is reported to occur in about 8% to 40% of patients with SLE. The causes of abdominal pain are varied and require accurate assessment. Acute Pancreatitis is a cause of abdominal pain and is a rare initial SLE presentation. It is characterized by abdominal pain and raised serum amylase levels. We would like to report a patient diagnosed with SLE following an initial presentation of Acute Pancreatitis, which was complicated with a pancreatic pseudocyst.

Case Report: The patient is an 18-year-old lady with no previous known medical illness who presented with a one day history of acute central abdominal pain radiating to the back. This was preceded by a

two week history of fever and non-productive cough. Further history revealed that she had alopecia, malar rash and painless oral ulcers one year before this presentation but did not seek medical attention. Physical examination revealed a tender and distended abdomen. Blood investigations showed leukopenia, elevated amylase with a positive Anti-nuclear antibody, and coombs test. She was admitted to the ICU and treated with intravenous cyclophosphamide, methylprednisolone, immunoglobulin, and antibiotics. During her follow-up a month after discharge, she was found to have recurrent abdominal pain and distension. A repeated CT Abdomen showed a pancreatic pseudocyst, and she underwent an endoscopic cystogastrostomy. Currently, she is on regular follow-up and is currently maintained on Hydroxychloroquine, Azathioprine, and Prednisolone.

Conclusion: In summary, Acute Pancreatitis is a relatively rare initial manifestation of SLE. The causes of Acute Pancreatitis are varied, and it is essential to recognize and differentiate Acute Pancreatitis due to active SLE from other causes as it may affect treatment decisions and subsequent mortality outcomes.

Catastrophic antiphospholipid syndrome precipitated by acute leukaemia: a case report

B. Sachdev Manjit Singh¹, W. Lee¹, K. Lee¹, Y. Cheong¹, S. Wan¹, C. Teh¹

¹Sarawak General Hospital, Kuching, Malaysia

Background: Catastrophic Antiphospholipid Syndrome (CAPS) rarely occurs in patients with Antiphospholipid Syndrome (APLS). It is an accelerated and devastating form of APLS characterized by multiple thromboses affecting mainly small vessels resulting in multi-organ failure. It has a high mortality rate despite aggressive treatment. Precipitating factors for CAPS include infections, surgery, and malignancy. We herein report a patient with SLE and secondary APLS diagnosed with CAPS precipitated by acute leukemia.

Case Report: The patient is a 63-year-old lady with a history of hypertension, dyslipidemia, and SLE with secondary APLS. She presented with acute right lower limb pain associated with coldness and numbness. Examination revealed a cold, pale right lower limb with reduced sensation and non-palpable pulses over the right femoral, popliteal, dorsalis pedis, and posterior tibialis. CT Angiogram of the bilateral lower limbs revealed a long segment thrombosis in the mid and distal right Superficial Femoral Artery. A diagnosis of Acute Right lower limb Ischemia was made. She was treated with intravenous heparin and underwent a right lower limb femoral embolectomy. Postoperative, the right lower limb pulses were palpable but became absent again on day two. A repeated CT Aorta revealed a short segment mural thrombus at the infrarenal abdominal aorta with minimal mural thrombus at the bilateral common iliac and common femoral arteries.

The vascular team proceeded with a bilateral femoral embolectomy for worsening symptoms but was complicated with hypotension requiring inotropic support and ICU admission. Methylprednisolone