

*Original Scientific Article***MORPHOLOGICAL PECULIARITIES OF PARASITIC (*TRICHOSOMOIDES CRASSICAUDA*) INFECTION IN RAT URINARY BLADDER**

Vladyslav Sikora, Mykola Lyndin, Natalia Hyriavenko, Roman Moskalenko, Yulia Lyndina, Kateryna Sikora, Ruslana Chyzhma, Olena Diachenko, Anatolii Romaniuk

Department of Pathology, Sumy State University, Privokzalna 31, Sumy 40022, Ukraine

Received 3 February 2021; Received in revised form 2 April 2021; Accepted 26 April 2021

ABSTRACT

Trichosomoides crassicauda (*T. crassicauda*) is a parasite commonly localized in the urinary bladder (UB) of laboratory and wild rats. The presence of these helminths can influence the prediction of pathological changes in the UB. Therefore, the purpose of this research was to make a comprehensive study of the features of the morphological changes in the UB wall of white laboratory rats as a result of *T. crassicauda* infestation. The study was performed on male rats using histological (Hematoxyline-Eosin and Alcian Blue staining) and immunohistochemical (Ki-67, Hsp70, Hsp90 α , CD3 and CD20) methods. *T. crassicauda* was detected in both urine and UB samples. Morphological changes were observed as disruption in urothelial cell stratification and insignificant proliferative and immune responses in the UB. Increased heat shock protein levels were observed which may suggest a natural body's resistance to this parasite.

Key words: nematode, parasite, rat, *Trichosomoides crassicauda*, urinary bladder

INTRODUCTION

Due to the unique morphological, anatomical, and physiological features of the urinary bladder (UB), it is used for bio-modeling of various pathological processes (1, 2, 3, 4, 5). The experimental studies on the UB of the laboratory animals help to understand the pathogenesis of various diseases which can be used for extrapolation of the results to human medicine (1, 2, 3, 6, 7, 8). The disruption of the mucous membrane integrity often correlates to the development of various pathologies and urination disorders (1, 2, 4, 7, 8, 9, 10). The urothelium surface is normally resilient to the biochemical components of the urine, microorganisms, and toxins. The local protection of the mucosal cells includes the tight junctions of umbrella cells (physical barrier) (5, 9), glycosaminoglycans (9, 11), cytokeratin (12),

uroplakins (Upk1a, Upk1b, Upk2, Upk3a and Upk3b), and numerous membrane receptors (9, 13).

Few nematode species can parasitize in animals' UB (14, 15). Depending on the development stage, they can migrate to nearly all organs and systems with or without clinical manifestations (15). They may affect the tissue structure and normal physiological processes disrupting the micturition.

Trichosomoides crassicauda (*T. crassicauda*) is a nematode commonly localized in the UB of laboratory and wild rats (14, 15, 16, 17). It was also detected in the kidneys, uterus, and lungs (17, 18). The nematode eggs are released in the urine (the eggs remain viable for a long time at room temperature) and enter another host's digestive system by contaminated food (water and food products). They are hatched in the stomach and reach the kidneys and UB by blood circulation. The helminths are accumulating in the urine and UB cavity where they lay the eggs in the mucosal tissue at a very early stage of their development. The eggs continue to develop repeating the same cycle of events. The prepatent period including the time between infection and the production of eggs is 8-10 weeks (15, 16, 17, 18). They can also be transmitted from the mother to the offspring before weaning (16). It is important to note that the biological behavior and pairing of the heterogeneous *T. crassicauda* are

Corresponding author: Dr. Vladyslav Sikora, PhD
E-mail address: v.sikora@med.sumdu.edu.ua
Present address: Department of Pathology, Sumy State University, Privokzalna 31, Sumy 40022, Ukraine
Phone: +380507276193

Copyright: © 2021 Sikora V. This is an open-access article published under the terms of the Creative Commons Attribution License which permits unrestricted use, distribution, and reproduction in any medium, provided the original author and source are credited.

Competing Interests: The authors have declared that no competing interests exist.

Available Online First: 2 July 2021

<https://doi.org/10.2478/macvetrev-2021-0019>

unique due to the different body sizes in males and females. Female nematodes are larger than males which is significant for the evolution of sexual selection. The smaller male nematode penetrates to the genital tract of the larger female nematodes fertilizing the eggs. Females are more frequently localized in the UB, while the males in the uterus (15, 17, 18, 19).

The absence of these nematodes in the urine does not exclude their presence in UB. Therefore, for positive determination of this parasite, it is suggested that both urine and UB tissue must be checked (15). The mechanisms of *T. crassicauda* parasitism have not been studied sufficiently. A positive correlation was described between pathomorphological changes in UB and uterus (inflammation and tumors) (15, 17, 18, 20). This confirms that the presence of *T. crassicauda* may negatively impact on the results of a modeling study. Therefore, this research aims to comprehensively study the features of the morphological changes in the UB wall of white laboratory rats due to the presence of *T. crassicauda*.

MATERIAL AND METHODS

Animals and experimental design

In this bio-modeling study, 60 male albino laboratory rats (214.62±12.40 g) were acquired from the Medical Institute of Sumy State University, Animal House. Animals were allowed to acclimatize for one week before the experiment had been commenced. During the study, the rodents were housed in polypropylene cages. They were kept in a room under a controlled constant temperature of 24 °C±1 °C, relative humidity of 55%±5%, 12 hours light/dark cycle, free access to tap water, and standard laboratory animal food. Urine samples were collected in three consecutive days of the experiment, at the same time (from 10 am to 1 pm). They were microscopically analyzed for the presence of the parasite (magnification ×100). According to the findings, the rodents were divided into two groups – presence (group 1 - infected group) and absence of *T. crassicauda* (group 2 - control group).

They were anesthetized and euthanized by cervical dislocation. The UB was identified and excised by a midline abdominal incision. Animal handling was performed with consideration to minimize stress to the experimental animals. All experiments were performed according to the guidelines established by the European Community for the Care and Use of Laboratory Animals, Ethics

and Animal Welfare Committee of the International Council for Laboratory Animal Science and according to local Ethics guidelines, and were approved by the Institute Bioethics Commission (experimental protocol № 25/04 from 10.04.2018).

Tissue preparation, morphometric scoring, histopathologic and immunohistochemical examination

After excising UB tissue from the animals, samples were immediately fixed in 10% formalin solution for 24 h, dehydrated (in ascending grades of ethanol 70–96%), cleared in xylene, and embedded in paraffin (4% wax). Thereafter, each block was cut into 4 µm thick sections on rotational microtome Shandon Finesse 325 (Thermo Scientific, USA), placed on aminopropyltriethoxysilane-coated slide glasses (Thermo Scientific, USA), deparaffinized, and rehydrated (xylene and descending graded ethanol 96–70%) by routine methods. Tissue samples were stained with Hematoxylin-Eosin and Alcian Blue techniques and mounted by Canada balsam (Thermo Scientific, USA) according to the standard method (21). Urine specimens were diluted with 10% formalin and examined under a microscope on slide glasses. Helminth species and eggs were confirmed by shape, size, membrane thickness and color (19).

Other samples were stained immunohistochemically. Antigen retrieval was carried out in a water bath at 97-98 °C containing boiled citrate antigen retrieval buffer, pH 6.0 (Thermo Fisher Scientific, USA) for 30 min. The cooled slides were washed in distilled water and placed in Tris-buffered saline (Thermo Fisher Scientific, USA) pH 7.4 for 20 min. The antigen-antibody reaction was visualized using the Ultra Vision Quanto Detection System HRP DAB Chromogen (Thermo Fisher Scientific, USA), which included blocking endogenous peroxidase activity by 3% H₂O₂, protein blocker using the Ultra V block and enhancing the reaction by Primary Antibody Amplifier Quant. Primary antibodies in different dilutions were used for determining the expression of receptors to Ki-67, Hsp70, Hsp90α, CD3 and CD20. Immunohistochemical analysis was visualized using the polymer detection system with diaminobenzidine chromogen, and additional nuclei counterstaining with Modified Mayer's Hematoxylin (Thermo Fisher Scientific, USA), dehydrated, cleared and mounted. All morphological examinations and morphometric scoring of parasites and their eggs were performed using «Carl Zeiss Primo Star» microscope with a digital camera «Zeiss AxioCam ERc 5s» and the

software package for the image output «ZEN 2 (blue edition)» (Germany) with a built-in micrometer and calculation output.

Statistical analysis

The results were presented as Mean ± SD or as a percentage of variation compared to the control.

RESULTS

The urine analysis revealed the presence of *T. crassicauda* eggs in 17 (28.33%) rats (group 1) with significant variation in the number in each specimen. Group 2 included rats without nematode infection in urine – 43 (71.67%). Morphological analysis of UB confirmed changes in both groups: animals in group 1 (17 rats – 100%) and group 2 (8 rats – 18.6%). The overall rate of infection was 41.67 % (from the total number of animals - 60 rats).

Helminths and their eggs were localized in the UB cavity (in the lumen and between mucous

rugae) and/or embedded in the epithelium. *T. crassicauda* had an elongated body with rounded ends, mature and/or immature eggs. Morphometric characteristics of the females of *T. crassicauda* significantly varied and in average were 612.28±153.71 µm in length and 94.13±19.71 µm in width. The male specimens outside the female body were found only twice in the lumen of the UB (first one – 47.15 µm in length and 8.20 µm in diameter, the second one – 38.26 µm in length and 7.90 µm in width).

On histological examination, we found a discrete swelling in the UB, disturbed stratification of the urothelium, and localized hyperplasia. The helminths and eggs were encapsulated by transitional epithelial cells. The adjacent cells had dystrophic and necrotic changes. Desquamations caused localized increased permeability of the mucosal layer. The helminths were localized on the top or between the rugae without inflammatory reaction in lamina propria and submucosa. Despite the direct contact of the nematode eggs with lamina propria, single immune cells were observed only in several rats (Fig. 1).

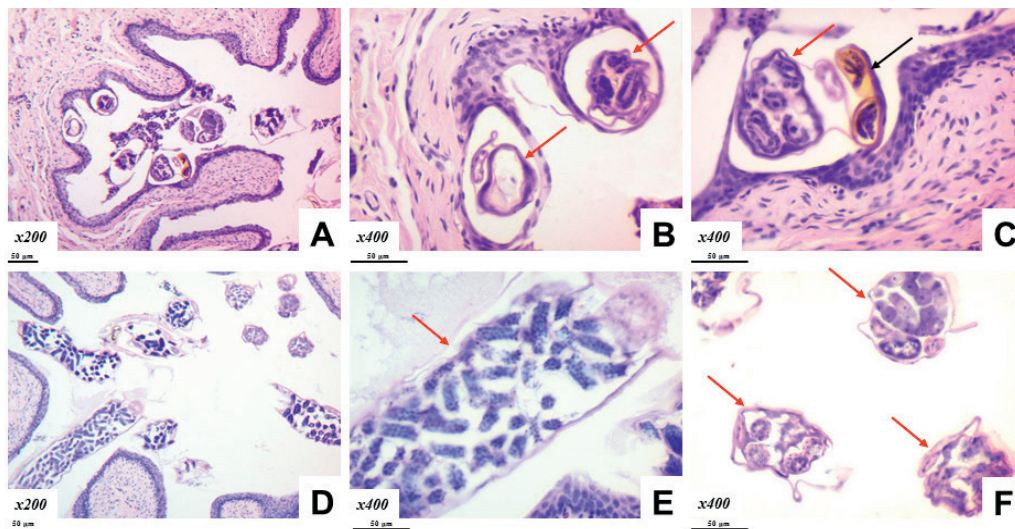


Figure 1. *Trichosomoides crassicauda* (red arrow) and eggs (black arrow) in the rat UB. Hematoxyline and Eosin staining. Magnification: A, D×200; B, C, E, F×400. Scale bar=50 µm

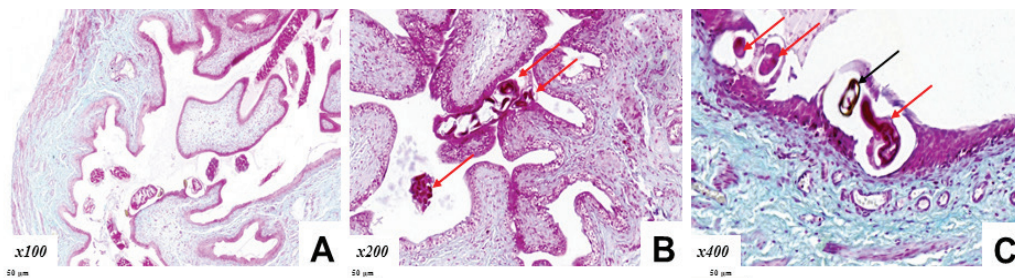


Figure 2. *Trichosomoides crassicauda* (red arrow) and eggs (black arrow) in the rat UB. Alcian Blue staining. Magnification: A×100; B×200; C×400. Scale bar=50 µm

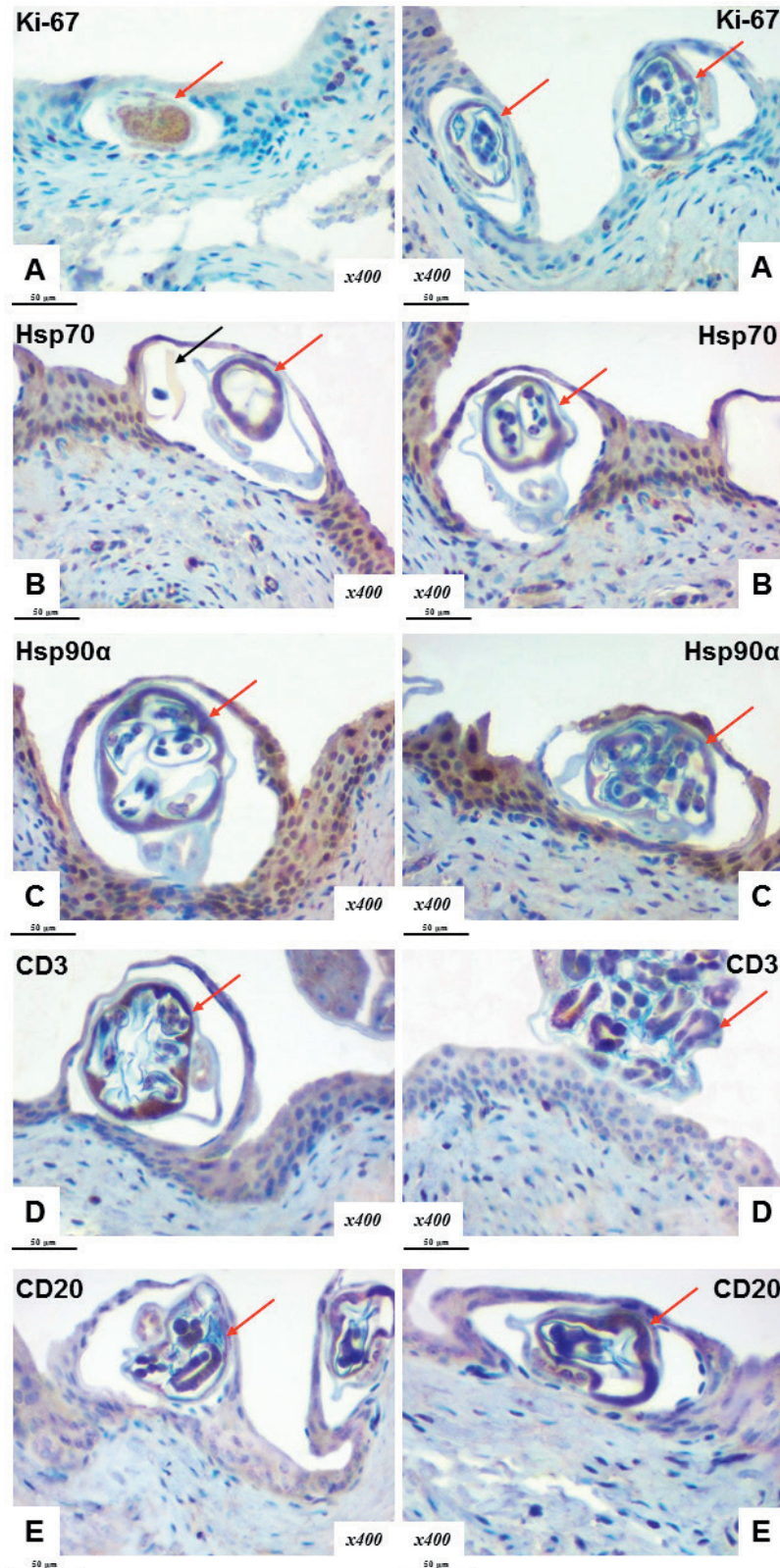


Figure 3. Intraepithelial localization of *Trichosomoides crassicauda* (red arrow) and eggs (black arrow) in the rat UB. Immunohistochemical examination of Ki-67 (A), Hsp70 (B), Hsp90α (C), CD3 (D) and CD20 (E) expression. Chromogen – diaminobenzidine. Nuclei were counterstained with Mayer’s hematoxylin. Magnification: ×400. Scale bar=50 μm

Despite the varying female size, the eggs did not have significant variations ($59.14 \pm 6.69 \mu\text{m}$ in length and $37.76 \pm 7.89 \mu\text{m}$ in width) which were influenced mainly on the development stage of the female and its eggs. *T. crassicauda*'s eggs had a well-defined brown oval capsule ($3.26 \pm 0.71 \mu\text{m}$ thick) the embryos being tightly situated in its cavities. Nematodes and their eggs penetrated different layers of the urothelium, mostly reaching the basement membrane of UB by passing through the umbrella, intermediate, and basal cells where they formed chamber-like capsule around them. Although they were embedded in the transitional epithelium, a small space was visible around their shell. The chamber-like capsule encompassed single or multiple parasites in its cavity.

The glycosaminoglycans layer of the urothelium was not entirely eroded despite the disrupted stratification of the cells. The affected layers included the epithelium and the surrounding encapsulated parasite areas (Fig. 2 A, B, C).

A low proliferative index of the transitional epithelium was observed throughout the mucous membrane. Ki-67 positive expression was found in single cells of the basal and partly intermediate layers of the transitional epithelium. Ki-67 was mainly not expressed by cells in the affected and surrounding areas or its expression was sporadic in few cells (Fig. 3 A). Increased proliferative activity was found near the desquamation lesions of the epithelium.

The surrounding epithelial tissue showed an increase of the chaperones' activity around the parasite localization. Expressed induction of Hsp70 and Hsp90 α was observed in basal, intermediate and umbrella cells (Fig. 3 B, C).

An immunohistochemical study confirmed the absence of inflammatory infiltration. CD3 (T-lymphocytes) and CD20 (B-lymphocytes) were detected in small and solitary formations around the helminths and eggs in the UB mucous membrane (Fig. 3 D, E).

DISCUSSION

Rats are frequently used as experimental animals for pathological and/or biomodelling studies which are essential for improving theoretical understanding (22). It is generally believed that numerous threats with unclear pathogenesis can affect UB functioning and lead to urodynamic disorders (2, 3, 5, 9, 13). The causes of tissue transformation under the influence of exo- and endogenous factors are a topic of continuous investigations (3, 9, 23).

Parasites are considered as one of the most frequently observed macroscopic pathological agents (19, 24, 25). In our study, we investigated the influence of *T. crassicauda* on UB. The presence of these nematodes in the UB is correlated with the development of cystitis, bladder stones, metaplasia, and oncological processes (14, 17, 18, 19, 20). Moreover, they were revealed both in wild and laboratory rats despite the significant habitual differences. However, its' effects on UB are not sufficiently elucidated and is still an ongoing topic in current research (15, 16, 17, 18, 20, 26).

In urine samples, *T. crassicauda* was detected in 28.33%. However, by adding the findings of the morphological identification in UB samples, this value was increased by 18.60%. This indicates that urine analysis alone cannot be used for the detection of the presence of this parasite in the UB (15, 16). It should be noted that despite the experimental conditions which allowed close contact between the animals, the possibility for cross-infection was significantly low. In natural and experimental conditions, the infestation level has a certain value in the population despite the high zoonotic potentials of these parasites. Based on the results obtained by Mustapha Tijjani et al. (27), intestinal or tissue parasites were found in 17.1% and 15.4% of wild rodents, respectively. Some of the rodents were infected with various species of parasites.

It is considered that mature males and females differ in susceptibility to infections caused by bacteria, fungi, parasites, and viruses due to their innate physiological sex differences, genetic and behavioral features, endocrine-immune interactions, hormones profile, and their effects on gene expression. (28). All these gender differences may explain some variability in response to various infections. This might be explained due to the specific immune function affected by circulating steroid hormones (testosterone, estradiol, progesterone, and glucocorticoids) (29). Accordingly, men are more susceptible to parasitic infections due to the immunosuppressing role of testosterone (15, 28, 19, 30). Although the prevalence and intensity of infections are higher in males than in females, there are also parasites for which males are more resistant than females (28, 29).

This research has demonstrated the effects of direct contact interaction between the parasite and the UB epithelium. Changes in the transitional epithelium had a pronounced heterogeneity due to the increased susceptibility for secondary infections. This can be found in other reports where urothelium's responsiveness is described with

various degrees of inflammation (eosinophil and granulocyte infiltration) and hyperplasia resulting in variable outcome (15, 16, 17, 18, 20). We observed solitary inflammatory cells without parenchymal-stromal components in the UB.

The UB responsiveness to infectious/parasitic insults is mainly dependent on mucosal integrity (3, 9). The helminthiasis of UB is mainly characterized by disruption of the glycosaminoglycans layer with a consequent increased permeability. The parasite is usually localized beneath and between the mucosal cells of the UB. We observed that the alterations of the mucosal cells surrounding the encapsulated parasite can be partially restored with permanent deterioration of the superficial layer. It is presumed that the location of the parasite in the deeper mucosal layers may be to avoid direct contact with the urine at certain stages of their development. This results in recurrent urinary tract infections, interstitial cystitis, urolithiasis, and neoplastic changes (1, 3, 10, 11, 13, 20, 25).

The tissue inflammatory response (number and localization of immune cells) may indicate the outcome of the pathological process caused by various exo- and endogenous factors. (2, 3, 4, 9, 23, 31, 32, 33, 34, 35). During our study, only single T/B-lymphocytes were observed in the mucosa.

Prolonged contact of *T. crassicauda* with UB mucosa may cause inflammatory response with variable degrees of pathomorphological changes depending on other factors. The insignificant changes and relatively low immune response may be related to the high regenerative capabilities of the UB mucosa (36).

The presence of Ki-67 in few cells was not entirely elucidated. Ki-67 was detected in areas with epithelial lesions (desquamation areas), but it was almost undetectable in mucosal cells surrounding the encapsulated parasite. It is considered an essential element of regeneration (2, 20, 37). The deteriorated transitional epithelium structure and integrity were not accompanied by processes of proliferation which may be explained due to the lack (blocked) of cell receptors.

Heat shock proteins (Hsp70, Hsp90 α) act as protective components of the epithelium and are actively involved in their local defense (38). The cytoprotective properties of chaperones in the epithelium have been reported following a few hours or days after tissue insult (2, 39). The long-term impact of different factors on UB and chaperones' reactions remains unclear. Increased expression of Hsp70 and Hsp90 α in urothelium around helminths probably appeared as a response to cellular stress.

It is a compensatory reaction of normal cells to recover proteins' conformation, preventing caspases activation and apoptosis. Similar data on the full range of their protective properties are described in other reports (2, 38, 39, 40).

In summary, from the UB lumen, the parasite is breaching the glycosaminoglycans layer penetrating the epithelial physical barrier and continues its development in the mucosal layers. The variable pathomorphological and pathophysiological changes in the UB mucosa may lead to uncertain predictions of the parasite's pathological patterns. Additional research would elucidate these mechanisms.

CONCLUSION

The nematodes *Trichosomoides crassicauda* and their eggs are frequently found in the urinary bladder of laboratory rats. Their absence in urine does not exclude the helminthiasis in the urinary bladder. The co-existence of rats (healthy and infected with parasites) does not necessarily lead to cross-infection to all members of the population.

The nematodes disrupt the stratified structure of the urothelial cells bypassing the glycosaminoglycans' protective layer and encapsulating in the mucosal layers. This process is accompanied by a small-scale inflammatory reactions and other pathological changes. The lack of increased proliferative activity and increased chaperone expression may indicate to natural defense for this parasite.

CONFLICT OF INTEREST

The authors declare that they have no potential conflict of interest with respect to the authorship and/or publication of this article.

ACKNOWLEDGMENT

This research was supported by the research themes № 0119U100887 and № 0121U100472.

AUTHORS' CONTRIBUTION

ML and VS were involved in literature review, design, preparing the manuscript and figures. AR, RM, ML and VS were responsible for final approval of the article, analysis and data interpretation. NH, YL, KS,

RC and OD conducted the experimental part, data acquisition, statistical analysis, participated in writing, editing and discussion.

REFERENCES

1. Akiyama, Y., Homma, Y., Maeda, D. (2019). Pathology and terminology of interstitial cystitis/bladder pain syndrome: A review. *Histol Histopathol.* 34(1): 25-32.
2. Romaniuk, A., Sikora, V., Lyndin, M., Smiyanov, V., Sikora, V., Lyndina, Yu., Piddubnyi, et al. (2017). The features of morphological changes in the urinary bladder under combined effect of heavy metal salts. *Interv Med Appl Sci.* 9(2): 105-111. <https://doi.org/10.1556/1646.9.2017.09> PMID:28932505
3. Girard, B.M., Tooke, K., Vizzard, M.A. (2017). PACAP/Receptor system in urinary bladder dysfunction and pelvic pain following urinary bladder inflammation or stress. *Front Syst Neurosci.* 11, 90. <https://doi.org/10.3389/fnsys.2017.00090> PMID:29255407 PMCid:PMC5722809
4. De Groat, W.C., Yoshimura, N. (2015). Anatomy and physiology of the lower urinary tract. *Handb Clin Neurol.* 130, 61-108. <https://doi.org/10.1016/B978-0-444-63247-0.00005-5> PMID:26003239
5. Fry, C.H., Vahabi, B. (2016). The role of the mucosa in normal and abnormal bladder function. *Basic Clin Pharmacol Toxicol.* 119(S3): 57-62. <https://doi.org/10.1111/bcpt.12626> PMID:27228303 PMCid:PMC5555362
6. Cunha, G., Overland, M., Li, Y., Cao, M., Shen, J., Sinclair, A., Baskin, L. (2016). Methods for studying human organogenesis. *Differentiation* 91(4-5): 10-14. <https://doi.org/10.1016/j.diff.2015.10.005> PMID:26585195 PMCid:PMC4866906
7. Choudhary, M., Asselt, E., Mastrigt, R., Clavica, F. (2015). Neurophysiological modeling of bladder afferent activity in the rat overactive bladder model. *J Physiol Sci.* 65(4): 329-338. <https://doi.org/10.1007/s12576-015-0370-y> PMID:25782438 PMCid:PMC4477068
8. Wu, L., Zhang, X., Xiao, N., Huang, Y., Kavran, M., Elrashidy, R.A., Wang, M., et al. (2016). Functional and morphological alterations of the urinary bladder in type 2 diabetic FVB(db/db) mice. *J Diabetes Complications.* 30(5): 778-785. <https://doi.org/10.1016/j.jdiacomp.2016.03.003> PMID:27037041 PMCid:PMC4912852
9. Merrill, L., Gonzalez, E.J., Girard, B.M., Vizzard, M.A. (2016). Receptors, channels, and signalling in the urothelial sensory system in the bladder. *Nat Rev Urol.* 13(4): 193-204. <https://doi.org/10.1038/nrurol.2016.13> PMID:26926246 PMCid:PMC5257280
10. Andersson, K.E., McCloskey, K.D. (2014). Lamina propria: the functional center of the bladder? *NeuroUrol Urodyn.* 33(1): 9-16. <https://doi.org/10.1002/nau.22465> PMID:23847015
11. Sobolev, V.E., Jenkins, R.O., Goncharov, N.V. (2017). Sulfated glycosaminoglycans in bladder tissue and urine of rats after acute exposure to paraoxon and cyclophosphamide. *Exp Toxicol Pathol.* 69(6): 339-347. <https://doi.org/10.1016/j.etp.2017.02.007> PMID:28259532
12. Veranic, P., Jezernik, K. (2006). The cytokeratins of urinary bladder epithelial cells. *Asian J Cell Biol.* 1(1): 1-8. <https://doi.org/10.3923/ajcb.2006.1.8>
13. Matuszewski, M.A., Tupikowski, K., Dołowy, L., Szymańska, B., Dembowski, J., Zdrojowy, R. (2016). Uroplakins and their potential applications in urology. *Cent European J Urol.* 69(3): 252-257.
14. Rothenburger, J.L., Himsworth, C.G., La Perle, K.M.D., Leighton, F.A., Nemeth, N.M., Treuting, P.M., Jardine, C.M. (2019). Pathology of wild Norway rats in Vancouver, Canada. *J Vet Diagn Invest.* 31(2): 184-199. <https://doi.org/10.1177/1040638719833436> PMID:30852980 PMCid:PMC6838826
15. Najafi, F., Ghadikolai, M., Naddaf, S., Hasanpour, H., Mobedi, I., Mowlavi, G. (2017). *Trichosomoides crassicauda* infection in laboratory rats with histopathological description in the bladder tissue. *JoMMID.* 5(1-2): 31-34. <https://doi.org/10.29252/JoMMID.5.1.2.31>
16. Bahrami, S., Rezaei, A., Alborzi, A.R. (2014). *Trichosomoides crassicauda* infection in wistar rats. *Arch. Razi Inst.* 69(1): 63-67.
17. Ozkorkmaz, E.G. (2011). Microscopic investigations in a diabetic rat urinary bladder infected with *Trichosomoides crassicauda*. *J Electron Microsc (Tokyo).* 60(4): 261-265. <https://doi.org/10.1093/jmicro/dfr012> PMID:21454343
18. Al-Humaid, F., Mahmoud, O.M., Haroun, E.M., Magzoub, M., Al-Qarawi, A.A., Omer, O.H., Sulman, A. (1999). *Trichosomoides crassicauda* infection in Wistar rats. *J King Saud Univ.* 2(2): 105-111.

19. Flynn, R.J. (1973). Parasites of laboratory animals. 1st ed. Iowa State University Press: Ames
20. Serakides, R., Ribeiro, A.F.C., Silva, C.M., Santos, R.L., Nunes, V.A., Nascimento, E.F. (2001). Proliferative and inflammatory changes in the urinary bladder of female rats naturally infected with *Trichosomoides crassicauda*: reports of 48 cases. *Arq Bras Med Vet Zootec.* 53(2): 198-202.
<https://doi.org/10.1590/S0102-09352001000200012>
21. Suvarna, K., Layton, C., Bancroft, J. (2018). Bancroft's theory and practice of histological techniques. 8th ed. New York: Elsevier
22. Romaniuk, A., Lyndina, Yu., Sikora, V., Lyndin, M., Karpenko, L., Gladchenko, O., Masalitin, I. (2016). Structural features of bone marrow. *Interv Med Appl Sci.* 8(3): 121-126.
<https://doi.org/10.1556/1646.8.2016.3.3>
PMid:28203394 PMCID:PMC5283759
23. Lytvynenko, M., Bocharova, T., Zhelezniakova, N., Narbutova, T., Gargin, V. (2017). Cervical transformation in alcohol abuse patients. *Georgian Med News.* 271, 12-17.
24. Iliiev, P.T., Georgiev, G.Z., Kirkova, Z.T., Chakarova, B.G. (2017). A survey of helminth infections in the black rat from Stara Zagora District, Bulgaria. *Mac Vet Rev.* 40(2): 177-182.
<https://doi.org/10.1515/macvetrev-2017-0021>
25. Ishida, K., Hsieh, M.H. (2018). Understanding urogenital schistosomiasis-related bladder cancer: An update. *Front Med (Lausanne).* 5, 223.
<https://doi.org/10.3389/fmed.2018.00223>
PMid:30159314 PMCID:PMC6104441
26. Yokogawa, S. (1920). On the migratory course of *Trichosomoides crassicauda* (Bellingham) in the body of the final host. *J Parasitol.* 7(2): 80-84.
<https://doi.org/10.2307/3270959>
27. Tijjani, M., Majid, R.A., Abdullahi, S.A., Unyah, N.Z. (2020). Detection of rodent-borne parasitic pathogens of wild rats in Serdang, Selangor, Malaysia: A potential threat to human health. *Int J Parasitol Parasites Wildl.* 11, 174-182.
<https://doi.org/10.1016/j.ijppaw.2020.01.008>
PMid:32099788 PMCID:PMC7031134
28. McClelland, E.E., Smith, J.M. (2011). Gender specific differences in the immune response to infection. *Arch Immunol Ther Exp (Warsz).* 59(3): 203-213.
<https://doi.org/10.1007/s00005-011-0124-3>
PMid:21442309
29. Klein, S.L. (2004). Hormonal and immunological mechanisms mediating sex differences in parasite infection. *Parasite Immunol.* 26(6-7): 247-264.
<https://doi.org/10.1111/j.0141-9838.2004.00710.x>
PMid:15541029
30. Bone, J.F., Harr, J.R. (1967). *Trichosomoides crassicauda* infection in laboratory rats. *Lab Anim Care.* 17(3): 321-326.
31. O'Brien, V.P., Hannan, T.J., Schaeffer, A.J., Hultgren, S.J. (2015). Are you experienced? Understanding bladder innate immunity in the context of recurrent urinary tract infection. *Curr Opin Infect Dis.* 28(1): 97-105.
<https://doi.org/10.1097/QCO.0000000000000130>
PMid:25517222 PMCID:PMC4365976
32. Gonzalez, E.J., Arms, L., Vizzard, M.A. (2014). The role(s) of cytokines/chemokines in urinary bladder inflammation and dysfunction. *Biomed Res Int.* 2014, 120525.
<https://doi.org/10.1155/2014/120525>
PMid:24738044 PMCID:PMC3971501
33. Romaniuk, A., Lyndin, M., Sikora, V., Lyndina, Y., Panasovska, K. (2015). Histological and immunohistochemical features of medullary breast cancer. *Folia Med Cracov.* 55(2): 41-48.
34. Sui, X., Lei, L., Chen, L., Xie, T., Li, X. (2017). Inflammatory microenvironment in the initiation and progression of bladder cancer. *Oncotarget* 8(54): 93279-93294.
<https://doi.org/10.18632/oncotarget.21565>
PMid:29190997 PMCID:PMC5696263
35. Kozko, V.M., Bondarenko, A.V., Gavrylov, A.V., Shevchenko, O.S., Gargin, V.V. (2017). Pathomorphological peculiarities of tuberculous meningoencephalitis associated with HIV infection. *Interv Med Appl Sci.* 9(3): 144-149.
<https://doi.org/10.1556/1646.9.2017.31>
PMid:29201438 PMCID:PMC5700704
36. Romaniuk, A., Sikora, V., Lyndina, Yu., Lyndin, M., Hyriavenko, N., Sikora, V., Karpenko, L., et al. (2019). Effect of heavy metals on the readaptive processes in the urinary bladder. *BJMS.* 18(1): 100-106.
<https://doi.org/10.3329/bjms.v18i1.39558>
37. Radović, S., Vukobrat-Bijedić, Z., Selak, I., Babić, M. (2006). Expression of p53, bcl-2, and Ki-67 proteins in the inflammatory regenerative and dysplastic epithelial lesions of flat colonic mucosa. *Bosn J Basic Med Sci.* 6(1): 39-45.
<https://doi.org/10.17305/bjms.2006.3208>
PMid:16533178
38. Tiwari, S., Thakur, R., Shankar, J. (2015). Role of heat-shock proteins in cellular function and in the biology of fungi. *Biotechnol Res Int.* 2015, 132635.
<https://doi.org/10.1155/2015/132635>
PMid:26881084 PMCID:PMC4736001

39. Ikwegbue, P.C., Masamba, P., Oyinloye, B.E., Kappo, A.P. (2017). Roles of heat shock proteins in apoptosis, oxidative stress, human inflammatory diseases, and cancer. *Pharmaceuticals (Basel)*. 11(1): 2.
<https://doi.org/10.3390/ph11010002>
PMid:29295496 PMCID:PMC5874698
40. Jarzab, M., Kowal, M., Bal, W., Oczko-Wojciechowska, M., Rembak-Szynkiewicz, J., Kowalska, M., Stobiecka, E., et al. (2016). Ratio of proliferation markers and HSP90 gene expression as a predictor of pathological complete response in breast cancer neoadjuvant chemotherapy. *Folia Histochem Cytobiol.* 54(4): 202-209.
<https://doi.org/10.5603/FHC.a2016.0026>
PMid:28051275

Please cite this article in press as: Sikora V., Lyndin M., Hyriavenko N., Moskalenko R., Lyndina Y., Sikora K., Chyzhma R., Diachenko O., Romaniuk A. Morphological peculiarities of parasitic (*Trichosomoides crassicauda*) infection in rat urinary bladder. *Mac Vet Rev* 2021; 44 (2): i-ix. <https://doi.org/10.2478/macvetrev-2021-0019>