

Contents lists available at [ScienceDirect](https://www.sciencedirect.com)

North American Spine Society Journal (NASSJ)

journal homepage: www.elsevier.com/locate/xnsj

The usefulness and safety of the simultaneous parallel anterior and posterior combined lumbar spine surgery using intraoperative 3D fluoroscopy-based navigation (SPAPS)

Hisanori Ikuma^{a,*}, Tomohiko Hirose^a, Shinichiro Takao^c, Kazutoshi Otsuka^b, Keisuke Kawasaki^a^a Department of Orthopaedic Surgery, Kagawa Prefectural Central Hospital, 2-1, Asahi-machi 1-chome, Takamatsu City, Kagawa 760-0065, Japan^b Otsuka Orthopaedic Surgery Clinic, 1-24, Chuo-cho, Takamatsu City, Kagawa 760-0007, Japan^c Department of Orthopaedic Surgery, Okayama University Graduate School of Medicine, Dentistry, and Pharmaceutical Science, 5-1, Shikatacho 2-chome, Kita-ku, Okayama City, Okayama 700-8558, Japan

ARTICLE INFO

Keywords:

Single position surgery
Lateral decubitus position
Spine surgery
Navigation system
Parallel
Independent

ABSTRACT

Background: The combined anterior-posterior surgery in the lateral decubitus position generally needs the intraoperative repositioning. However, prolonged surgical time and increased medical costs due to intraoperative repositioning have been problematic. In recent years, there have been reports of combined anterior-posterior procedure with a single position performing anterior and posterior fixation consecutively where the patient remains in the lateral decubitus position (single surgeon method-SS method). We had further advanced this method, and have adopted the Simultaneous Parallel Anterior and Posterior combined lumbar spine Surgery using intraoperative 3D fluoroscopy-based navigation (SPAPS method), where anterior and posterior procedure are performed independently by two spine surgeons.

Methods: 66 cases that underwent SPAPS method (n=37) and SS method (n=29) from 2015 to 2019 at single institution were included in this study. The pre- and post-operative changes in the following were compared retrospectively between the two groups: surgical factors and clinical evaluations including JOA back pain evaluation questionnaire (JOABPEQ), visual analogue scale (VAS) on lower back pain, buttock/lower limb pain, and buttock/lower limb numbness, and Roland-Morris disability questionnaire (RDQ).

Results: The SPAPS method was able to significantly reduce the surgical time (p=0.0025) compared to the SS method, and allowed a reduction of approximately 24.4 minutes per segment. The estimated blood loss were similar in both groups, and with regards to post-operative outcomes, both groups improved equally well. The rates of screw deviation and fusion were also similar.

Conclusions: In the case of performing the combined anterior-posterior surgery under a single position, the anterior and posterior procedure can be performed independently and simultaneously by two spine surgeons by utilizing the 3D fluoroscopy-based navigation. The surgical time can be significantly reduced by approximately 24.4 minutes per segment comparing to the SS method.

Introduction

In the past, traditional open thoracolumbar combined anterior-posterior surgery had been considered as a major invasive procedure of the spine with a high risk of perioperative complications [1–3]. Over time, techniques have been devised to reduce its surgical trauma. Representative techniques include the extrapleural approach that reaches the thoracic vertebrae without thoracotomy [4], the retroperitoneal approach that reaches the lumbar vertebrae without laparotomy [5], etc.

However, since the spine is deeply nested, the surgical field has been very large, the surgical time was long, and there was a high volume of blood loss. In addition, when the operation from the anterior approach was complete, intraoperative repositioning was necessary to perform the instrumentation from the posterior approach. For this reason, it was a lengthy procedure.

The development of the lateral lumbar interbody fusion (LLIF) [6–9] facilitated decreased surgical insult, enabling minimally invasive spinal reconstruction from the anterior approach. Furthermore, the use

* Corresponding author.

E-mail address: i9ma9n@yahoo.co.jp (H. Ikuma).<https://doi.org/10.1016/j.xnsj.2020.100047>

Received 20 October 2020; Received in revised form 17 December 2020; Accepted 19 December 2020

Available online 23 December 2020

2666-5484/© 2020 The Authors. Published by Elsevier Ltd on behalf of North American Spine Society. This is an open access article under the CC BY-NC-ND license (<http://creativecommons.org/licenses/by-nc-nd/4.0/>)

of percutaneous pedicle screws (PPS) from the posterior approach minimized the surgical trauma of the combined anterior-posterior surgery as much as possible [10–12].

Attempts have been made in the recent years to reduce the surgical time of the combined anterior-posterior surgery by optimizing the advantages of these minimally invasive procedures. A typical technique involves an approach that performs LLIF and posterior screw fixation in the lateral decubitus position without intraoperative repositioning [13–18]. This method optimizes the percutaneous technique of PPS, and PPSs are inserted with the patient in the lateral decubitus position. By not performing intraoperative repositioning, it allows reduction of the surgical time.

Ziino et al. report that applying this technique could reduce the surgical time by approximately 44.4 minutes compared to the approach involving intraoperative repositioning [16]. We have further advanced this method, and have been performing the combined anterior posterior lumbar fusion procedure (the Simultaneous Parallel Anterior and Posterior combined lumbar spinal Surgery using intraoperative 3D fluoroscopy-based navigation: SPAPS) where two spinal surgeons independently and simultaneously perform anterior and posterior procedure.

The current study is a retrospective evaluation of outcomes of SPAPS in comparison to conventional minimally invasive anterior and posterior combined procedure that one surgeon performs anterior and posterior procedure consecutively with the patient remaining in the lateral decubitus position under fluoroscopy (single surgeon method: SS).

Materials and methods

Subjects

We retrospectively assessed consecutive 97 subjects aged 50 years or older who underwent combined anterior posterior lumbar fusion procedure in the lateral decubitus position for a degenerative disease, trauma, or an infectious disease in the thoracolumbar region between July 2015 and February 2019 in our institution. Of these, the SPAPS group where the anterior and posterior operations are performed independently and simultaneously by different spinal surgeons, and the SS group where one spinal surgeon performs anterior and posterior operations consecutively, were sampled, and those who could be followed 1 year after the surgery were included in the study. The exclusion criteria were severe osteoporosis (T score < -3.5), chronic inflammatory conditions, vascular, visceral or neural anatomy not compatible with the transposas approach.

The following items were examined: patient factors including age at the time of surgery, sex, body mass index (BMI), distribution of diagnosis and follow-up period; surgical factors including the fusion level, surgical time, intraoperative blood loss, perioperative complications, length of hospitalization, screw deviation rate, and fusion rate.

Clinical evaluations including JOA back pain evaluation questionnaire (JOABPEQ), visual analogue scale (VAS) on lower back pain, buttock/lower limb pain, and buttocks/lower limb numbness, and Roland-Morris disability questionnaire (RDQ). Pre-operative and post-operative changes in these items were compared retrospectively between the two groups.

Surgical time and intraoperative blood loss were calculated per intervertebral segment by dividing by the number of fixed vertebrae. The rate of screw deviation was evaluated using CT images taken immediately after the surgery (cross-sectional, sagittal, and coronal images were used for evaluation). Screw breaching grade by Ravi et al. was used for the evaluation of screw deviation [19]. This grading was based on the direction and magnitude of the breach where Grade 1 = in pedicle; Grade 2 = 0–2 mm; Grade 3 = 2–4 mm; Grade 4 = >4 mm.

The fusion of fracture site was assessed using CT images (cross-sectional, sagittal, and coronal images) taken 1 year after the surgery. The fusion was confirmed if bone bridges were observed in the area

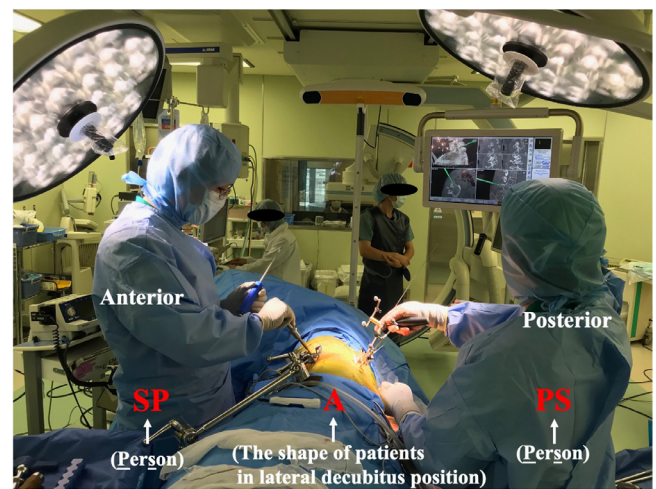


Fig. 1. After the patient is secured in the lateral decubitus position, a spine surgeon is placed each on the abdominal and dorsal sides who perform the surgery independently while using the navigation system. The meaning of SPAPS that was coined by us is as follows: PS and SP represent a person (surgeon), A represents the shape of the patient in lateral decubitus position, and the letters show surgeons standing at the front and dorsal sides of the patient performing the procedure.

where cages and the endplate meet as well as around the cages in any of the images. The image assessment was performed by the author or the co-author at a single institution. Patients were scheduled for follow-up evaluations (FU) at 3, 6, and 12 months.

Evaluation of JOABPEQ [20]

- Pre- and post-comparison of individuals

If the value of the post-treatment score increased by 20 points or more compared to the pre-treatment score or if the value of the pre-treatment score is less than 90 points, and the post-treatment score reaches 90 points or greater. The case was judged “Effective,” if either 1 or 2 was satisfied.

- Pre- and post-operative interpopulation comparisons

Efficacy rate in the population = (The number of individuals judged to be “Effective”) ÷ {(The number of individuals constituting the population)-

(The number of patients whose pre-treatment score was 90 points or more, and the post-treatment score was 90 points or more)}.

Evaluation of intergroup differences in treatment effects

Patients with pre-treatment scores of 90 points or more as well as with post-treatment score of 90 points or more were removed from the analysis set, and the efficacy rate was calculated for each population to verify the population rate.

Surgical Techniques (The simultaneous parallel anterior and posterior combined lumbar spinal surgery using intraoperative 3D fluoroscopy-based navigation: SPAPS method (Fig. 1))

First, the patient is secured on the operating table in the right lateral decubitus position using tapes. Use tapes to secure the patient in consideration for metal interfering with 3D fluoroscopy. Use body pressure dispersion mat when securing the patient to reduce pressure on bony protuberances and nerve tracts.

When draping is completed, set the reference frame on the left posterior superior iliac spine, and take 3D fluoroscopic images. Our department uses Artis-Zee® (Seimens AG Corp., Munich, Germany) to obtain high resolution 3D fluoroscopic images. The obtained images are automatically transferred to the navigation system of spine surgery, SPINE

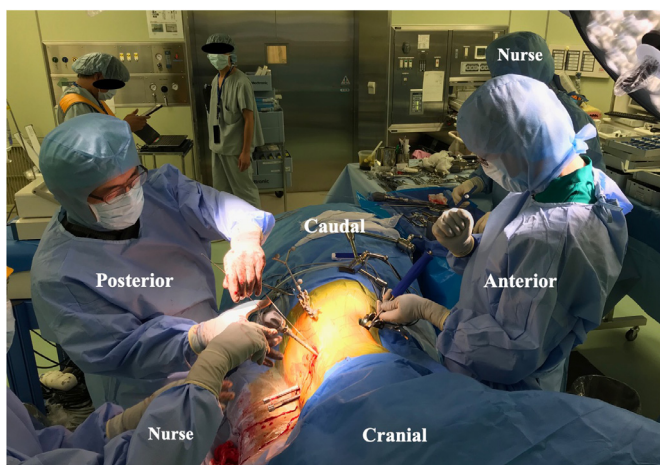

Fig. 2. Two surgeons are independently and simultaneously performing the anterior LLIF cage insertion and posterior percutaneous pedicle screw insertion.

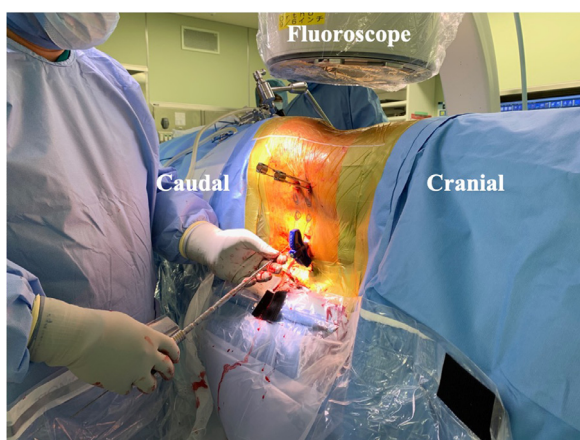


Fig. 3. One surgeon is inserting the posterior pedicle screw after inserting the anterior LLIF cage. Fluoroscope is prepared for use throughout the procedure.

NAVIGATION (Brainlab, Inc., Munich, Germany)®, and navigation begins.

Then, a spinal surgeon is placed each on the abdominal and dorsal sides of the patient, and they begin anterior approach and posterior PPS insertion simultaneously (Fig. 2). During surgery, each surgeon uses the surgical devise for SPINE NAVIGATION (Brainlab, Inc., Munich, Germany)® individually, and makes progress in parallel. Motor evoked potential (MEP) and directional triggered EMG stimulation (Nihon Kohden corp., Tokyo, Japan) are used throughout the surgery to monitor the status of nerves.

With this technique, since the navigation accuracy is reduced when operating on intervertebral discs from the front, stop after approaching the intervertebral discs until all guide wires for PPS are inserted, and perform the insertion of the LLIF cage after PPS guide wires are inserted. In addition, navigation with the patient in the lateral decubitus position, as opposed to the prone position, makes the vertebral body easier to move, and the navigation accuracy decreases over time. For these reasons, the insertion of guide wire should begin from the vertebral body that is furthest from the reference frame. When the anterior implant is eventually placed, tighten and secure the posterior construct, and complete the procedure.

Table 1
Patient's demographic data.

Variable	SPAPS	SS	p-value
Number of patients(n)	37	29	
Age (years)	67.1 ± 11.8	67.1 ± 12.6	n.s.
Gender (m/f)	14/23	13/16	n.s.
BMI (kg/m ²)	24.3 ± 4.2	23.6 ± 4.5	n.s.
Length of follow-up (months)	15.2 ± 2.2	23.5 ± 6.7	<0.05
Number of segments fused (mean)			
T10/11	1 (1.4%)	0(0%)	n.s.
T11/12	3(4.4%)	2(4.3%)	n.s.
T12/L1	3(4.4%)	5(10.8%)	n.s.
L1/2	7(10.2%)	7(15.2%)	n.s.
L2/3	10(14.7%)	8(17.3%)	n.s.
L3/4	15(22.1%)	8(17.3%)	n.s.
L4/5	25(36.7%)	14(30.4%)	n.s.
L5/S	4(5.8%)	2(4.3)	n.s.

Single surgeon method: SS method (Fig. 3)

First, secure the patient in the right lateral decubitus position. The SS group in this series consists of cases at our institution that could not use the navigation system for some reason, and we perform surgical procedures using a fluoroscope for imaging support. There is one surgeon by default.

With regards to the order of surgical operation, when the posterior operation is performed first, performing the LLIF cage insertion from the front after the posterior screw insertion is completed. When the anterior operation is performed first, anterior LLIF cage insertion is performed first, following by the posterior screw insertion. As such, one surgeon performs the anterior and posterior operations consecutively in this method.

Statistical examinations

In this study, statistical analysis was performed using ystat 2006® (Igakutosho-shuppan Ltd., Saitama, Japan). All values are expressed as mean ± standard deviation. Age at the time of surgery, body mass index, number of fixed vertebrae, surgical time, volume of intraoperative blood loss, length of hospitalization, JOABPEQ, VAS, and RDQ were assessed using the Mann-Whitney nonparametric test. Sex, fusion rate, screw deviation rate, and perioperative complications were assessed using the Chi-square test. The statistical significance was set at the threshold of $p < 0.05$.

Results

Patient's demographic data

Ultimately, 66 subjects were met in our criteria in the study. These subjects consist of 37 cases in the SPAPS group and 29 cases in the SS group. Of these, patients include 14 males and 23 females with the mean age of 67.1 ± 11.8 years for the SPAPS group, and 13 males and 16 females with the mean age of 67.1 ± 12.6 years for the SS group. Mean BMI and mean follow-up period were 24.3 ± 4.2 kg/m² and 15.2 ± 2.2 months for the SPAPS group, and 23.6 ± 4.5 kg/m² and 23.5 ± 6.7 months for the SS group. The fusion was performed between the T10/11 and L5/S, with the most common in the L4/5, followed by L3/4 and L2/3 (Table 1).

The distribution of diagnosis is as follows: in the SPAPS group, degenerative spondylolisthesis in 20 cases, degenerative scoliosis in 3 cases, canal stenosis with degenerative disc disease in 3 cases, spinal fracture in 3 cases, post traumatic pseudarthrosis in 3 cases, degenerative disc disease in 2 cases, pyogenic spondylitis in 2 cases, and a history of multiple spinal surgeries in 1 case; in the SS group, degenerative spondylolisthesis in 15 cases, spinal fracture in 9 cases, pyogenic

Table 2
Diagnosis for all subjects.

	SPAPS(n=37)	SS(n=29)
Degenerative spondylolisthesis	20	15
Degenerative scoliosis	3	0
Canal stenosis with degenerative disc disease	3	0
Spinal fracture	3	9
Post traumatic pseudarthrosis	3	0
Degenerative disc disease (DDD)	2	1
Pyogenic spondylitis	2	2
Multiple operated of back (MOB)	1	0
Destructive spondyloarthropathy	0	2

spondylitis in 2 cases, destructive spondylarthrosis in 2 cases, and degenerative disc disease in 1 cases (Table 2).

Surgical results

The fusion level was $1.35 \pm 0.5/1.78 \pm 1.2$ (the number of anterior fusion level/the number of posterior fusion level) in the SPAPS group and $1.41 \pm 0.6/1.75 \pm 1.1$ (the number of anterior fusion level/the number of posterior fusion level) in the SS group, showing no significant difference between the two groups.

The mean surgical time and mean estimated blood loss per segment were 103.0 ± 34.7 min and 84.1 ± 88.4 mL in the SPAPS group, and 127.4 ± 34.8 min and 91.9 ± 72.4 mL in the SS group respectively. There was a significant decrease in surgical time ($p = 0.0025$), where a reduction of approximately 24.4 minutes was possible. There was no significant difference between the groups in terms of the estimated blood loss.

With regards to perioperative complications, there was 1 case of psoas grade 4/5 weakness in either group, and both cases recovered within 3 months after the surgery. Thigh pain or numbness were observed in 6 cases in the SPAPS group and 4 cases in the SS group, and all recovered. One case of proximal junctional fracture was observed in both groups respectively, and one case of cage migration was observed in the SPAPS group, but none required surgery. There was one case in either group who underwent transfusion, and no cases in either group developed post-operative surgical site infection.

The mean length of hospitalization was 19.3 ± 8.2 days for the SPAPS group and 21.6 ± 9.5 days for the SS group, showing no significant difference. The fusion rate at 1 year after surgery was 88.2% for the SPAPS group and 85.9% for the SS group, showing no significant difference (Table 3).

Screw deviation rate and clinical outcomes

As for the screws, the SPAPS group and SS group inserted 195 and 147 pedicle screws respectively with the screw deviation rate at 4.6% in the SPAPS group and 5.4% in the SS group, showing no significant difference between the groups. The direction of deviation was in the outward direction for all cases in both groups (Table 4).

Pre- and post-operative changes in JOABPEQ, VAS for low back pain, buttock/lower limb pain, and buttock/lower limb numbness, and RDQ presented favorable improvements after the surgery in both groups, and no significant difference was observed (Table 5).

Discussions

With the introduction of LLIF, there has been an increase in the number of spinal surgeons who are familiar with performing spinal surgery in the lateral decubitus position, resulting in an increase in the number of reports in recent years where screw insertion from the posterior side is performed in the lateral decubitus position [13–18]. The previous method performed an intraoperative repositioning after inserting

the LLIF cage via the anterior approach with the patient in the lateral decubitus position, and inserted pedicle screws in the prone position.

However, multiple approaches often requires intraoperative repositioning prolongs surgical time and increases medical costs [13]. Prolonged surgical time also increases the risks of cardiovascular complications, decreased pulmonary compliance, and the onset of hypovolemia. In addition, the possibility of post-operative vision loss cannot be ignored as one of the complications from prone positioning [21–23].

In recent years, the situation surrounding medical costs is moving towards establishing health care that is safe and low cost [24,25], and single position lateral surgery may be one of the spine surgical procedures that meets this demand. The report of the first single position lateral surgery was made by Blizzerd et al. According to the report, performing the procedure in a single position avoiding intraoperative repositioning significantly reduced surgical time and radiation exposure, and the authors also mentions that medical costs could be low [13].

The calculation of the actual medical cost is extremely challenging as it is influenced by various factors such as patient matters, environmental factors of the operating room etc. However, Abbasi et al. reported that the cost of operating room time for oblique lateral lumber interbody fusion (OLLIF) to be approximately \$83 per minute [26]. In addition, Blizzerd et al. referenced a report by Tohmeh et al. that it was possible to reduce the surgical time by 38 minutes by skipping intraoperative repositioning in the single position method [27], and mentions that the method can reduce medical costs by \$3154 per case [13].

In our SPAPS method, the surgical procedure is performed in single position, and by proceeding with anterior and posterior operations independently with two spine surgeons, it reduced the surgical time by 24.4 minutes per segment compared to conventional single position lateral surgery (SS method) performed by one spine surgeon. Based on this result, while it is necessary to have two spine surgeons with the SPAPS method, there is a possibility of further medical cost reduction. On the other hand, with respect to the amount of blood loss per segment, there was no significant difference between the two groups as the procedures are both minimally invasive, with blood loss in the SPAPS method was 84.1 mL and the SS method was 91.9 mL.

The SPAPS method is characterized by the use of the navigation system throughout the procedure to perform the surgery. When taking images for intraoperative navigation, the surgeons, anesthesiologist, and the operating room staff all step out of the operating room. With this, radiation exposure among all medical staff can be reliably reduced compared to conventional surgical procedures that use fluoroscopy.

On the other hand, when looking at the previous reports of procedures using fluoroscopy, the time of radiation exposure per percutaneous pedicle screw was 15–27 seconds [13,28,29], subjecting surgeons to a relatively high radiation exposure. This helps understand the advantage of using the navigation system in the SPAPS method with regards to radiation exposure.

Another advantage of the navigation system is the improved accuracy of screw insertion. As a result of a comparing 195 screws in the SPAPS method and 147 screws in the SS method in this study, the rates of screw deviation in this study were 4.6% and 5.4% respectively with no significant difference. However, it should be noted that a Grade 4 deviation was observed in the SPAPS method group. It was the first case after introducing the SPAPS method, and was caused by the navigation error that was not noticed during surgery. This patient developed post-operative radicular pain, which fortunately improved over time, and did not result in reoperation. In addition, there were no other cases of screw deviation that presented neurological disorders resulting in reoperation.

Since the lateral decubitus position is less secure compared to the prone position that employs a four-point frame, it is easy to cause vertebral body movement from surgical manipulation, and the surgeon should keep in mind that navigation errors occur easily in the beginning when the procedure is unfamiliar. Also, all deviation directions were outwards, and the fact that most of them were down-side screws is an important outcome. As presented in previous reports [6,30,31],

Table 3
Surgical result.

	SPAPS(n=37)	SS(n=29)	p-value
Fusion level – anterior	1.35 ± 0.5	1.41 ± 0.6	n.s.
Fusion level – posterior	1.78 ± 1.2	1.75 ± 1.1	n.s.
Surgical time per segment(min)	103.0 ± 34.7	127.4 ± 34.8	0.0025
Estimated blood loss per segment(ml)	84.1 ± 88.4	91.9 ± 72.4	n.s.
Perioperative complication			
Psoas grade 4/5 weakness	1(resolved by month 3)	1(resolved by month 3)	n.s.
Thigh pain or numbness	5(4 resolved by month 3)	4(all resolved by month 4)	n.s.
Transfusion	1	1	n.s.
Surgical site infection	0	0	n.s.
Length of stay(days)	19.3 ± 8.2	21.6 ± 9.5	n.s.
Mechanical complication			
Proximal junctional fracture	1(no need for surgery)	1(no need for surgery)	n.s.
Cage migration	1(no need for surgery)	0	n.s.
Fusion rate(%) (one year post-op)	88.2	85.9	n.s.

Table 4
Screw deviation rate.

	SPAPS(n=195)	Direction	SS(n=147)	Direction	p-value
Grade1 (in pedicle)	186(95.3%)		142(96.5%)		n.s.
Grade2 (0-2mm)	5(2.5%) Down-side for all	Lateral for all	4(2.7%) Down-side for all	Lateral for all	n.s.
Grade3 (2-4mm)	3(1.5%) Up-side for 2 cases Down-side for 1 case	Lateral for all	4(2.7%) Down-side for all	Lateral for all	n.s.
Grade4 (>4mm)	1(0.5%) Down-side for all	Lateral for all	0(0%)		n.s.
Total number of screw perforations	9(4.6%)	Lateral for all	8(5.4%)	Lateral for all	n.s.

Table 5
Clinical outcomes.

The parameter of functional scores	SPAPS(n=37)		The effectiveness of the treatment	SS(n=29)		The effectiveness of the treatment	p-value
	Pre-op	Post-op (1 year)		Pre-op	Post-op (1 year)		
Low back pain	38.8 ± 34.4	85.2 ± 21.9	0.843	46.1 ± 32.8	78.2 ± 28.8	0.681	n.s.
Lumbar function	44.1 ± 28.2	64.3 ± 26.6	0.485	52.4 ± 26.0	72.7 ± 25.8	0.357	n.s.
Walking ability	33.6 ± 28.1	66.6 ± 32.3	0.675	26.4 ± 30.1	65.5 ± 33.1	0.535	n.s.
Social life function	37.2 ± 20.4	63.9 ± 23.3	0.648	32.4 ± 20.6	56.6 ± 25.6	0.448	n.s.
Mental health	39.0 ± 15.8	57.3 ± 14.4	0.486	43.5 ± 17.9	60.0 ± 22.7	0.344	n.s.
<i>Visual analogue scale</i>			Recovery rate (%)			Recovery rate (%)	n.s.
Low back pain	5.7 ± 2.8	1.8 ± 1.9	68.4	5.3 ± 2.7	1.8 ± 2.1	66.0	n.s.
Pains in buttocks and lower limb(s)	5.8 ± 3.1	1.6 ± 2.0	72.4	5.4 ± 3.1	1.8 ± 2.5	66.6	n.s.
Numbness in buttocks and lower limb(s)	4.3 ± 3.1	1.4 ± 2.2	67.4	4.9 ± 3.1	2.0 ± 2.5	59.1	n.s.
<i>Roland-Morris Disability Questionnaire</i>	12.8 ± 4.7	5.3 ± 6.2	58.5	16.0 ± 6.2	7.1 ± 5.2	55.6	n.s.

positioning the patient near the center of the operating table results in the edge of the table interfering during insertion of down-side screws, and adequate screw insertion angle cannot be obtained. For this reason, the down-side screw tends to deviate outwards. It is important that the patient is positioned near the end of the operating table about 1/4th of the way across the bed from the surgeon [13].

There was one case of psoas grade 4/5 weakness in either group that occurred immediately after surgery, and both spontaneously improved within 3 months from the surgery. Thigh pain or numbness was observed in 6 cases in the SPAPS method and 4 cases in the SS method, and all cases spontaneously improved within 4 months.

A report by Walker et al. [32] noted transient hip flexion weakness and transient anterior thigh sensory symptom as major complications following the XLIF procedure, with rates at 19.7% (range 0 to 54.9%) and 21.7% (range 0 to 50%) respectively, as well as persistent motor neurological weakness at 2.8%. Our results showed a few transient hip flexion weaknesses at 5.5% (one case in the SPAPS method and one case in the SS method). The reason for this was believed to be due to the fact that the targeted area was broad ranging from T10 to L5. In addition, the anterior thigh sensory symptom developed in 13.6% of the cases (five cases in the SPAPS method and four cases in the SS method) among which all but one case (1.1%) spontaneously improved within 4

months. The persistent case was that of grade 4 screw deviation in the SPAPS method. The subject suffered a lumbar plexus damage due to an outward deviation of the pedicle screw at L3.

The method to evaluate the clinical performance used in this study are as follows: JOABPEQ, VAS for low back pain, buttock/lower limb pain, and buttock/lower limb numbness, and RDQ, but there are no reports that utilized these assessments in single position surgeries, and our results cannot be compared with previous reports. The reason why we used JOABPEC was because all subjects in this study were Japanese, and that it is a clinical evaluation method prepared in Japan based on Japanese living conditions and psychological aspects. Also, the reason for using RDQ was that it was necessary to evaluate back pain because percutaneous pedicle screws were used in posterior instrumentation with the objective of minimizing surgical trauma to back muscle.

The purpose of the current study was to study the two surgical procedures, and for this reason, statistical tests on pre- and post-operative rates of change within each procedure were not performed. With regards to JOABPEQ and RDQ one year after the procedure, there was no significant difference between the two groups, and both showed good improvement. In the previous reports on VAS in XLIF [33,34], Khajavi et al. reported that the rates of improvement in VAS

back and VAS leg were 59% (from 6.9 to 2.8) and 56% (from 7.1 to 3.1), and Tohmeh et al. reported 49% (from 7.5 to 3.8) and 48% (from 6 to 3.1). Our results were also similar. In addition, there was no significant difference in the bone union rates between the groups one year after the surgery, and the results were satisfactory for both groups.

In terms of mechanical complications, one case of proximal junctional fracture and one case of cage migration was observed in the SPAPS method, and one case of proximal junctional fracture in the SS method. The proximal junctional fracture did not have a strong impact on post-operative course in either group, and these could be treated with a conservative treatment using a corset. Cage migration was observed in one case in the SPAPS method, and the patient was advanced in age at 81 years with a low T-score of -2.1 . 1 month after performing the SPAPS procedure on the L4/5 intervertebral segment, a backout occurred about 1/4th the length of the cage on the side where the cage was inserted, which subsequently stopped, and fusion was achieved 10 months after the surgery. During the course, there were few complaints of lower back pain despite changes in imaging, and the clinical course was favorable. At 1 year after the surgery, JOABPEQ significantly improved in all categories other than mental health, and VAS for lower back pain, buttock/lower limb pain, and buttock/lower limb numbness improved from 8 to 3, 7 to 3, and 8 to 2, respectively. RDQ decreased from 12 to 1.

There are several limitations to this study. The sample sizes of the two groups were small, and the follow-up period was only around 1 year. As the study method was not a randomized trial, the author was involved in the analysis of the results in this study, and it was not a blinded test. Also, since the target disorders in both groups was not uniform and there are some differences about the setup time between the navigation system and image guidance, it is not possible to purely compare SPAPS and SS groups. For these reasons, the interpretation of the results of this study comparing these two groups requires caution, and it is necessary to take into account that there are biases.

Conclusions

The SPAPS method was able to significantly reduce the surgical time ($p=0.0025$) compared to the SS method, and allowed a reduction of approximately 24.4 minutes per segment. The estimated blood loss was similar in both groups, and with regards to post-operative outcomes, both groups improved equally well. The rates of screw deviation were also similar, but a grade 4 deviation was initially observed in the SPAPS group.

Compliance with ethical standards

Ethical Approval: The study was approved by the Institutional Review Board of Kagawa Prefectural Central Hospital, Kagawa, Japan.

Declaration of Competing Interest

For all authors, there are no conflicts of interest to declare.

Reference

- [1] Allain J. Anterior spine surgery in recent thoracolumbar fractures: an update. *Orthop Traumatol Surg Res* 2011;97(5):541–54.
- [2] Villavicencio AT, Burneikiene S, Bulsara KR, Thramann JJ. Perioperative complications in transforaminal lumbar interbody fusion versus anterior-posterior reconstruction for lumbar disc degeneration and instability. *J Spinal Disord Tech* 2006;19(2):92–7.
- [3] Acosta FL, Cloyd JM, Aryan HE, Ames CP. Perioperative complications and clinical outcomes of multilevel circumferential lumbar spinal fusion in the elderly. *J Clin Neurosci* 2009;16(1):69–73.
- [4] Kaneda K, Abumi K, Fujiya M. Burst fractures with neurologic deficits of the thoracolumbar-lumbar spine. Results of anterior decompression and stabilization with anterior instrumentation. *Spine* 1984;9(8):788–95.
- [5] Iwahara T, Ikeda K, Hirabayashi K. Results of anterior spine fusion by extraperitoneal approach for spondylolysis and spondylolisthesis. *Nihon Seikeigeka Gakkai Zasshi* 1963;36:1049–67.
- [6] Ozgur BM, Aryan HE, Pimenta L, Taylor WR. Extreme lateral interbody fusion (XLIF): a novel surgical technique for anterior lumbar interbody fusion. *Spine J* 2006;6(4):435–43.
- [7] Berjano P, Balsano M, Buric J, Petrucci M, Lamartina C. Direct lateral access lumbar and thoracolumbar fusion: preliminary results. *Eur Spine J* 2012;21(Suppl 1):S37–42.
- [8] Youssef JA, McAfee PC, Patty CA, Raley E, DeBauche S, Shucosky E, et al. Minimally invasive surgery: lateral approach interbody fusion: results and review. *Spine (Phila Pa 1976)* 2010;35(Suppl 26):S302–11.
- [9] Uribe JS, Deukmedjian AR. Visceral, vascular, and wound complications following over 13,000 lateral interbody fusions: a survey study and literature review. *Eur Spine J* 2015;24(Suppl 3):386–96.
- [10] Oda Y, Yamauchi T, Tanaka M. Lateral lumbar interbody fusion with percutaneous pedicle screw in combination with microendoscopic laminectomy in the lateral position for lumbar canal stenosis. *Acta Med Okayama* 2019;73(4):373–7.
- [11] Hiyama A, Sakai D, Sato M, Watanabe M. The analysis of percutaneous pedicle screw technique with guide wire-less in lateral decubitus position following extreme lateral interbody fusion. *J Orthop Surg Res* 2019;14(1):304.
- [12] Vora D, Kinnard M, Falk D, Hoy M, Gupta C, Yu W, et al. A comparison of narcotic usage and length of post-operative hospital stay in open versus minimally invasive lumbar interbody fusion with percutaneous pedicle screws. *J Spine Surg* 2018;4(3):516–21.
- [13] Blizzard DJ, Thomas JA. MIS single-position lateral and oblique lateral lumbar interbody fusion and bilateral pedicle screw fixation: feasibility and perioperative results. *Spine (Phila Pa 1976)* 2018;43(6):440–6.
- [14] Ouchida J, Kanemura T, Sakate K, Nakashima H, Ishikawa Y, Imagama S. Simultaneous single-position lateral interbody fusion and percutaneous pedicle screw fixation using O-arm-based navigation reduces the occupancy time of the operating room. *Eur Spine J* 2020;29(6):1277–86.
- [15] Ziino C, Arzeno Z, Cheng I. Analysis of single-position for revision surgery using lateral interbody fusion and pedicle screw fixation: feasibility and perioperative results. *J Spine Surg* 2019;5(2):201–6.
- [16] Ziino C, Konopka JA, Ajiboye RM, Ledesma J, Koltzov JCB, Cheng I. Single position versus lateral-then-prone positioning for lateral interbody fusion and pedicle screw fixation. *J Spine Surg* 2018;4(4):717–24.
- [17] Baum GR, Lin JD, Morr S, Osorio JA, Leung E, Schutzer RW, et al. Minimally invasive approach to the lumbosacral junction with a single position, 360° fusion. *J Spine Surg* 2019;5(Suppl 1):S68–73.
- [18] Quiceno E, Hartman C, Godzik J, Pacult MA, Hemphil C, Uribe JS. Single position spinal surgery for the treatment of grade ii spondylolisthesis: a technical note. *J Clin Neurosci* 2019;65:145–7.
- [19] Ravi B, Zahrai A, Rampersaud R. Clinical accuracy of computer-assisted two-dimensional fluoroscopy for the percutaneous placement of lumbosacral pedicle screws. *Spine* 2010;36(1):84–91.
- [20] Fukui M, Chiba K, Kawakami M, Kikuchi S, Konno S, Miyamoto M, et al. JOA back pain evaluation questionnaire (JOABPEQ)/JOA cervical myelopathy evaluation questionnaire (JOACMEQ). The report on the development of revised versions. April 16, 2007. The subcommittee of the clinical outcome committee of the Japanese orthopaedic association on low back pain and cervical myelopathy evaluation. *J Orthop Sci* 2009;14(3):348–65.
- [21] Kwee MM, Ho YH, Rozen WM. The prone position during surgery and its complications: a systematic review and evidence-based guidelines. *Int Surg* 2015;100(2):292–303.
- [22] Anastasian ZH, Gaudet JG, Levitt LC, Mergeche JL, Heyer EJ, Berman MF, et al. Factors that correlate with the decision to delay extubation after multilevel prone spine surgery. *J Neurosurg Anesthesiol* 2014;26(2):167–71.
- [23] DePasse JM, Palumbo MA, Haque M, Ebersson CP, Daiels AH, et al. Complications associated with prone positioning in elective spinal surgery. *World J Orthop* 2015;6(3):351–9.
- [24] Macario A. What does one minute of operating room time cost? *J Clin Anesth* 2010;22(4):233–6.
- [25] Tan JM, Macario A. How to evaluate whether a new technology in the operating room is cost-effective from society's viewpoint. *Anesthesiol Clin* 2008;26(4):745–64 viii.
- [26] Abbasi H, Murphy MM. Economic performance of oblique lateral lumbar interbody fusion (OLLIF) with a focus on hospital throughput efficiency. *Cureus* 2015;7(7):e292.
- [27] Tohmeh AG, Watson B, Tohmeh M, Zielinski XJ, et al. Allograft cellular bone matrix in extreme lateral interbody fusion: preliminary radiographic and clinical outcomes. *Sci World J* 2012;2012:263637.
- [28] Fransen P. Fluoroscopic exposure in modern spinal surgery. *Acta Orthop Belg* 2011;77(3):386–9.
- [29] Spitz SM, Sandhu FA, Voyadzis JM. Percutaneous "K wireless" pedicle screw fixation technique: an evaluation of the initial experience of 100 screws with assessment of accuracy, radiation exposure, and procedure time. *J Neurosurg Spine* 2015;22(4):422–31.
- [30] Abe K, Orita S, Mannojo C, Motegi H, Aramomi M, Ishikawa T, et al. Perioperative complications in 155 patients who underwent oblique lateral interbody fusion surgery: perspectives and indications from a retrospective, multicenter survey. *Spine (Phila Pa 1976)* 2017;42(1):55–62.
- [31] Silvestre C, Mac-Thiong J, Hilmil R, Roussouly P, et al. Complications and morbidities of mini-open anterior retroperitoneal lumbar interbody fusion: oblique lumbar interbody fusion in 179 patients. *Asian Spine J* 2012;6(2):89–97.

- [32] Walker CT, Farber SH, Cole TS, Xu DS, Godzik J, Whiting AC, et al. Complications for minimally invasive lateral interbody arthrodesis: a systematic review and meta-analysis comparing prepsoas and transpsoas approaches. *J Neurosurg Spine* 2019;25:1–15.
- [33] Khajavi K, Shen A, Lagina M, Hutchinson A. Comparison of clinical outcomes following minimally invasive lateral interbody fusion stratified by preoperative diagnosis. *Eur Spine J* 2015;24(Suppl 3):322–30.
- [34] Tohmeh AG, Khorsand D, Watson B, Zielinski X. Radiographical and clinical evaluation of extreme lateral interbody fusion: effect of cage size and instrumentation type with a minimum of 1-year follow-up. *Spine* 2014;39(26):E1582–91.