



Contents lists available at [ScienceDirect](https://www.sciencedirect.com)

JPRAS Open

journal homepage: [www.elsevier.com/locate/jpra](http://www.elsevier.com/locate/jpra)



## Case Report

# Perineal reconstruction supplemented by abdominal advancement following recurrent penile cancer: Two cases

J Ward<sup>a,\*</sup>, M Little<sup>a</sup>, B Ayres<sup>b</sup>, M Soldin<sup>a</sup>

<sup>a</sup> Department of Plastic and Reconstructive Surgery, St George's Hospitals NHS Foundation Trust, Blackshaw Road, London SW17 0QT, United Kingdom

<sup>b</sup> Department of Urology, St George's Hospitals NHS Foundation Trust, Blackshaw Road, London SW17 0QT, United Kingdom

## ARTICLE INFO

### Article history:

Received 5 October 2020

Accepted 11 July 2021

Available online 21 July 2021

### Keywords:

Perineal reconstruction

Penile cancer

Abdominal advancement

Surgical salvage

## ABSTRACT

Reconstruction after excision of locoregionally recurrent penile cancer can be a surgical challenge. In this short study, we present two cases of perineal reconstruction using bilateral gracilis flaps supplemented by abdominal advancement for salvage of recurrent penile cancer, reviewing relevant literature and outlining our local approach to the perineum.

Crown Copyright © 2021 Published by Elsevier Ltd on behalf of British Association of Plastic, Reconstructive and Aesthetic Surgeons.

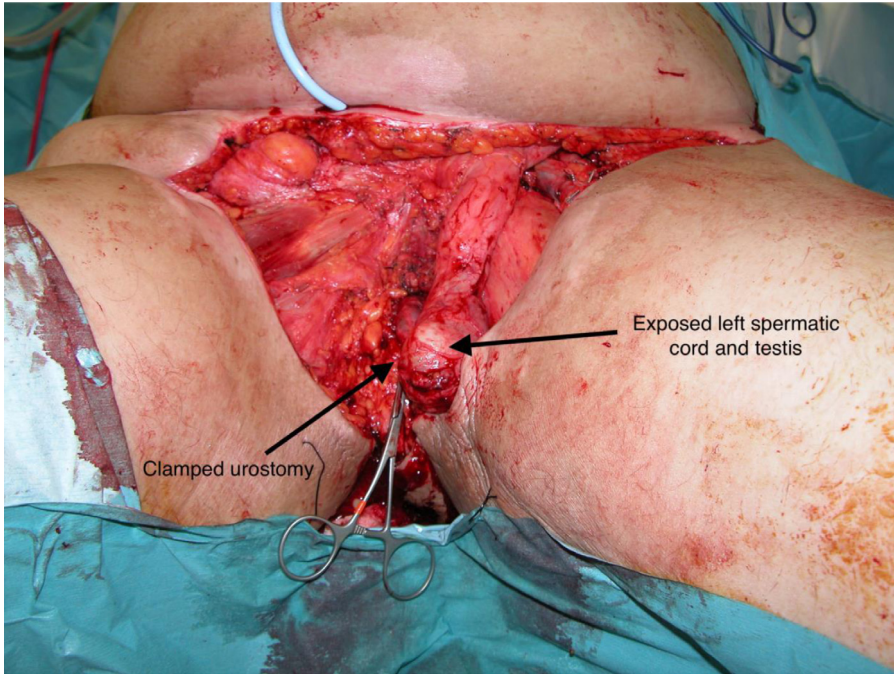
This is an open access article under the CC BY-NC-ND license (<http://creativecommons.org/licenses/by-nc-nd/4.0/>)

## Introduction

Penile cancer is a rare urological malignancy affecting approximately 700 men each year in the United Kingdom (UK). Surgery is the mainstay of primary treatment and when performed in combination with adjuvant therapies delivers five-year survival rates close to 75%.<sup>1</sup> In cases of locally advanced or recurrent disease, radical treatment (surgery or radiotherapy) is recommended by the UK guidelines.<sup>2</sup> Surgery in this context often results in extensive tissue loss necessitating salvage reconstruction to resurface groin or perineal defects and cover critical structures such as the femoral

\* Corresponding author.

E-mail address: [joseph.a.ward@btinternet.com](mailto:joseph.a.ward@btinternet.com) (J. Ward).



**Fig. 1.** Case 1 – Intra-operative image demonstrating an extensive perineal defect extending into the left groin with exposed left testis and spermatic cord.

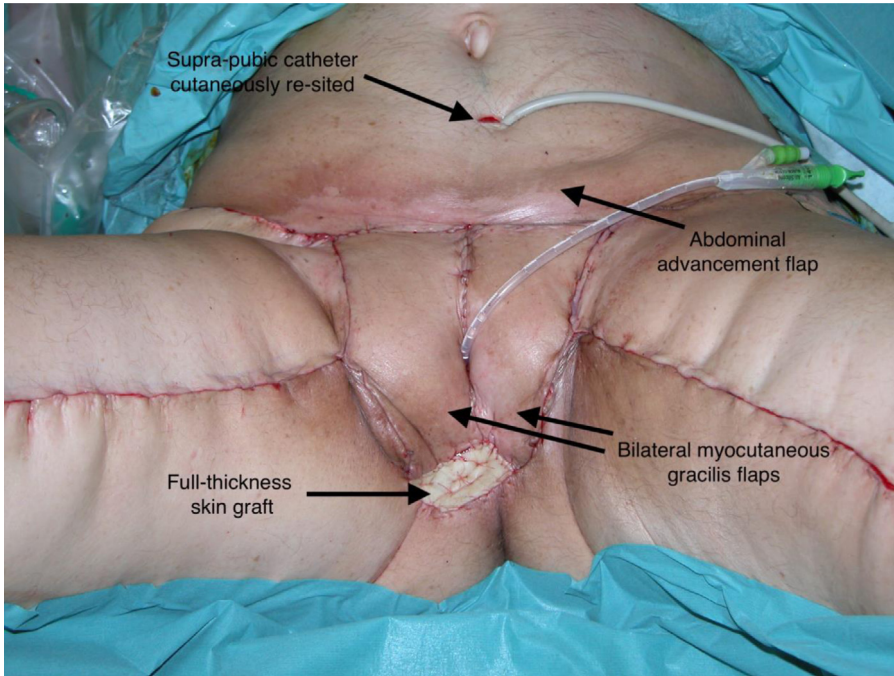
vessels. Historically, health-related quality of life outcomes have been poor, but as reconstructive expertise has improved, tolerable morbidity and a return to normal activity are achievable. In this study, we present two cases of salvage perineal reconstruction following penile cancer using bilateral myocutaneous gracilis flaps and abdominal advancement. We describe related literature and outline our local approach to the perineum.

### Case 1

A 79-year-old male with multiple cardiopulmonary comorbidities presented with a two-month history of worsening groin pain. He had previously undergone a subtotal penectomy and left inguinal dissection for a grade 3 pT3a pN3 cM0 penile squamous cell carcinoma (SCC) reconstructed using a tensor fascia lata (TFL) flap. Clinical evaluation demonstrated left groin recurrence but no distant metastases. Following multidisciplinary discussion, palliative surgery was planned with the excision of recurrent disease and locoregional reconstruction. Intraoperatively, the scrotal, perineal, right and left inguinal skin (up to the border of the previous TFL flap) were resected leaving the left spermatic cord and testis (Fig. 1). Coverage of exposed left femoral vessels, pubic bone, and anterior perineum was achieved using more than 15 cm of abdominal advancement supplemented with bilateral gracilis myocutaneous flaps and a small, full-thickness skin graft (Fig. 2). Urinary drainage was maintained through an existing urethrostomy and suprapubic catheterization site. Delayed wound healing was achieved.

### Case 2

A fully active 75-year-old male presented with perineal and scrotal skin breakdown following total penectomy and bilateral inguino-pelvic lymph node dissection supplemented by adjuvant inguinal and pelvic chemoradiotherapy for grade 3 pT3a pN3 cM0 penile SCC. Clinical ex-



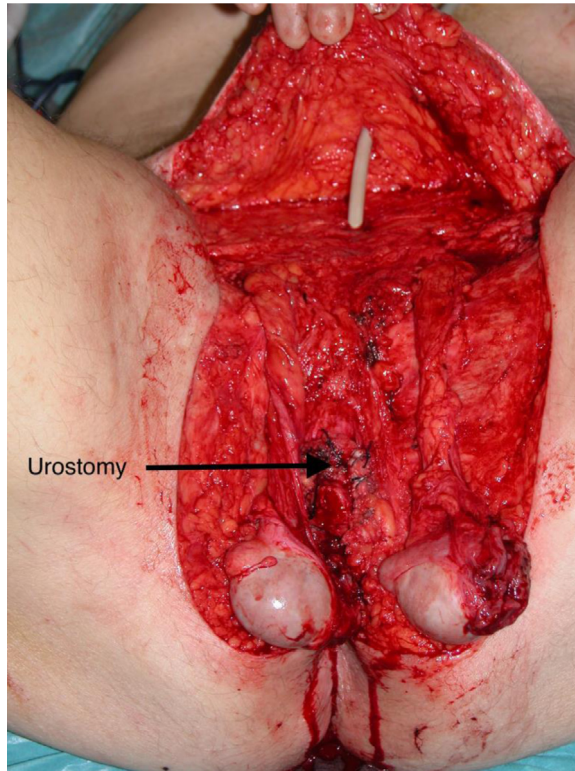
**Fig. 2.** Case 1 – Postoperative image demonstrating closure with bilateral gracilis flaps supplemented by abdominal advancement and a full-thickness skin graft.

amination revealed multiple scrotal and perineal cutaneous deposits in addition to a discharging right groin sinus. Imaging showed locally advanced disease, but no distant metastases. Multidisciplinary discussion deemed palliative surgery to be appropriate. Intraoperatively, the scrotal and perineal skin were excised up to the anal verge with spermatic cord preservation (Fig. 3). The large perineal defect was closed by extensive abdominoplasty advancement supplemented by bilateral myocutaneous gracilis flaps (refer Fig. 4). Urinary drainage was maintained through an existing urethrostomy and suprapubic catheterization site. Timely uncomplicated wound healing was achieved.

## Discussion

We present two cases of perineal reconstruction using bilateral myocutaneous gracilis flaps supplemented by abdominal advancement. When reconstructing the perineum, the plastic surgeon must deliver durable, well-vascularized tissue with sufficient bulk to fill dead space that is ideally harvested from an unirradiated donor site. Owing to its midline location at the lower limb origin, the perineal region is blessed with excellent vascularity derived from the iliac providing several locoregional perforators (lotus petal, deep inferior epigastric artery, gluteal artery, anterolateral thigh) and pedicled (rectus abdominis and gracilis muscle) flap options. Our rationale for employing the myocutaneous gracilis flap in both cases was its reliable nature, proximity to the perineum, long skin paddle, bilateral availability, and avoidance of abdominal wall violation. Furthermore, it can be harvested with relative ease, minimal donor morbidity, and is well-described for perineal reconstruction with complication rates comparable to other pedicled muscle options albeit increased by obesity, active smoking status, and previous chemoradiation.<sup>3</sup>

We used suprapubic abdominal advancement to close the anterior perineal defects in both cases as a low-risk manoeuvre. At least three other authors have reported the use of abdominal advancement



**Fig. 3.** Case 2 – Intraoperative image demonstrating a large perineal defect with exposed bilateral testis and spermatic cord.

for closure of anterior perineal or groin defects predominantly for the reconstruction of extensive hidradenitis suppurativa.<sup>4-6</sup> This is a context where delayed wound healing is expected and low-risk surgical strategies are indicated. We could identify only one other instance of abdominal advancement being used for postoncological reconstruction for a total penectomy case that necessitated bilateral inguinal nodal dissection, orchiectomy, and subtotal scrotoectomy, thereby leaving an anterior perineal defect.<sup>7</sup>

The surgical decision-making for perineal reconstruction is nuanced with considerations that include patient comorbidities, previous surgery, nutritional status, and available donors taken into account. The reconstructive surgeon may frequently need to “think on their feet” determining the reconstructive plan intraoperatively, when faced with final oncological defect making cases both challenging and interesting. We strongly advocate reconstructive approaches that do not unduly prolong operative time to reduce complications. Our local reconstructive strategy for locally advanced penile cancer salvage is to use a tensor fascia lata flap for groin reconstruction because of its thin pliable nature, easy transposition, and avoidance of tedious perforator dissection. Suprapubic defects are addressed with abdominal advancement, wherever possible, with extension into the anterior perineum as necessary. A unilateral or bilateral gracilis is chosen for the reconstruction of the middle and posterior perineal two-thirds for the reasons stated above; however, gluteal fold and inferior gluteal artery perforator flaps are reliable alternate choices for midposterior perineal defects. Where pan-perineal reconstruction is required and a laparotomy is indicated, we will perform a rectus abdominis muscle flap with close attention paid to minimize abdominal wall morbidity.



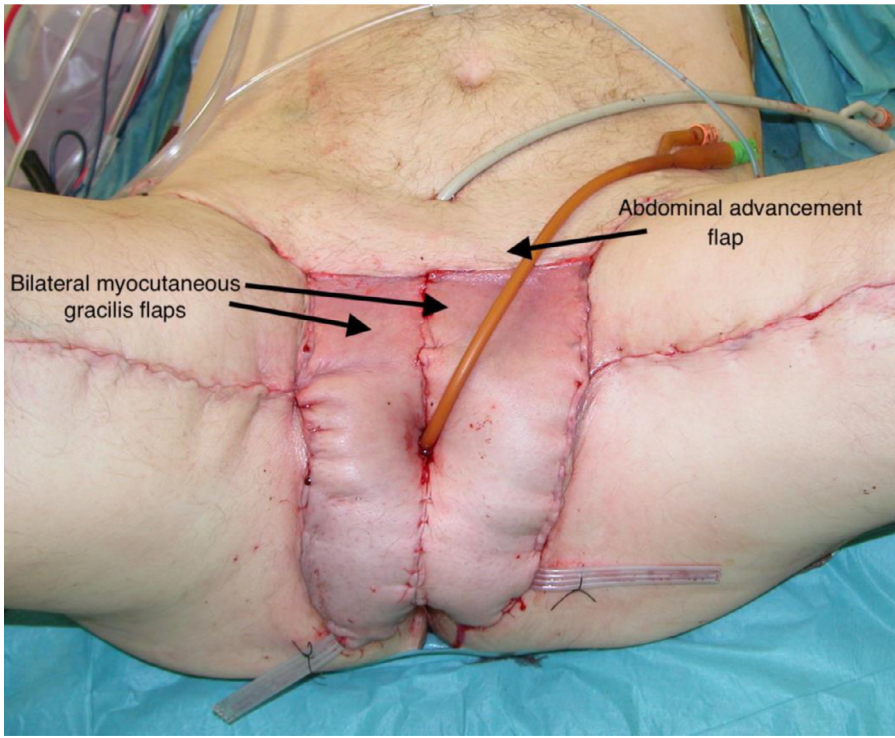


Fig. 4. Case 2 - Postoperative image demonstrating closure with bilateral gracilis flaps and abdominal advancement.

## Conclusion

We have presented two successful cases of perineal reconstruction using bilateral gracilis flaps aided by abdominal advancement. The challenges of wound healing in perineal reconstruction necessitate the use of such adaptable, reliable, and low-risk surgical strategies. In the context of salvage reconstruction, reconstructive choices must be closely tailored to an individual patient's medical and functional status, to minimize complications.

## Funding

None

## Ethical approval

Not required

## Declaration of Competing Interest

None declared

## References

1. Cancer Research UK. Penile Cancer Statistics. <https://www.cancerresearchuk.org/health-professional/cancer-statistics/statistics-by-cancer-type/penile-cancer> (Accessibility verified 7th May 2021).

2. NHS England. Guidelines for the management of penile cancer (West Midlands expert advisory group for urological cancer), Dec 2016. <https://www.england.nhs.uk/mids-east/wp-content/uploads/sites/7/2018/05/guidelines-for-the-management-of-penile-cancer.pdf> (Accessibility verified 7th May 2021)
3. Singh M, Kinsley S, Huang A, et al. Gracilis flap reconstruction of the perineum: an outcomes analysis. *J Am Coll Surg.* 2016;223(4):602–610.
4. Mizukami T, Fujiwara M, Ishikawa K, Aoyama S, Fukamizu H. Reconstruction for extensive groin hidradenitis suppurativa using a combination of inferior abdominal flap and medial thigh-lift: a case report. *Aesthetic Plast Surg.* 2014;38:745–748.
5. Greenbaum AR. Modified abdominoplasty as a functional reconstruction for recurrent hidradenitis suppurativa of the lower abdomen and groin. *Plast Reconstr Surg.* 2007;119:764–766.
6. Johnson 3rd ON, Potter BK, Bonnacarrere ER. Modified abdominoplasty advancement flap for coverage of trauma-related hip disarticulations complicated by heterotopic ossification: a report of two cases and description of surgical technique. *J Trauma.* 2008;64:E54–E59.
7. Ottenhof SR, Leone A, Djajadiningrat RS, et al. Surgical and oncological outcomes in patients after vascularised flap reconstruction for locoregionally advanced penile cancer. *Eur Urol Focus.* 2019;5:867–874.