


Contents lists available at [ScienceDirect](http://ScienceDirect.com)

eNeurologicalSci

journal homepage: [www.elsevier.com/locate/ensci](http://www.elsevier.com/locate/ensci)

Review article

## The role of optic nerve sheath diameter ultrasound in brain infection

Gavin A. Stead<sup>a,\*</sup>, Fiona V. Cresswell<sup>a,b,c</sup>, Samuel Jjunju<sup>a</sup>, Pham K.N. Oanh<sup>d</sup>,  
Guy E. Thwaites<sup>e,f</sup>, Joseph Donovan<sup>e,f</sup>

<sup>a</sup> Infectious Diseases Institute, Kampala, Uganda<sup>b</sup> Clinical Research Department London School of Hygiene and Tropical Medicine, London, United Kingdom<sup>c</sup> Medical Research Council – Uganda Virus Research Institute - London School of Hygiene and Tropical Medicine Uganda Research Unit, Entebbe, Uganda<sup>d</sup> Hospital for Tropical Diseases, Ho Chi Minh City, Viet Nam<sup>e</sup> Centre for Tropical Medicine and Global Health, Nuffield Department of Medicine, University of Oxford, Oxford, United Kingdom<sup>f</sup> Oxford University Clinical Research Unit, Centre for Tropical Medicine, Ho Chi Minh City, Viet Nam

### ARTICLE INFO

#### Keywords:

Brain infection

Meningitis

Optic nerve sheath diameter

Ultrasound

Raised intracranial pressure

### ABSTRACT

Brain infections cause significant morbidity and mortality worldwide, especially in resource-limited settings with high HIV co-infection rates. Raised intracranial pressure [ICP] may complicate brain infection and worsen neurological injury, yet invasive ICP monitoring is often unavailable. Optic nerve sheath diameter [ONSD] ultrasound may allow detection of raised ICP at the bedside; however, pathology in brain infection is different to traumatic brain injury, in which most studies have been performed. The use of ONSD ultrasound has been described in tuberculous meningitis, cryptococcal meningitis and cerebral malaria; however correlation with invasive ICP measurement has not been performed. Normal optic nerve sheath values are not yet established for most populations, and thresholds for clinical intervention cannot be assumed to match those used in non-infective brain pathology. ONSD ultrasound may be suitable for use in resource-limited settings by clinicians with limited ultrasound training. Standardisation of scanning technique, consensus on normal ONSD values, and action on abnormal results, are areas for future research.

This scoping review examines the role of ONSD ultrasound in brain infection. We discuss pathophysiology, and describe the rationale, practicalities, and challenges of utilising ONSD ultrasound for brain infection monitoring and management. We discuss the existing evidence base for this technique, and identify knowledge gaps and future research priorities.

### 1. Background

Over 3 million cases of brain infection occur globally each year, resulting in substantial morbidity and mortality [1–4]. The term ‘brain infection’ encompasses a wide range of pathology. Well recognised pathological subgroups—meningitis, encephalitis and abscesses—may result from infection by bacteria, mycobacteria, viruses, fungi and parasites, and lead to a variety of clinical presentations. Geographical location, co-morbidities and specific exposures may increase risk of certain pathogens. Consideration of host immunity is important; immunocompromised individuals such as those living with human

immunodeficiency virus [HIV] are particularly susceptible to brain infection [5,6]. Cryptococcal meningitis, tuberculous meningitis [TB meningitis] and bacterial meningitis all occur with higher frequency in HIV co-infection [6–8]. Despite roll-out of anti-retroviral therapy, cryptococcal meningitis and TB meningitis, both acquired immunodeficiency syndrome [AIDS]-defining illnesses, remain major causes of death and disability with an estimated 200,000 [2,3] and 100,000 [4] global cases each year, respectively.

Severe brain infection may result in raised intracranial pressure [ICP], and this is highly detrimental to neurological function [9–13]. ICP is not routinely managed in most individuals with brain infection [14].

**Abbreviations:** AIDS, Acquired immunodeficiency syndrome; CSF, Cerebrospinal fluid; HIV, Human immunodeficiency virus; ICP, Intracranial pressure; IQR, Interquartile range; IRIS, Immune reconstitution inflammatory syndrome; LP, Lumbar puncture; MAP, Mean arterial pressure; ONSD, Optic nerve sheath diameter; ROC, Receiver-operator characteristic; TB meningitis, Tuberculous meningitis; TBI, Traumatic brain injury; SD, Standard deviation.

\* Corresponding author.

**E-mail addresses:** [g.a.stead@doctors.org.uk](mailto:g.a.stead@doctors.org.uk) (G.A. Stead), [fiona.cresswell@lshtm.ac.uk](mailto:fiona.cresswell@lshtm.ac.uk) (F.V. Cresswell), [oanhpk@oucr.org](mailto:oanhpk@oucr.org) (P.K.N. Oanh), [gthwaites@oucr.org](mailto:gthwaites@oucr.org) (G.E. Thwaites), [jdonovan@oucr.org](mailto:jdonovan@oucr.org) (J. Donovan).

<https://doi.org/10.1016/j.ensci.2021.100330>

Received 21 December 2020; Accepted 18 February 2021

Available online 22 February 2021

2405-6502/© 2021 The Author(s).

Published by Elsevier B.V. This is an open access article under the CC BY-NC-ND license

(<http://creativecommons.org/licenses/by-nc-nd/4.0/>).

Whether specific treatment of established raised ICP improves outcomes in brain infections is uncertain; with exception of cryptococcal meningitis where early ICP reduction is associated with improved clinical outcomes [15]. Gold standard measurement of ICP requires an invasive intracranial monitoring device, sited in a neurocritical care setting [16–18]; however, this standard is often out of reach in resource-limited settings where cryptococcal meningitis, TB meningitis and cerebral malaria have their greatest burden of disease. A low cost, safe, reliable and easy to learn technique for ICP monitoring has potential for patient benefit. Early recognition of raised ICP, prior to clinical deterioration, may allow targeted brain imaging and use of appropriate therapies to prevent neurological decline. Ultrasound measurement of the optic nerve sheath diameter (ONSD), as a surrogate measurement for ICP, has been the subject of much interest in recent years, with a growing evidence base in non-infective brain pathology [19–21]. However, the value of ONSD ultrasound in brain infection cannot be assumed from non-infective data, given differences in pathology, clinical setting and operator experience.

In this review we examine the role of ONSD ultrasound in brain infection, specifically in cryptococcal meningitis, TB meningitis, cerebral malaria and bacterial meningitis; conditions associated with raised ICP in their severest forms. We discuss pathophysiology of these brain infections, and the rationale and evidence base for using ONSD ultrasound for their monitoring and management, especially in resource-poor settings. We discuss whether ONSD ultrasound can indeed identify raised ICP in brain infection and the potential impact of this bedside tool on patient outcomes. Finally, we describe research gaps relevant to the use of ONSD ultrasound in brain infection and suggest future studies to address these gaps.

We elected to perform a scoping review to identify and map the evidence available for this topic. We searched PubMed and Google Scholar up to 01/06/20 using the search term ‘optic nerve’, and each of the following terms: ‘tuberculous meningitis’, ‘cryptococcal meningitis’, ‘bacterial meningitis’, ‘malaria’, ‘viral encephalitis’, ‘brain infection’. Additionally, a search was performed using the terms ‘optic nerve sheath diameter’ and ‘intracranial pressure’. Using PubMed our search strategy returned 1310 manuscripts. Each was analysed for its relevance to our review. We included manuscripts describing ONSD ultrasound as a proxy for intracranial pressure monitoring, where at least one patient had brain infection. A total of 66 manuscripts, identified through PubMed or Google Scholar, were included in the final review, with the

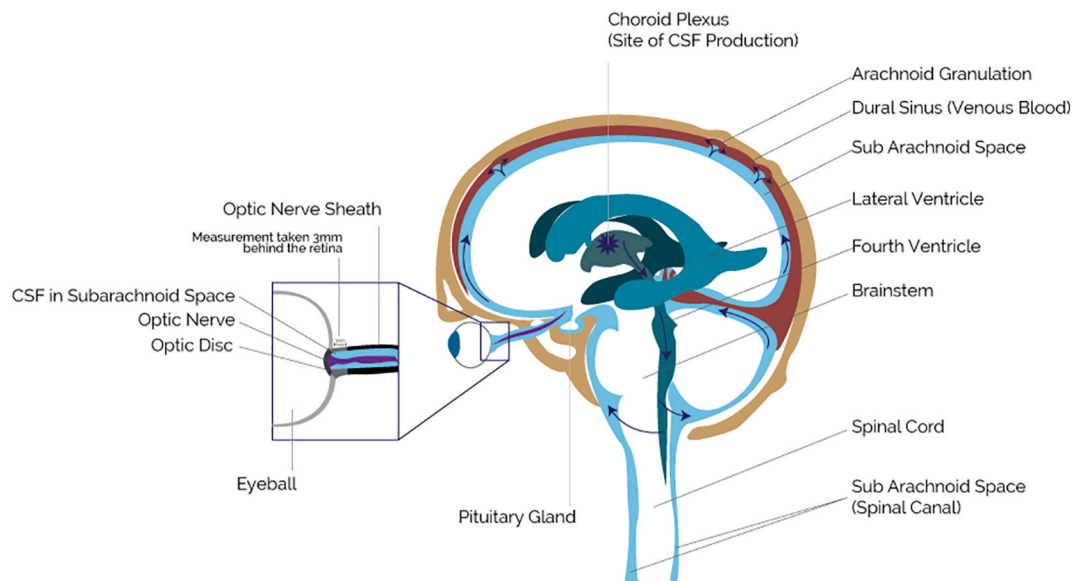
remaining search results rejected.

## 2. Pathophysiology of raised intracranial pressure in brain infection

The skull is a fixed compartment with a constant total volume; changes in one constituent [i.e. brain, cerebrospinal fluid (CSF), blood volume] result in compensatory changes in one or both of the other constituents [22,23]. Changes in brain compartment volume beyond the limits of physiological compensation elevate ICP and reduce cerebral perfusion; cerebral perfusion pressure = mean arterial pressure [MAP] - ICP. Impaired cerebral perfusion results in cerebral ischaemia and infarction. Autoregulation is the process by which cerebral blood flow is regulated and controlled [24]; ensuring cerebral blood flow cannot continue to rise in the face of rising MAP. A sustained rise in ICP impairs autoregulation in bacterial meningitis, with increased cerebral blood flow potentially contributing to raised ICP [25]. Intracranial masses compress the brain compartment, leading to compensatory movement of CSF extracranially to maintain cerebral perfusion. In hydrocephalus, there is impairment of the passage of CSF from its point of production [choroid plexus] to its point of absorption [arachnoid granulations] [26]. [Fig. 1] In non-communicating hydrocephalus, a neurosurgical emergency, CSF cannot exit the ventricular system of the brain, and pressure is exerted on brain tissue.

Brain infection is a heterogeneous group, and the mechanism through which ICP becomes elevated differs across pathologies. Raised ICP in cryptococcal meningitis is common; occurring in up to 50% of patients [27]. Raised ICP in cryptococcal meningitis is typically secondary to a communicating hydrocephalus; the most likely mechanism is of physical blockage of CSF reabsorption from accumulation of cryptococcal organisms and their free lying polysaccharide capsule within the arachnoid granulations [28]. Lumbar CSF opening pressure correlates with higher cryptococcal polysaccharide titres and positive India ink smear microscopy [27], with persistence of CSF culture positivity at 2 weeks [29], and with arachnoid granulation cryptococcus concentrations on electron microscopy and histology [28]. In cryptococcal meningitis a significant proportion of mortality and morbidity, such as loss of vision, is directly related to raised ICP [30].

The pathophysiology of raised ICP in TB meningitis is complex. Hydrocephalus, inflammatory paradoxical reactions, neurological immune reconstitution inflammatory syndrome [IRIS], and cerebral



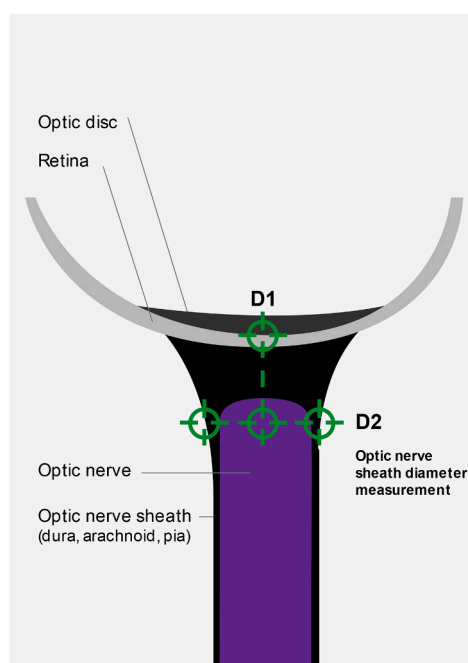
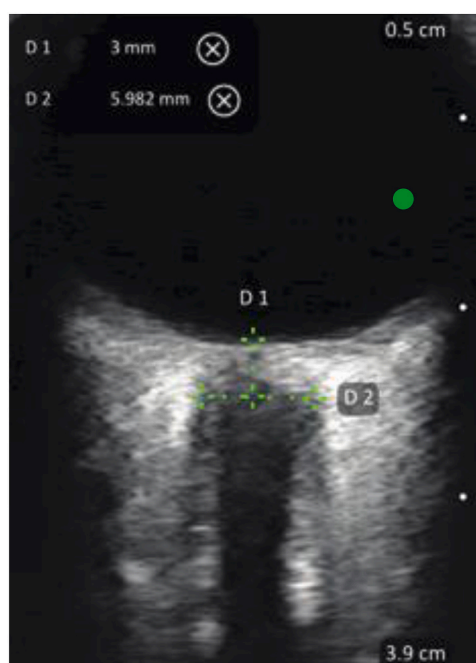
**Fig. 1.** Anatomy of CSF flow relating to optic nerve sheath (Based on an image from the Intracranial Hypertension Research Foundation, with permission). CSF: Cerebrospinal fluid.

oedema can all contribute to raised ICP, with the latter exacerbated by hyponatraemia [31,32]. Raised ICP is common in cerebral malaria especially among children. The mechanism remains uncertain, although sequestration of parasitized erythrocyte cells in the cerebral microvasculature has been suggested [33]. In malaria this sequestration may compromise the blood-brain barrier by causing cytotoxic injury to the vascular endothelium, leading to a combination of extracellular and intracellular oedema. In addition, vasodilation may increase intracerebral blood volume [34]. In bacterial meningitis, raised ICP occurs due to the direct toxic effect of the pathogen combined with host inflammatory response [14]. Vasoactive mediators, inflammatory cytokines, and reactive oxygen species lead to cytotoxic cerebral oedema, venous thrombosis, reduced CSF resorption and failure of autoregulation [14].

### 3. Use of ONSD as a surrogate measure of ICP

Lumbar CSF opening pressure and fundoscopy are frequently used to identify raised estimate ICP, yet each have limitations [35,36]. CSF opening pressure is measured with a manometer during lumbar puncture and may detect raised ICP in a fully communicating subarachnoid system; yet in non-communicating disease lumbar puncture can worsen a pressure gradient and risks fatal tentorial herniation [37]. Changes in ICP are transmitted to the optic nerve sheath, with its CSF-containing subarachnoid space continuous with the subarachnoid space of the brain and spinal cord [38]. When pressure in the CSF compartment is elevated, impaired venous drainage manifests as swelling at the optic disc [papilloedema]. This swelling can be visualised by performing fundoscopy, a technique available for over 100 years [39]. Unfortunately, fundoscopy is challenging to perform without dilating eye drops, measurements are subjective and operator dependent, and papilloedema can take days to develop reducing its value in acute illness [40].

Changes in the optic nerve sheath itself are also measurable and occur acutely when ICP is elevated. Under ultrasound, the optic nerve appears hypoechoic, closely surrounded by echogenic pia mater, hypoechoic subarachnoid space, hyperechoic dura mater, and periorbital fat. ONSD is measured as the space within dura mater on opposite sides of the sheath [41]. [Fig. 2].



**Fig. 2.** Enlarged optic nerve sheath imaged by ultrasound.

This first panel shows an ultrasound image of the optic nerve sheath, and surrounding structures. D1 denotes distance from the retina to the point of optic nerve sheath diameter measurement (3 mm). D2 denotes the measured optic nerve sheath diameter at 3 mm from the retina. In the second panel a corresponding image is shown labelling structures of the eye for direct comparison with the clinical image (first panel).

### 4. ONSD ultrasound as a tool for ICP monitoring in brain infection

Several studies provide an evidence base supporting ONSD ultrasound as a monitoring tool for ICP. Existing primary research is dominated by traumatic brain injury [TBI] and intracerebral haemorrhage, yet these studies have relatively small samples sizes, and vary in their definitions of raised ICP, methods of ONSD scanning, and cut-offs to detect raised ICP [41–44]. Three meta-analyses support an association between increased ONSD and raised ICP, however none included individuals with brain infection [19–21].

#### 4.1. Cryptococcal meningitis

Only one study of ONSD ultrasound in cryptococcal meningitis has been published to date [45]. Nabeta et al. prospectively studied HIV-positive Ugandan adults with advanced HIV [median CD4 count 17 cells/ $\mu$ l], comparing ultrasound-guided ONSD measurements before and after lumbar puncture, with lumbar CSF opening pressures [Table 1]. Mean ONSD significantly correlated with CSF opening pressure, and receiver-operator characteristic [ROC] curve analysis demonstrated ONSD  $\geq$ 5 mm predicted CSF opening pressure > 200 mmHg with 85% sensitivity and 59% specificity.

#### 4.2. TB meningitis

In a study of ONSD ultrasound in TBM, 25 Indian adults with suspected TBM based on consistent brain magnetic resonance imaging [MRI] appearances [ $n = 25$ , mean ONSD 5.81 mm] were compared with a control group where individuals lacked MRI appearances of TBM or papilloedema on fundoscopy [ $n = 120$ , upper limit of normal for ONSD 4.37 mm] [46]. Larger studies are required to further investigate the role of ONSD ultrasound in TBM.

#### 4.3. Cerebral malaria

Beare et al. performed a prospective study of ONSD ultrasound in 112 children [mean age 3 years] with cerebral malaria or severe malaria plus impaired consciousness in Malawi [47]. In this study 49% [55/112]

**Table 1**  
Summary of studies with ONSD cut-off for detecting raised ICP in brain infection.

Study	Patient group	No. of patients	Reference for raised ICP	ONSD cut off [mm]	Sensitivity [%]	Specificity [%]	Country
Nabeta, 2014 [45]	Meningitis, 81% cryptococcal. 4% TB meningitis, 15% other/ unknown. Adult population.	98	CSF pressure by lumbar puncture	5.0	85	59	Uganda
Shirodkar, 2014 [51]	Mixed infective and non-infective pathology. Adult population.	101	CT/MRI	4.6 [F] 4.8 [M]	84.6 [F] 97.4 [M]	100 [F] 100 [M]	India
Rehman, 2018 [52]	Mixed infective and non-infective pathology. Paediatric population.	48	CT/MRI	4–5.4 [<1y / >10y]	100	60–67	Pakistan
Gupta, 2019 [53]	Mixed infective and non-infective pathology. Adult population.	100	CSF pressure by lumbar puncture	6.3	77	92	India
du Toit, 2015 [54]	Mixed meningitis. Adult population.	73	CSF pressure by lumbar puncture	4.8	50	90	South Africa

CSF: Cerebrospinal fluid. CT: Computed tomography. F: Female gender. ICP: Intracranial pressure. M: Male gender. MRI: Magnetic resonance imaging. ONSD: Optic nerve sheath diameter ultrasound. TB: Tuberculosis.

patients had ONSD  $\geq 4.3$  mm [‘raised ONSD’], with these two groups [raised ONSD vs. non-raised ONSD] also having significantly different CSF opening pressures [higher in raised ONSD group], however no difference was seen in mortality between raised ONSD and non-raised ONSD groups; 16%, [9/55] vs. 19% [11/57], respectively. An increase in neurological sequelae was found in children with increased ONSD [15%, 7/46] compared to those without [4%, 2/46],  $p < 0.05$ .

A prospective cross-sectional study carried out by Kofi-Mensa et al. found a significant difference in ONSD between children with unarousable coma due to malaria [ $n = 37$ , mean ONSD 5.09 mm] vs. children without unarousable coma [ $n = 50$ , mean ONSD 3.87 mm] [48]. In this study mean ONSD was higher in children who died [5.70 mm], and in children recovering with neurological sequelae [5.96 mm] vs. in children who recovered without neurological sequelae [4.58 mm]. This suggests ONSD may be able to prognosticate children with cerebral malaria.

#### 4.4. Bacterial meningitis

Studies in bacterial meningitis have shown reduction in ICP and mortality with ICP-guided therapy [49,50]. Whether ONSD can be used to guide ICP-reducing therapies in bacterial meningitis requires further study, especially in resource-limited settings. To date there are no published studies supporting a clinical role for ONSD ultrasound in bacterial meningitis.

### 5. Practicalities and challenges

The strengths and limitations of ONSD ultrasound as a point-of-care technique for ICP monitoring are shown in Table 2. Performing ONSD in brain infection presents challenges. ONSD ultrasound may increasingly be performed outside of intensive care or emergency unit settings, by individuals with less ultrasound experience. Basic training and

**Table 2**  
Strengths and limitations of ONSD ultrasound.

Strengths	Limitations
<ul style="list-style-type: none"> <li>• Safe and non-invasive [55,56]</li> <li>• Point of care bedside test [57]</li> <li>• Quick to perform [58]</li> <li>• Correlation with invasive ICP measurements [41]</li> <li>• Low inter operator variability [59]</li> <li>• Not affected by age in adults, body mass index, head circumference, or blood pressure [60]</li> </ul>	<ul style="list-style-type: none"> <li>• Potentially false positives for raised ICP in Graves orbitopathy, ONS meningiomas, leukaemic infiltration, orbital congestion [59]</li> <li>• Artefact from surrounding collagen tissue can distort optic nerve [61]</li> <li>• Variation in normal range by ethnicity [57,62–64]</li> <li>• Variation in age with children [65]</li> <li>• Minimal guidance for acting on abnormal measurements</li> <li>• May be operator dependent</li> </ul>

ICP: Intracranial pressure. ONS: Optic nerve sheath.

educational material are important to standardise scanning technique, measurement, interpretation, and clinical response, and give a sound understanding of normal and abnormal ultrasound appearances.

ONSD ultrasound requires periods of time spent close to the patient in range of infectious droplets that may be spread by aerosolisation. Individuals with TB meningitis and active pulmonary TB, or with untreated bacterial meningitis, may present an infection risk to the scanning practitioner. Access to infection control guidelines and procedures, personal protective equipment, and suitable isolation for patients need consideration. Guidelines for reducing infection risk in individuals with TB may be difficult to implement in low resource settings [66].

Identification of suspected ICP by ONSD ultrasound requires knowledge of normal ONSD ranges, particularly considering the likelihood that normal ONSD varies by ethnicity. Specific ONSD normal ranges are known for only a few ethnic groups, and expanding these datasets is an area for future study. ONSD variation within a specific country has not yet been described but would confound data comparison further.

### 6. Research gaps and future work

Evidence supporting ONSD ultrasound for the measurement and monitoring of ICP in brain infection is limited. At best, there is correlation between ONSD and other surrogate measurements of raised ICP, such as lumbar CSF opening pressure and fundoscopy; yet studies to date have been small. Data comparing ONSD with invasive ICP measurement in brain infection would be valuable.

The ultimate purpose of detecting ICP changes using ONSD is to intervene and improve patient outcomes. Yet evidence is required to support ICP-guided therapies in brain infections of varying aetiology, and to demonstrate that ONSD can reliably identify that raised ICP. Currently no evidence supports ONSD ultrasound-guided investigations or management in brain infection. No randomised studies have compared ONSD-monitored individuals with those not undergoing ONSD ultrasound. In settings where 3D brain imaging, invasive monitoring, and neurosurgical interventions are unavailable, it is even more unclear how detecting an enlarged ONSD should alter management approach. Benefit of ONSD ultrasound may be limited to specific brain infections. In TB meningitis, where lumbar puncture is not repeated regularly (unlike in cryptococcal meningitis), ONSD ultrasound may have greater value in identifying patients who may benefit from a variety of interventions.

Additionally, ONSD ultrasound requires a standardised approach to both clinical practice and research. Optimal ultrasound probe and patient position are uncertain. A standard scanning technique, a method of repeating and averaging, and an alternate reference standard for raised ICP [when invasive monitoring is not available] would be valuable. A clinical practice guideline as well as an evidence-based approach to managing enlarged ONSD in specific brain infections would be useful.

## 7. Conclusion

Raised ICP is a common complication of brain infection. ONSD ultrasound may represent a novel way to identify raised ICP at the bedside with minimal operator training and low risk to the patient, yet more supporting evidence is required, both of the ability of ONSD ultrasound to reliably identify raised ICP, and of its use in guiding management approaches that improve clinical outcomes. Currently there is no standardised cut-off for diagnosing clinically relevant ICP in brain infection and determining such a cut-off is complicated by differences in normal ONSD among healthy individuals. Studies have been small, and health outcomes are rarely measured. Future work should aim to address these points with a focus on guiding further investigations and management strategies. If a standardised, evidence-based approach can be developed, ONSD ultrasound may be a highly valuable tool in the management of brain infection, especially in low resource settings.

## Ethics approval and consent to participate

Not applicable.

## Consent for publication

Not applicable.

## Availability of data and materials

Not applicable

## Funding

FVC is supported by a Wellcome Clinical PhD Fellowship in Global Health [210772A]. GT and JD are supported by the Wellcome Trust, UK (110179/Z/15/Z).

## Authors' contributions

GS, JD, and FC conceptualized the manuscript. GS, JD, and SJ drafted the manuscript. All authors revised drafts and approved the final submission.

## Declaration of Competing Interest

The authors declare that they have no competing interests.

## Acknowledgements

Emily Satinsky for assisting with final review of the manuscript.  
Emily Martyn for assisting with image collection.  
Clarius for lending a handheld scanner to the Infectious Diseases Institute meningitis clinical research team.  
Daniella Nastri Design for helping with image design.

## References

- [1] GBD, Meningitis collaborators. Global, regional, and national burden of meningitis, 1990–2016: a systematic analysis for the Global Burden of Disease Study 2016, *Lancet Neurol.* 17 (12) (2016) 1061–1082, 2018.
- [2] R. Rajasingham, R.M. Smith, B.J. Park, J.N. Jarvis, N.P. Govender, T.M. Chiller, et al., Global burden of disease of HIV-associated cryptococcal meningitis: an updated analysis, *Lancet Infect Dis* 17 (8) (2017) 873–881.
- [3] T. Bicanic, T.S. Harrison, Cryptococcal meningitis, *Br Med Bull* 72 (2004) 99–118.
- [4] R.J. Wilkinson, U. Rohlwick, U.K. Misra, R. van Crevel, N.T.H. Mai, K.E. Dooley, et al., Tuberculous meningitis, *Nat Rev Neurol* 13 (10) (2017 Oct) 581–598.
- [5] R. Sonnevile, E. Magalhaes, G. Meyfroidt, Central nervous system infections in immunocompromised patients, *Curr Opin Crit Care* 23 (2) (2017 Apr) 128–133.
- [6] J.R. Zunt, Central nervous system infection during immunosuppression, *Neurol Clin* 20 (1) (2002 Feb) 1–22 (v).
- [7] P. Domingo, I. Suarez-Lozano, F. Torres, V. Pomar, E. Ribera, M.J. Galindo, et al., Bacterial meningitis in HIV-1-infected patients in the era of highly active antiretroviral therapy, *JAIDS J Acquir Immune Defic Syndr* 51 (5) (2009 Aug) 582–587.
- [8] K.E.B. van Veen, M.C. Brouwer, A. van der Ende, D. van de Beek, Bacterial meningitis in patients with HIV: a population-based prospective study, *J Infect* 72 (3) (2016 Mar) 362–368.
- [9] S. Tripathy, S.R. Ahmad, Raised intracranial pressure syndrome: a stepwise approach, *Indian J Crit Care Med Peer-Rev Off Publ Indian Soc Crit Care Med.* 23 (Suppl. 2) (2019 Jun) S129–S135.
- [10] J.M.K. Murthy, Management of intracranial pressure in tuberculous meningitis, *Neurocrit Care* 2 (3) (2005 Jun 1) 306–312.
- [11] M. Abassi, D.R. Boulware, J. Rhein, Cryptococcal meningitis: diagnosis and management update, *Curr Trop Med Rep* 2 (2) (2015 Jun 1) 90–99.
- [12] P. Rebaud, J.C. Berthier, E. Hartemann, D. Floret, Intracranial pressure in childhood central nervous system infections, *Intensive Care Med* 14 (5) (1988) 522–525.
- [13] C.R. Newton, F.J. Kirkham, P.A. Winstanley, G. Pasvol, N. Peshu, D.A. Warrell, et al., Intracranial pressure in African children with cerebral malaria, *Lancet Lond Engl* 337 (8741) (1991 Mar 9) 573–576.
- [14] A. Tariq, P. Aguilar-Salinas, R.A. Hanel, N. Naval, M. Chmayssani, The role of ICP monitoring in meningitis, *Neurosurg Focus* 43 (5) (2017 Nov), E7.
- [15] P.G. Pappas, Managing cryptococcal meningitis is about handling the pressure, *Clin Infect Dis Off Publ Infect Dis Soc Am* 40 (3) (2005 Feb 1) 480–482.
- [16] D.S. Nag, S. Sahu, A. Swain, S. Kant, Intracranial pressure monitoring: gold standard and recent innovations, *World J Clin Cases* 7 (13) (2019 Jul 6) 1535.
- [17] P.H. Raboel, J. Bartek, M. Andresen, B.M. Bellander, B. Romner, Intracranial pressure monitoring: invasive versus non-invasive methods—a review [Internet]. Vol. 2012, *Critical Care Research and Practice*. Hindawi; 2012 [cited 2020 Aug 8]. p. e950393, Available from: <https://www.hindawi.com/journals/ccrp/2012/950393/>.
- [18] M.A. Kirkman, M. Smith, Intracranial pressure monitoring, cerebral perfusion pressure estimation, and ICP/CPP-guided therapy: a standard of care or optional extra after brain injury? *Br J Anaesth* 112 (1) (2014 Jan 1) 35–46.
- [19] J. Dubourg, E. Javouhey, T. Geeraerts, M. Messerer, B. Kassai, Ultrasonography of optic nerve sheath diameter for detection of raised intracranial pressure: a systematic review and meta-analysis, *Intensive Care Med* 37 (7) (2011 Jul) 1059–1068.
- [20] C. Robba, G. Santori, M. Czosnyka, F. Corradi, N. Bragazzi, L. Padayachy, et al., Optic nerve sheath diameter measured sonographically as non-invasive estimator of intracranial pressure: a systematic review and meta-analysis, *Intensive Care Med* 44 (8) (2018) 1284–1294.
- [21] A. Koziarz, N. Sne, F. Kegel, S. Nath, J.H. Badhiwala, F. Nassiri, et al., Bedside optic nerve ultrasonography for diagnosing increased intracranial pressure: a systematic review and meta-analysis, *Ann Intern Med* 171 (12) (2019 Dec 17) 896–905.
- [22] G. Kellie, An account of the appearances observed in the dissection of two of three individuals presumed to have perished in the storm of the 3d, and whose bodies were discovered in the vicinity of Leith on the morning of the 4th, November 1821; with some reflection, *Trans Medico-Chir Soc Edinb* 1 (1824) 84–122.
- [23] N. Lundberg, The Saga of the Monro-Kellie Doctrine, in: *Intracranial Pressure*. V. Berlin, Springer Berlin Heidelberg, Heidelberg, 1983, pp. 68–76.
- [24] W.M. Armstead, Cerebral blood flow autoregulation and Dysautoregulation, *Anesthesiol Clin* 34 (3) (2016 Sep) 465.
- [25] K.M. Fs L, J.Q. Jh W, Gm K, Ie G, et al., Dependency of cerebral blood flow on mean arterial pressure in patients with acute bacterial meningitis, *Crit Care Med* 28 (4) (2000 Apr 1) 1027–1032.
- [26] H.L. ReKate, The definition and classification of hydrocephalus: a personal recommendation to stimulate debate, *Cerebrospinal Fluid Res* 5 (2008 Jan 22) 2.
- [27] J.R. Graybill, J. Sobel, M. Saag, C. van der Horst, W. Powderly, G. Cloud, et al., Diagnosis and management of increased intracranial pressure in patients with AIDS and cryptococcal meningitis, *Clin Infect Dis* 30 (1) (2000 Jan 1) 47–54.
- [28] A. Loyse, H. Wainwright, J.N. Jarvis, T. Bicanic, K. Rebe, G. Meintjes, et al., Histopathology of the arachnoid granulations and brain in HIV-associated cryptococcal meningitis: correlation with cerebrospinal fluid pressure, *AIDS Lond Engl* 24 (3) (2010 Jan 28) 405–410.
- [29] M.A. Rolfes, J. Rhein, C. Schutz, K. Taseera, H.W. Nabeta, K. Huppler Hullsiek, et al., Cerebrospinal fluid culture positivity and clinical outcomes after amphotericin-based induction therapy for cryptococcal meningitis, *Open Forum Infect Dis* 2 (4) (2015 Dec) ofv157.
- [30] H.-Y. Sun, C.-C. Hung, S.-C. Chang, Management of cryptococcal meningitis with extremely high intracranial pressure in HIV-infected patients, *Clin Infect Dis* 38 (12) (2004 Jun 15) 1790–1792.
- [31] U.K. Misra, J. Kalita, S.K. Bhoi, R.K. Singh, A study of hyponatremia in tuberculous meningitis, *J Neuro Sci* 367 (2016 Aug 15) 152–157.
- [32] J. Donovan, A. Figaji, D. Imran, N.H. Phu, U. Rohlwick, G.E. Thwaites, The neurocritical care of tuberculous meningitis, *Lancet Neurol* 17 (2019 May) 0(0).
- [33] N.A.V. Beare, S.J. Glover, S. Lewallen, T.E. Taylor, S.P. Harding, M.E. Molyneux, Prevalence of raised intracranial pressure in cerebral malaria detected by optic nerve sheath ultrasound, *Am J Trop Med Hyg* 87 (6) (2012 Dec) 985–988.
- [34] R. Idro, K. Marsh, C.C. John, C.R. Newton, Cerebral malaria; mechanisms of brain injury and strategies for improved neuro-cognitive outcome, *Pediatr Res* 68 (4) (2010 Oct) 267–274.
- [35] C.M. Doherty, R.B. Forbes, Diagnostic lumbar puncture, *Ulster Med J* 83 (2) (2014 May) 93–102.

- [36] H. Steffen, B. Eifert, A. Aschoff, G.H. Kolling, H.E. Völcker, The diagnostic value of optic disc evaluation in acute elevated intracranial pressure, *Ophthalmology*. 103 (8) (1996 Aug) 1229–1232.
- [37] D.J. Gower, A.L. Baker, W.O. Bell, M.R. Ball, Contraindications to lumbar puncture as defined by computed cranial tomography, *J Neurol Neurosurg Psychiatry* 50 (8) (1987 Aug 1) 1071–1074.
- [38] N. Mukherjee, M.A. El-Dairi, M.T. Bhatti, Optic nerve sheath fenestration—indications and techniques, *US Ophthalmic Rev* 06 (02) (2013) 125.
- [39] **Ophthalmoscope [Internet], [cited 2020 Aug 1]. Available from:** <http://www.mrcophth.com/Historyofophthalmology/ophthalmoscope.html>.
- [40] M. Rigi, S.J. Almarzouqi, M.L. Morgan, A.G. Lee, Papilledema: epidemiology, etiology, and clinical management, *Eye Brain* 7 (2015) 47–57.
- [41] T. Geeraerts, S. Merceron, D. Benhamou, B. Vigué, J. Duranteau, Non-invasive assessment of intracranial pressure using ocular sonography in neurocritical care patients, *Intensive Care Med* 34 (11) (2008 Nov) 2062–2067.
- [42] K. Munawar, M.T. Khan, S.W. Hussain, A. Qadeer, Z.S. Shad, S. Bano, et al., Optic nerve sheath diameter correlation with elevated intracranial pressure determined via ultrasound, *Cureus*. 11 (2) (2019 Feb 27), e4145.
- [43] J. Wang, K. Li, H. Li, C. Ji, Z. Wu, H. Chen, et al., Ultrasonographic optic nerve sheath diameter correlation with ICP and accuracy as a tool for noninvasive surrogate ICP measurement in patients with decompressive craniotomy, *J Neurosurg* 19 (2019 Jul) 1–7.
- [44] J.P. Jeon, S.U. Lee, S.-E. Kim, S.H. Kang, J.S. Yang, H.J. Choi, et al., Correlation of optic nerve sheath diameter with directly measured intracranial pressure in Korean adults using bedside ultrasonography, *PLoS One* 12 (9) (2017), e0183170.
- [45] H.W. Nabeta, N.C. Bahr, J. Rhein, N. Fosslund, A.N. Kiragga, D.B. Meya, et al., Accuracy of noninvasive intraocular pressure or optic nerve sheath diameter measurements for predicting elevated intracranial pressure in cryptococcal meningitis, *Open Forum Infect Dis*. 1 (3) (2014 Dec) ofu093.
- [46] S. Sangani, S. Parikh, Can sonographic measurement of optic nerve sheath diameter be used to detect raised intracranial pressure in patients with tuberculous meningitis? A prospective observational study, *Indian J Radiol Imaging* 25 (2) (2015) 173.
- [47] N.A.V. Beare, S.J. Glover, S. Lewallen, T.E. Taylor, S.P. Harding, M.E. Molyneux, Prevalence of raised intracranial pressure in cerebral malaria detected by optic nerve sheath ultrasound, *Am J Trop Med Hyg* 87 (6) (2012 Dec) 985–988.
- [48] K.-M.S. de Tové, Y.S. de Tové-Sissinto, D.J. Adedemy, D.W.M.M. Akanni, M. Kiki, P. Yékpè Ahouansou, et al., Sonographic Measurement of Optic Nerve Sheath Diameter: A Prognostic Tool for Childhood Cerebral Malaria. *OJRad*, March 2019.
- [49] P.-O. Grände, E.B. Myhre, C.-H. Nordström, S. Schliamsner, Treatment of intracranial hypertension and aspects on lumbar dural puncture in severe bacterial meningitis, *Acta Anaesthesiol Scand* 46 (3) (2002 Mar) 264–270.
- [50] M. Glimåker, B. Johansson, H. Halldorsdottir, M. Wanecek, A. Elmi-Terander, P. H. Ghatan, et al., Neuro-intensive treatment targeting intracranial hypertension improves outcome in severe bacterial meningitis: an intervention-control study, *PLoS One*. 9 (3) (2014), e91976.
- [51] C.G. Shirodkar, S.M. Rao, D.P. Mutkule, Y.R. Harde, P.M. Venkateswara, M. U. Mahesh, Optic nerve sheath diameter as a marker for evaluation and prognostication of intracranial pressure in Indian patients: an observational study, *Indian J Crit Care Med Peer-Rev Off Publ Indian Soc Crit Care Med* 18 (11) (2014 Nov) 728–734.
- [52] N.U. Rehman Siddiqui, A. Haque, Q. Abbas, H. Jurair, B. Salam, R. Sayani, Ultrasonographic optic nerve sheath diameter measurement for raised intracranial pressure in a tertiary care centre of a developing country, *J Ayub Med Coll Abbottabad JAMC* 30 (4) (2018 Dec) 495–500.
- [53] S. Gupta, A. Pachisia, Ultrasound-measured optic nerve sheath diameter correlates well with cerebrospinal fluid pressure, *Neurol India* 67 (3) (2019 Jun) 772–776.
- [54] G.J. du Toit, D. Hurter, M. Nel, How accurate is ultrasound of the optic nerve sheath diameter performed by inexperienced operators to exclude raised intracranial pressure? *South Afr J Radiol* 19 (1) (2015 Aug 7) 5.
- [55] H.H. Kimberly, S. Shah, K. Marill, V. Noble, Correlation of optic nerve sheath diameter with direct measurement of intracranial pressure, *Acad Emerg Med* 15 (2) (2008 Feb) 201–204.
- [56] J. Bäuerle, P. Lochner, M. Kaps, M. Nedelmann, Intra- and interobserver reliability of sonographic assessment of the optic nerve sheath diameter in healthy adults, *J Neuroimaging Off J Am Soc Neuroimaging* 22 (1) (2012 Jan) 42–45.
- [57] S.A. Ballantyne, G. O'Neill, R. Hamilton, A.S. Hollman, Observer variation in the sonographic measurement of optic nerve sheath diameter in normal adults, *Eur J Ultrasound Off J Eur Fed Soc Ultrasound Med Biol* 15 (3) (2002 Oct) 145–149.
- [58] L. Wang, L. Feng, Y. Yao, Y. Wang, Y. Chen, J. Feng, et al., Optimal optic nerve sheath diameter threshold for the identification of elevated opening pressure on lumbar puncture in a Chinese population, *PLoS One*. 10 (2) (2015), e0117939.
- [59] N. Rosa, M. De Bernardo, Ultrasound assessment of optic nerve sheath diameter in healthy volunteers, *J Crit Care* 40 (2017) 279.
- [60] Betcher J, Becker TK, Stoyanoff P, Cranford J, Theyyuni N. Military trainees can accurately measure optic nerve sheath diameter after a brief training session. *Mil Med Res [Internet]*. 2018 Dec 20 [cited 2020 Apr 24];5. Available from: <http://www.ncbi.nlm.nih.gov/pmc/articles/PMC6300875/>.
- [61] A. Ozgen, M. Ariyurek, Normative measurements of orbital structures using CT, *AJR Am J Roentgenol* 170 (4) (1998 Apr) 1093–1096.
- [62] I. Anas, Transorbital sonographic measurement of normal optic sheath nerve diameter in nigerian adult population, *Malays J Med Sci MJMS* 21 (5) (2014 Oct) 24–29.
- [63] P. Goeres, F.A. Zeiler, B. Unger, D. Karakitsos, L.M. Gillman, Ultrasound assessment of optic nerve sheath diameter in healthy volunteers, *J Crit Care* 31 (1) (2016 Feb) 168–171.
- [64] R.R. Maude, M.A. Hossain, M.U. Hassan, S. Osbourne, K.L.A. Sayeed, M.R. Karim, et al., Transorbital sonographic evaluation of Normal optic nerve sheath diameter in healthy volunteers in Bangladesh, *PLOS ONE* 8 (12) (2013 Dec 2), e81013.
- [65] J. Ballantyne, A.S. Hollman, R. Hamilton, M.S. Bradnam, R. Carachi, D.G. Young, et al., Transorbital optic nerve sheath ultrasonography in normal children, *Clin Radiol* 54 (11) (1999 Nov) 740–742.
- [66] **Recommendations, Tuberculosis, Guidance, NICE [Internet]. [cited 2020 Mar 10], Available from:** <https://www.nice.org.uk/guidance/ng33/chapter/Recommendations#infection-control>.