

POTENTIAL PROTECTIVE EFFECT OF APOCYNIN IN ETHYLENE GLYCOL-INDUCED HEPATIC DAMAGE BY ATTENUATION OF MITOCHONDRIAL OXIDATIVE STRESS

SUMEETA KUMARI, MINU SHARMA, SINGLA SK*

Department of Biochemistry, Panjab University, Chandigarh, India. Email: singla.biochem@gmail.com

Received: 13 October 2015, Revised and Accepted: 31 October 2015

ABSTRACT

Objective: The present study was carried out to investigate the protective role of apocynin (APO), an nicotinamide adenine dinucleotide phosphate oxidase inhibitor, against ethylene glycol (EG)-induced hepatotoxicity in rats.

Methods: Male Sprague-Dawley rats were divided into three groups with six animals in each group. Control group; EG group, in which hyperoxaluria was induced by 0.4% EG in drinking water for 9 days; and EG+APO group, 0.4% EG in drinking water for 9 days along with APO at a dosage of 200 mg/kg body weight/day, intraperitoneal. All the experimental animals were sacrificed on day 10. Serum and the liver homogenates were analyzed for various biochemical parameters. Mitochondria from liver were isolated by differential centrifugation and were diagnosed for vital biochemical parameters.

Results: Hyperoxaluric animals have shown significantly increased levels of serum glutamic oxaloacetic transaminase, serum glutamic pyruvic transaminase, alkaline phosphatase, and lactate dehydrogenase, thus suggesting liver dysfunction. Declined activities of respiratory chain enzymes showed mitochondrial dysfunction in EG treated rats. In addition, mitochondrial oxidative stress was evident by decreased levels of superoxide dismutase, reduced glutathione, and an increased lipid peroxidation (LPO). APO (200 mg/kg/day), significantly decreased EG-induced oxidative stress by reducing LPO and restoring antioxidant enzymes activities in liver tissue. Also, reduction in the impairment of liver mitochondria functioning was detected in APO treated rats. Histological analysis depicted that APO treatment decreased liver epithelial damage, increased Kupffer cells, and restored normal hepatocyte morphology.

Conclusion: The results demonstrated the potential beneficial effects of APO in reducing EG-induced liver damage that might be through attenuation of mitochondrial oxidative stress.

Keywords: Ethylene glycol, Liver, Oxidative stress, Mitochondrion, Apocynin, Antioxidant.

INTRODUCTION

Ethylene glycol (EG), an important organic solvent, frequently used as the primary ingredient of automobile antifreeze and hydraulic brake fluids [1], is a widely used chemical that is capable of causing remarkable injury if ingested [2]. EG is filtered by the renal glomeruli and is passively reabsorbed. However, a major part of EG is metabolized through the liver (80%) with a short half-life of 3-8 hrs, and its metabolites are in fact dangerous [3]. The metabolites are cell toxins that suppress the oxidative metabolism leading to central nervous system depression, and cardio-pulmonary, hepatic and renal failure [4]. The liver and kidney are the primary site of metabolism for EG. It has in itself a slight toxicity, but is *in vivo* broken down via the liver enzyme alcohol dehydrogenase to four metabolites: Glycoaldehyde, glycolic acid, glyoxylic acid and oxalic acid [5]. Studies in our lab have demonstrated that EG ingestion causes renal injury and nephrolithiasis [6-8]. Furthermore, the systemic response of kidney injury to liver dysfunction is a well-known fact [4]. Previous studies suggested the involvement of oxidative stress in EG hepatotoxicity, as a result of either excess generation of reactive oxygen species (ROS), and/or reduced antioxidant defenses. The foremost sites of physiological ROS generation are nicotinamide adenine dinucleotide phosphate (NADPH) oxidase (NOX) and mitochondria in liver [9]. NOX arbitrates oxidative stress in hepatic injury [10]. Mitochondrial respiratory chain complex I was shown to be inactivated by NOX [11]. NOX, a multisubunit complex consisting of membrane-associated gp91phox and p22phox and cytosolic subunits with p47phox, p67phox, and p40phox, etc., causes the production of superoxide anion, an originator of ROS [12]. Among the seven NOX homologs established in mammals (NOX1, NOX2, NOX3, NOX4, NOX5, DUOX1, and DUOX2), the main ROS-producing NOXs in the liver are NOX1, NOX2, and NOX4 [13]. Most if not all pathogenic insults in the liver can cause oxidative stress, inducing lipid peroxidation (LPO),

protein oxidation, and DNA damage, leading to hepatocyte mitochondrial dysfunction, amplifying inflammation and initiating fibrosis [14,15].

There are numerous antioxidants that play a role to scavenge ROS resulting from both exogenous and endogenous sources [16]. Apocynin (APO) (4-hydroxy-3-methoxy acetophenone or acetovanillone) is the finest known antioxidant and an inhibitor of NOX, so as to prevent the configuration of superoxide radical anions [17,18]. The mechanism of inhibition is not completely known, but involves the impairment of the translocation to the membrane of the cytosolic component p47phox of the NOX complex and found to block the association of p47phox with membrane-bound p22phox subunit of the NOX complex [19]. Its widespread antioxidative stress actions in the liver in different models have been well-documented by several studies. It has been shown to be protective in hepatic ischemia/reperfusion injury [20], hypercholesterolemia-induced hepatic oxidative burden and injury [21], hemorrhagic shock-induced liver injury [22], lipopolysaccharide-induced hepatic injury [23], hydrophobic bile salt-induced hepatocyte shrinkage [24], isoproterenol-induced myocardial injury and fibrogenesis [12], and melamine-related nephrolithiasis [25]. However, few studies have been able, thus far, to demonstrate the effects of APO in hyperoxaluria-induced hepatotoxicity model. Hence, the present study was designed to evaluate the potential protective effect of APO against EG-induced hepatotoxicity in male SD rats. This is the first study in which effect of an NOX inhibitor was evaluated in EG-induced liver toxicity.

METHODS

Chemicals

All the chemicals used in the study were of analytical grade and purchased from Sigma Chemical Co. (St. Louis, MO, USA), Merck

(Mumbai, Maharashtra, India) and Sisco Research Laboratories Pvt. Ltd. (Mumbai, India). APO was acquired from Sigma Laboratories Pvt. Ltd. (Mumbai, India). Kits for creatinine, alkaline phosphatase (ALP), serum glutamic oxaloacetic transaminase (SGOT), serum glutamic pyruvic transaminase (SGPT), urea, and lactate dehydrogenase (LDH) estimation were obtained from ERBA Diagnostics Mannheim GmbH (Mannheim/Germany).

Animal model

The rat's experimental protocols were approved by the Institutional Animal Ethics Committee and were in accordance with the Guidelines for Humane Use and Care of Laboratory Animals. 18 male SD rats (200±20 g) of equivalent age were procured from the central animal house of Panjab University, Chandigarh, India. The rats were housed in an animal house unit (temperature 21-23°C and 50-60% relative humidity), fed a standard chow diet and water *ad-libitum* was used. All rats were acclimatized to the local vivarium before starting the experiment and arbitrarily divided into three groups consist of six rats in each group.

Experimental design

The rats were randomly segregated into following three groups.

Control group: Rats were given an intraperitoneal injection of normal saline.

EG group: Rats received 0.4% EG in drinking water for 9 days.

EG+APO group: Rats received 0.4% EG in drinking water and APO 200 mg/kg/day, i.p. for 9 days.

Food and water consumption was regularly monitored. Rats were sacrificed on day 10.

Sample collection

Blood samples were collected in clean centrifuge tubes, by puncturing inferior vena cava under anesthesia and allowed to clot for 1 hr. Serum was separated as a supernatant after centrifugation at 2000 × g for 15 minutes.

Biochemical assays in serum

Serum SGOT and SGPT, urea, creatinine, LDH, and ALP levels were estimated by commercially available kits (Erba diagnostic, Manheim, Germany) as per manufacturer's instructions.

Measurement of oxidant/antioxidant status in liver tissue

LPO in liver was estimated by the thiobarbituric acid reaction with the malondialdehyde (MDA), a product formed due to peroxidation of lipids by the method of Wills [26]. Catalase (CAT) activity was determined by the UV spectrophotometer method described by CAT [27]. The assay for superoxide dismutase (SOD) was performed according to the method of Kono [28].

Mitochondrial parameters

Isolation of mitochondria

The liver was washed in saline at 4°C, weighed, and homogenized in a Potter/Elvehjem homogenizer, (10 % w/v) in buffer containing 0.25 M sucrose, 5 mM HEPES, 1 mM EDTA, and 0.1% bovine serum albumin pH 7.2. The whole homogenate was centrifuged at 1000 × g for 5 minutes to remove the nuclear fraction and cell debris. Mitochondrial pellet was obtained by centrifuging the post-nuclear supernatant at 14,000 × g for 20 minutes mitochondrial pellet was washed thrice with 1.15% potassium chloride solution and finally suspended in 0.25 M sucrose solution. All operations were performed at 4°C [8]. The mitochondrial fractions obtained were used for the following biochemical studies.

Estimation of mitochondrial oxidative stress and antioxidant status

MDA, a measure of LPO and manganese-SOD (MnSOD) activities

were assayed in mitochondrial preparation, as described earlier in section 2.6. Reduced glutathione (GSH) content was quantified according to the method described by Ellman *et al.* [29].

Mitochondrial respiratory chain complexes

Nicotinamide adenine dinucleotide dehydrogenase activity was measured spectrophotometrically as described by King and Howard [30]. The activity of succinate dehydrogenase was assayed by following the method described by King *et al.* [31]. Mitochondrial cytochrome oxidase was assayed according to Sottocasa *et al.* [32].

Histopathological studies

The liver was removed, and its transverse sections were fixed in 10% buffered formalin solution (pH 7). Fixed liver specimens were embedded in paraffin, sectioned in 4 µm thickness, and stained with Hematoxylin and Eosin (H and E) for the evaluation of liver injury, viewed under polarized light using Leica DM3000 light microscope.

Statistical analysis

The results are shown as mean±standard deviation, measured for six rats in each group. The differences among the control and experimental groups were determined by one-way ANOVA followed by Tukey's *post-hoc* analysis and p<0.05 was considered significant.

RESULTS

Evaluation of liver functioning

Analysis of serum markers of liver functions (SGOT, SGPT, LDH, and ALP) are shown in Table 1. EG exposure to rats resulted in considerably elevated SGOT, SGPT, LDH, and ALP levels. The treatment of APO significantly normalized these atypical parameters.

Evaluation of renal functioning

The urea and creatinine content in the serum of EG treated rats increased significantly (p<0.001) in comparison to control rats. However, administration of APO reduced the unusual levels in serum (Table 1).

Liver oxidative stress and antioxidant status

LPO in the liver tissue was increased significantly after EG exposure (Table 2). MDA status in this group was found to increase by 70%. After treatment with APO, a decrease in MDA status was observed as compared to EG exposed rats. As a result of EG exposure, the activity of antioxidant enzymes SOD and CAT in the liver tissue were significantly reduced (p<0.001) as compared to control group animals (Table 2). The increase in antioxidant enzymes activity was observed after APO supplementation in EG+APO rats when compared to EG group.

Mitochondrial oxidative stress and antioxidant status

Mitochondrial LPO was used as an index of mitochondrial oxidative stress. Induction of hepatotoxicity leads to a significant increase (p<0.01), by 64%, in mitochondrial LPO of EG treated rats as compared to control rats (Fig. 1). APO treatment significantly (p<0.01) decreased mitochondrial LPO by 29%. The activities of antioxidant enzymes, i.e., SOD, reduced GSH were decreased significantly (p<0.01) in EG rats as compared to control rats. However, supplementation of APO increased the activities of antioxidant enzymes in mitochondria of hyperoxaluric rats (Fig. 1).

Mitochondrial respiratory chain complexes

A significant reduction (p<0.01) in the activities of respiratory chain complexes was observed in EG animals. Administration of APO significantly (p<0.01) increased the activities of these enzymes in liver mitochondria of hyperoxaluric rats (Table 3).

Histological analysis

Liver histology of control rats showed portal triads and normal arrangement of hepatocyte with nuclei in between the rows of the hepatocyte, sinusoids have been observed. These sinusoids contain

Table 1: Effect of APO on serum SGOT, SGPT, LDH, ALP, urea, and creatinine levels in rats exposed to EG

Biochemical parameters	Control group	EG group	EG+APO group
SGOT (IU/L)	130.57±17.11	194.35±9.05***	148.40±16.82##
SGPT (IU/L)	73.24±9.31	127.18±10.19***	82.08±11.28###
LDH (IU/L)	1650.42±106.86	2608.38±113.50***	1851.21±87.66###
ALP (IU/L)	165.94±28.23	369.87±34.91***	219.75±50.54##
Urea (mg/dl)	68.13±17.47	128.54±14.03***	78.46±8.03##
Creatinine (mg/dl)	0.88±0.31	2.14±0.33**	1.22±0.28#

Values are expressed as mean±SD; n=6. *p<0.05, **p<0.01, ***p<0.001 indicates significant change in comparison to control. #p<0.05, ##p<0.01, ###p<0.001 indicates significant change between EG and EG+APO. SGOT: Serum glutamic oxaloacetic transaminase, SGPT: Serum glutamic pyruvic transaminase, LDH: Lactate dehydrogenase, ALP: Alkaline phosphatase, EG: Ethylene glycol, SD: Standard deviation, APO: Apocynin

Table 2: Effect of APO on LPO, SOD, and CAT levels in the liver of rats exposed to EG

Oxidative stress parameters	Control group	EG group	EG+APO group
LPO (μ mol MDA/min/mg protein)	0.17±0.05	0.29±0.03**	0.18±0.04#
SOD (U/mg protein)	22.96±5.68	8.28±2.11**	18.13±4.26#
CAT (U/mg protein)	644.40±69.88	250.11±41.56***	515.22±58.00###

Values are expressed as mean±SD; n=6. *p<0.05, **p<0.01, ***p<0.001 indicates significant change in comparison to control. #p<0.05, ##p<0.01, ###p<0.001 indicates significant change between EG and EG+APO. APO: Apocynin, LPO: Lipid peroxidation, SOD: Superoxide dismutase, CAT: Catalase, EG: Ethylene glycol, MDA: Malondialdehyde, SD: Standard deviation

Table 3: Effect of APO on mitochondrial respiratory chain complexes in the rats exposed to EG

Respiratory chain complexes	Control group	EG group	EG+APO group
Complex I (nmol NADH oxidized/min/mg protein)	447.23±29.37	165.42±27.97***	396.64±49.90###
Complex II (nmol succinate oxidized/min/mg protein)	335.22±24.30	188.41±33.96**	277.83±35.52#
Complex IV (nmol cyt.c oxidized/min/mg protein)	0.39±0.09	0.21±0.06*	0.38±0.04#

Values are expressed as mean±SD; n=6. *p<0.05, **p<0.01, ***p<0.001 indicates significant change in comparison to control. #p<0.05, ##p<0.01, ###p<0.001 indicates significant change between EG and EG+APO. APO: Apocynin, EG: Ethylene glycol, NADH: Nicotinamide adenine dinucleotide, SD: Standard deviation

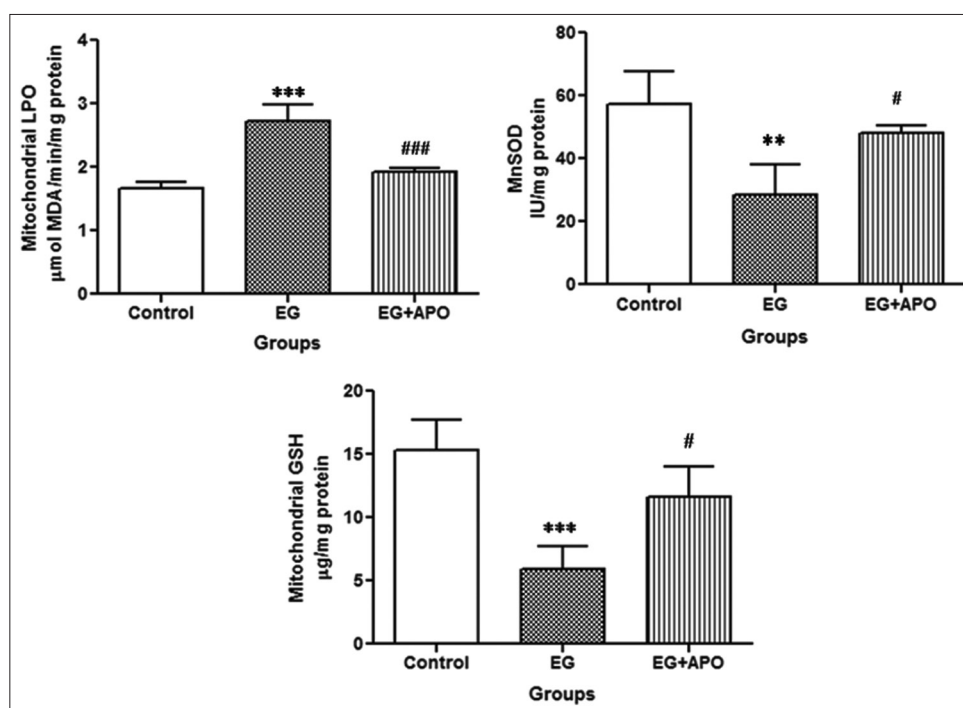


Fig. 1: Effect of apocynin (APO) on liver mitochondrial lipid peroxidation, manganese-superoxide dismutase, and reduced glutathione. Values are expressed as mean±SD; n=6. *p<0.05, **p<0.01, *p<0.001 indicates significant change in comparison to control. #p<0.05, ##p<0.01, ###p<0.001 indicates significant change between ethylene glycol (EG) and EG+APO**

normal Kupffer cells (Fig. 2a). Whereas rats exposed to EG showed cellular swelling with compressed sinusoids. EG treatment resulted in increased Kupffer cells (Fig. 2b). This may be due to oxidative stress created by EG as Kupffer cells are the defensive cells of the liver.

Hemolysis was observed due to damage of blood vessels present in between the sinusoids. However, histological analysis of APO treated hyperoxaluric rats showed less compressed sinusoids, decrease in the number of Kupffer cells as compared to EG rats and also decreased

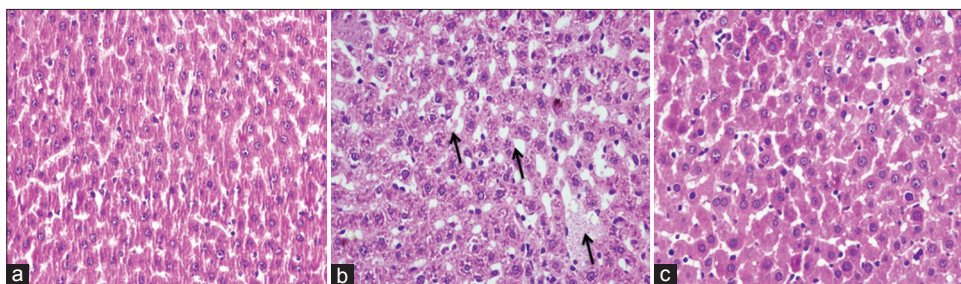


Fig. 2: Liver histological analysis, stained with hematoxylin and eosin. (a) Control group, (b) Ethylene glycol (EG) group, and (c) EG+APO group (Original magnifications $\times 100$). Arrows indicate cellular swelling with compressed sinusoids. APO: Apocynin

cellular swelling (Fig. 2c).

DISCUSSION

This is a novel study, in which we have investigated the effect of APO on EG-induced hepatotoxicity. APO (200 mg/kg/day) effectively attenuated the toxic effects of EG in liver tissue. Administration of EG in our study significantly augmented serum levels of SGOT and SGPT in EG treated rats. These results are in agreement with preceding studies by Kumar *et al.* and Kim *et al.* which revealed that the elevated levels of these enzymes are indicative of cellular leakage and failure in the functional integrity of cell membranes in liver [33,34]. However, APO administration decreased the activities of these enzymes in serum, showing the stabilization of the plasma membranes with the repair of the damaged hepatic tissue. Serum ALP and LDH have also raised in EG treated rats. ALP is excreted via bile by the liver. In liver damage caused by EG, there is reduced secretion of bile which is reflected in the augmented level of ALP in the serum. Similar results were found by Sharma and Sharma [35]. However, a study by Singh *et al.* [36], on the effect of verbenalin in experimental liver damage in rodents, have shown results similar to our study. LDH is also a vital biochemical marker of cellular damage. Free radical arbitrated membrane damage could release LDH into the cytosol and prevention of free radical formation via APO avoids the release of LDH. However, supplementation of APO to EG exposed rats improved the liver functions significantly. Earlier parallel results were found by Zuo *et al.* [22] which have shown the protective effects of APO on liver injury.

In the current investigation, the level of MDA, which is an indirect manifestation of LPO, was found to be significantly elevated with EG exposure. So, it can be suggested that EG is injurious to liver tissue, and the injury is caused by the production of reactive free radicals. APO decreases the generation of free radicals responsible for the LPO and thus decreases the level of MDA, the end product of peroxidation. The result was also observed in the earlier study, where an LPO level was elevated due to hyperoxaluria in liver [37].

Our results revealed that EG exposure decreased SOD and catalase activity, which was significantly restored by APO. These results corroborate findings from the experimental studies by Bijarnia *et al.* [7,37]. Accordingly, APO treatment strengthened the antioxidative defense system with an increased activity of SOD and CAT.

Elevated urea and creatinine levels in serum indicated a diminished renal function in hyperoxaluric condition. The results are in line with previous studies where urea and creatinine levels in serum were elevated due to EG exposure [38]. Following the APO treatment, urea and creatinine levels were reduced as compared to EG rats. As the kidneys become impaired due to any cause, the urea and creatinine levels in the blood will rise due to their poor clearance by the kidneys.

The mitochondrion is considered as the major source of ROS production which leads to the generation of oxidative stress [39]. Many previous studies found a reduction in the activities of complexes-I, II, and IV leading to ATP depletion in animal models of many diseases [40,41].

Such metabolic stress could cause cell damage by increasing the production of ROS and increased oxidative stress in EG treated rats. Oxidation of mitochondrial protein through ROS has been found to affect the ATP synthase and respiratory chain enzymes [42,43]. These results suggest that the administration of EG affected not only respiratory chain complexes but also other vital components involved in normal mitochondrial functioning. Therefore, mitochondrial dysfunction may play an imperative role in the excessive production of ROS, which might result in LPO [44]. Similar results were found in a previous study which demonstrated that the presence of EG is associated with an enhancement in superoxide anion and hydroperoxides generation in EG rats [8]. Mitochondrial GSH pool is most decisive in preserving mitochondrial structure and function [45]. GSH depletion could lead to an oxidative stress condition which in this study is supported by the presence of increased levels of MDA concentration in GSH depleted mitochondrial fractions in EG rats. APO might sustain mitochondrial GSH, which might play a key role in the protection of mitochondrial components against hyperoxaluria-induced oxidative damage. Mn-SOD is considered as the first line of defense in mitochondria against ROS. A decrease in the activity of Mn-SOD can be attributed to the harmful effects of free radicals generated on EG administration. Similar results were found in a study by Sharma *et al.* [8]. APO was able to ameliorate this antioxidant system significantly by its antioxidant potential thereby improving mitochondrial liver functions.

CONCLUSION

The present study described successfully the therapeutic potential of APO, a natural non-toxic compound, in the prevention of EG-induced liver damage. Results suggested that the APO up-regulated the activities of antioxidant enzymes and decreased the level of LPO in the hepatic tissue. In addition, the study showed the potential of APO in preventing EG-induced mitochondrial dysfunction and oxidative stress. However, further clinical and experimental studies are required to elucidate the mechanism(s) responsible for the observed pharmacological activities.

ACKNOWLEDGMENT

The financial assistance provided by the Panjab University, Chandigarh is gratefully acknowledged.

REFERENCES

1. Corley RA, Bartels MJ, Carney EW, Weitz KK, Soelberg JJ, Gies RA, *et al.* Development of a physiologically based pharmacokinetic model for ethylene glycol and its metabolite, glycolic acid, in rats and humans. *Toxicol Sci* 2005;85(1):476-90.
2. Lovric M, Granic P, Cubrilo-Turek M, Lalic Z, Sertic J. Ethylene glycol poisoning. *Forensic Sci Int* 2007;170(2-3):213-5.
3. Patocka J, Hon Z. Ethylene glycol, hazardous substance in the household. *Acta Medica (Hradec Kralove)* 2010;53(1):19-23.
4. El Sawy NA, Faruk EM, Hegazy RM. Does ginger extract protect against ethylene glycol induced hepatic toxicity in adult male albino rats? *Basic Sci Med* 2014;3:17-25.
5. Vale A. Ethylene and diethylene glycol. *Medicine* 2007;35:617-8.
6. Aggarwal D, Kaushal R, Kaur T, Bijarnia RK, Puri S, Singla SK. The most potent antilithiatic agent ameliorating renal dysfunction and

- oxidative stress from *Bergenia ligulata* rhizome. J Ethnopharmacol 2014;158:85-93.
7. Bijarnia RK, Bachtler M, Chandak PG, van Goor H, Pasch A. Sodium thiosulfate ameliorates oxidative stress and preserves renal function in hyperoxaluric rats. PLoS One 2015;10(4):e0124881.
 8. Sharma M, Kaur T, Singla SK. Protective effects of N-acetylcysteine against hyperoxaluria induced mitochondrial dysfunction in male wistar rats. Mol Cell Biochem 2015;405(1-2):105-14.
 9. Jiang JX, Török NJ. NADPH oxidases in chronic liver diseases. Adv Hepatol 2014;2014. pii: 742931.
 10. Paik YH, Brenner DA. NADPH oxidase mediated oxidative stress in hepatic fibrogenesis. Korean J Hepatol 2011;17(4):251-7.
 11. Koziel R, Pircher H, Kratochwil M, Lener B, Hermann M, Dencher NA, et al. Mitochondrial respiratory chain complex I is inactivated by NADPH oxidase Nox4. Biochem J 2013;452(2):231-9.
 12. Liu L, Cui J, Yang Q, Jia C, Xiong M, Ning B, et al. Apocynin attenuates isoproterenol-induced myocardial injury and fibrogenesis. Biochem Biophys Res Commun 2014;449(1):55-61.
 13. Paik YH, Kim J, Aoyama T, De Minicis S, Bataller R, Brenner DA. Role of NADPH oxidases in liver fibrosis. Antioxid Redox Signal 2014;20(17):2854-72.
 14. Abreu IC, Guerra JF, Pereira RR, Silva M, Lima WG, Silva ME, et al. Hypercholesterolemic diet induces hepatic steatosis and alterations in mRNA expression of NADPH oxidase in rat livers. Arq Bras Endocrinol Metabol 2014;58(3):251-9.
 15. Degli Esposti D, Hamelin J, Bosselut N, Saffroy R, Sebah M, Pommier A, et al. Mitochondrial roles and cytoprotection in chronic liver injury. Biochem Res Int 2012;2012:387626.
 16. Sisein EA. Biochemistry of free radicals and antioxidants. Sch Acad J Biosci 2014;2:110-8.
 17. Ben-Shaul V, Lomnitski L, Nyska A, Zurovsky Y, Bergman M, Grossman S. The effect of natural antioxidants, NAO and apocynin, on oxidative stress in the rat heart following LPS challenge. Toxicol Lett 2001;123(1):1-10.
 18. Stefanska J, Pawliczak R. Apocynin: Molecular aptitudes. Mediators Inflamm 2008;2008:106507.
 19. Joshi S, Peck AB, Khan SR. NADPH oxidase as a therapeutic target for oxalate induced injury in kidneys. Oxid Med Cell Longev 2013;2013:462361.
 20. Liu PG, He SQ, Zhang YH, Wu J. Protective effects of apocynin and allopurinol on ischemia/reperfusion-induced liver injury in mice. World J Gastroenterol 2008;14(18):2832-7.
 21. Lu LS, Wu CC, Hung LM, Chiang MT, Lin CT, Lin CW, et al. Apocynin alleviated hepatic oxidative burden and reduced liver injury in hypercholesterolaemia. Liver Int 2007;27(4):529-37.
 22. Zhou R, Hu DY, Liu LM, Zhou XW. Protective effects of apocynin on "two-hit" injury induced by hemorrhagic shock and lipopolysaccharide. Acta Pharmacol Sin 2002;23(11):1023-8.
 23. Lomnitski L, Foley JE, Grossman S, Shaul VB, Maronpot RR, Moomaw CR, et al. Effects of apocynin and natural antioxidant from spinach on inducible nitric oxide synthase and cyclooxygenase-2 induction in lipopolysaccharide-induced hepatic injury in rat. Pharmacol Toxicol 2000;87(1):18-25.
 24. Becker S, Reinehr R, Graf D, vom Dahl S, Häussinger D. Hydrophobic bile salts induce hepatocyte shrinkage via NADPH oxidase activation. Cell Physiol Biochem 2007;19(1-4):89-98.
 25. Li X, Lu J, Shang P, Bao J, Yue Z. The selective NADPH oxidase inhibitor apocynin has potential prophylactic effects on melamine-related nephrolithiasis *in vitro* and *in vivo*. Mol Cell Biochem 2015;399(1-2):167-78.
 26. Wills ED. Mechanisms of lipid peroxide formation in animal tissues. Biochem J 1966;99(3):667-76.
 27. Catalase LH. Methods of Enzymatic Analysis. New York: Academic Press; 1965. p. 885.
 28. Kono Y. Generation of superoxide radical during autoxidation of hydroxylamine and an assay for superoxide dismutase. Arch Biochem Biophys 1978;186(1):189-95.
 29. Ellman GL, Courtney KD, Andres V Jr, Feather-Stone RM. A new and rapid colorimetric determination of acetylcholinesterase activity. Biochem Pharmacol 1961;7:88-95.
 30. King TE, Howard RL. Preparations and properties of soluble NADH dehydrogenases from cardiac muscle. Methods in Enzymol 1967;10:275-94.
 31. King TE, Ohnishi T, Winter DB, Wu JT. Biochemical and EPR probes for structure-function studies of iron sulfur centers of succinate dehydrogenase. Adv Exp Med Biol 1976;74:182-227.
 32. Sottocasa GL, Kuylenstierna B, Ernster L, Bergstrand A. An electron-transport system associated with the outer membrane of liver mitochondria. A biochemical and morphological study. J Cell Biol 1967;32(2):415-38.
 33. Kim MK, Hyun SH, Chung SY. Effect of herbal extract mixtures on serum and liver lipid metabolism in chronic ethanol-administered rats. J Health Sci 2006;52:344-51.
 34. Suresh Kumar S, Sujatha C, Syamala J, Nagasudha B, Mishra S. Protective effect of root extract of *Operculina turpethum* Linn. Against paracetamol-induced hepatotoxicity in rats. Indian J Pharm Sci 2006;68:32.
 35. Sharma A, Sharma KK. Chemoprotective role of triphala against 1,2-dimethylhydrazine dihydrochloride induced carcinogenic damage to mouse liver. Indian J Clin Biochem 2011;26(3):290-5.
 36. Singh B, Saxena A, Chandan B, Anand K, Suri O, Suri K, et al. Hepatoprotective activity of verbenalin on experimental liver damage in rodents. Fitoterapia 1998;69(2):135-40.
 37. Bijarnia RK, Kaur T, Singla SK, Tandon C. Reversal of hyperoxaluria-induced alteration in rat liver by administration of N-acetylcysteine. Drug Chem Toxicol 2007;30(3):229-40.
 38. Aggarwal A, Singla SK, Gandhi M, Tandon C. Preventive and curative effects of *Achyranthes aspera* Linn. extract in experimentally induced nephrolithiasis. Indian J Exp Biol 2012;50(3):201-8.
 39. Turrens JF. Mitochondrial formation of reactive oxygen species. J Physiol 2003;552:335-44.
 40. Kamboj SS, Sandhir R. Protective effect of N-acetylcysteine supplementation on mitochondrial oxidative stress and mitochondrial enzymes in cerebral cortex of streptozotocin-treated diabetic rats. Mitochondrion 2011;11(1):214-22.
 41. Tabrizi SJ, Workman J, Hart PE, Mangiarini L, Mahal A, Bates G, et al. Mitochondrial dysfunction and free radical damage in the huntington R6/2 transgenic mouse. Ann Neurol 2000;47(1):80-6.
 42. Forsmark-Andrée P, Lee CP, Dallner G, Ernster L. Lipid peroxidation and changes in the ubiquinone content and the respiratory chain enzymes of submitochondrial particles. Free Radic Biol Med 1997;22(3):391-400.
 43. Guerrieri F, Capozza G, Fratello A, Zanotti F, Papa S. Functional and molecular changes in FoF1 ATP-synthase of cardiac muscle during aging. CardioScience 1993;4(2):93-8.
 44. Abdoli N, Azarmi Y, Eghbal MA. Protective effects of N-acetylcysteine against the statins cytotoxicity in freshly isolated rat hepatocytes. Adv Pharm Bull 2014;4(3):249-54.
 45. Marí M, Morales A, Colell A, García-Ruiz C, Fernández-Checa JC. Mitochondrial glutathione, a key survival antioxidant. Antioxid Redox Signal 2009;11(11):2685-700.