

**HEPATOPROTECTIVE ACTIVITY OF *BERBERISARISTATA* ROOT EXTRACT AGAINST CHEMICAL INDUCED ACUTE HEPATOTOXICITY IN RATS**NAVDEEP DEHAR\*<sup>1</sup>, RANI WALIA<sup>2</sup>, R.B VERMA<sup>3</sup>, PINKY PANDEY<sup>4</sup><sup>1</sup>MD Assistant Professor, <sup>2</sup>MD Prof. &Head, <sup>3</sup>Professor, Department Of Pharmacology, <sup>4</sup>Associate Professor Department of Pathology M.M. Institute of Medical Sciences and Research, Mullana, Ambala (Haryana, INDIA)

Email: navdeepdehar@gmail.com

Received: 4 September 2013, Revised and Accepted: 26 September 2013

**ABSTRACT**

**Objective:** To study the effects of root extract of *Berberis aristata* in rat model of acute hepatotoxicity induced by carbon tetrachloride (CCl<sub>4</sub>). CCl<sub>4</sub> is commonly used hepatotoxin in the experimental studies of liver diseases. Liver damage induced by CCl<sub>4</sub> involves biotransformation of free radicals derivatives, increased lipid peroxidation and excessive cell death. *Berberis aristata* root extract, "berberine chloride" is known to possess multiple pharmacological activities including anti-microbial, antiviral, anti-inflammatory, cholesterol lowering, anti cancer and anti-oxidant effects. The present study was conducted to evaluate the hepatoprotective activity of berberine in chemical induced hepatotoxicity in rats.

**Material & Methods:** The experimental protocol was approved by the IAEC. Adult wistar rats aged 7-9 weeks were injected intraperitoneally with 50% CCl<sub>4</sub> as 1:1 mixture in liquid paraffin. Berberine was administered i/p before or after CCl<sub>4</sub> treatment in various groups. Twenty-four hours after CCl<sub>4</sub> injection, serum alanine aminotransferase (ALT), aspartate aminotransferase (AST), alkaline phosphatase (ALP) activities, total serum bilirubin levels and liver weight were measured. Histological changes of liver were examined with microscopy.

**Results:** Serum ALT, AST, ALP activities significantly decreased in a dose-dependent manner in both pre-treatment and post-treatment groups with berberine. Histological examination showed lowered liver damage in berberine-treated groups.

**Conclusion:** The present study demonstrates that berberine possesses hepatoprotective effects against CCl<sub>4</sub>-induced hepatotoxicity and that the effects are both preventive and curative. Berberine should have potential for developing a new drug to treat liver toxicity.

**Keywords:** CCl<sub>4</sub>, Berberine, hepatoprotective activity, antioxidant**INTRODUCTION**

Liver is a vital organ of metabolism and excretes virtually every drug and toxin introduced in the body. The global burden of liver disorders amount to more than 30,000 deaths annually [1]. Hepatotoxicity is one of the main reasons behind withdrawal of a drug from the market. 50% of all acute liver failures and 5% of all hospital admissions are associated with drug-induced hepatotoxicity [2]. Numerous medicinal plants are being used for the treatment of liver disorders. In spite of tremendous strides in modern medicine, there is hardly any drug that offers protection to the liver from drug induced damage or help in regeneration of hepatic cells [3]. Many polyherbal formulations reputed to have hepatoprotective action are available in the market for liver disorders but treating a liver disorder by using a precise herbal drug is still an intriguing problem [4, 5].

CCl<sub>4</sub> is the most commonly used hepatotoxin in the experimental studies of liver diseases. Liver cell injury induced by CCl<sub>4</sub> involves the metabolism of CCl<sub>4</sub> to trichloromethyl free radical by the mixed function oxidase system. This leads to wide spread disturbances in hepatocyte function like increased lipid peroxidation and excessive cell death [6,7]. This model of CCl<sub>4</sub> liver induced injury has been widely used in new drug development for liver diseases. *Berberis aristata* is an edible plant in South Asian traditional medicine. Particularly its fruit, root and stem are rich in berberine, which is being used as a tonic remedy for liver and heart. It is known to possess multiple pharmacological activities like antimicrobial, antiviral, anti-inflammatory, cholesterol lowering, anticancer and antioxidant activity [8]. The drugs having antioxidant activity are effective in treating CCl<sub>4</sub> induced toxicity [9,10]. *Coptidis rhizoma* (Huanglin), a popular Chinese herb, rich in berberine has exhibited hepatoprotective effects on CCl<sub>4</sub> induced injury in a study conducted by Feng et al, 2010 [11]. Antioxidant effects of berberine against LDL oxidation [12] and inflammation have also been reported previously. Janbaz & Gilani, 2000 found that berberine has no curative action on CCl<sub>4</sub> induced liver injury at low doses; however, levels of ALT and AST were ameliorated after berberine treatment [8]. There have been reports suggesting the

habitat dependent variations in the content of berberine in the roots and stem-bark of *Berberis* species [13]. To confirm the nature and extent of action of berberine in *Berberis aristata* root extract found in the Himalayan Region in India, it was necessary to do a more systematic and comprehensive study of hepatoprotective effects of berberine in CCl<sub>4</sub> induced acute liver toxicity in rats. The present study aimed at exploring the preventive and curative effects of berberine on liver tissue injury, liver enzymes, total bilirubin and liver weight.

**MATERIAL AND METHODS****STUDY CONDUCT**

The study was conducted at the Department of Pharmacology in collaboration with Department of Pathology and Biochemistry, MM Institute of Medical Sciences & Research, Mullana, India. The experimental protocol was reviewed and approved by Institutional Animal Ethics Committee. (Ref. no.: 101/IAEC/MMIMSR/2011)

**DRUGS AND CHEMICAL REAGENTS**

Berberine chloride, CCl<sub>4</sub>, Heparin, Thiopentone sodium, Phenobarbitone and Liquid paraffin were obtained from Hindustan Pharmaceuticals, Amritsar, India. ALT, AST, ALP and Serum bilirubin kits were purchased from Sigma Aldrich, Bangalore, India.

**ANIMALS**

Healthy albino rats (Wistar strain) of either sex, aged 7 weeks, weighing 130-250 gm were obtained from Central Animal House of MMIMSR, Mullana. The animals were housed in the groups of 6-8 per cage for a minimum of 5 days prior to pharmacological experiments with free access to standard rodent diet with water and maintained on 12 hr light/ dark cycle and temperature (22±3°C). Animal housing, handling techniques and experiment protocols (drug treatment and sacrifice) were complied with the guidelines of CPCSEA, India.

## ACUTE TOXICITY STUDIES

The acute oral toxicity studies were performed for the root extract of *Berberis aristata*, berberine chloride, according to the OPPTS (Office of Prevention, Pesticide and Toxic Substance) Conventional Acute Toxicity Test [14].

Animals were divided into 6 groups with 6 animals in each group:

- Group 1- Negative control (liquid paraffin, 1ml/kg, i/p)
- Group 2 - CCl<sub>4</sub>Toxic control(50% CCl<sub>4</sub> in liquid paraffin, i/p)
- Group 3- CCl<sub>4</sub> + Berberine 5mg/kg, i/p (post treatment)
- Group 4- CCl<sub>4</sub> + Berberine 10mg/kg, i/p (post treatment)
- Group 5- CCl<sub>4</sub> + Berberine 20mg/kg, i/p (post treatment)
- Group 6- CCl<sub>4</sub> + Berberine 10mg/kg, i/p (pre treatment)

Rats from the group 2-6 were injected with CCl<sub>4</sub> at a dose of 1ml/kg, i/p as a 50% liquid paraffin solution while group 1 served as a negative control receiving 1ml/kg, i/p of liquid paraffin only. Berberine was suspended in distilled water at concentration of 5,10 and 20 mg/kg and administered i/p at rats in groups 3-5 respectively after 6 hours of CCl<sub>4</sub> treatment. Rats in group 6 were administered berberine 10mg/kg i/p twice daily for 2 days before CCl<sub>4</sub> treatment. The CCl<sub>4</sub> control group (group 2) was only administered with distilled water of equal volume after CCl<sub>4</sub> toxicity.

## BLOOD SAMPLE COLLECTION

24 hours after CCl<sub>4</sub> treatment, the animals were anaesthetized using thiopentone sodium, 40mg/kg, i/p. Blood samples were collected by cardiac puncture in sterilized dry centrifuge tube and allowed to coagulate for 30 mins at 37 °C. The serum was separated at 2500 rpm (micro centrifuge) for 10 mins and subjected to biochemical investigations viz. aspartate aminotransferase (AST), alanine aminotransferase (ALT), alkaline phosphatase (ALP) and total bilirubin (TB).

## ASSESSMENT OF LIVER FUNCTION

The AST, ALT, ALP activities in serum sample were analyzed by using Chemistry Auto Analyzer (RT 1904C). The values were expressed in terms of International Units/litre (IU/L).

## HISTOPATHOLOGICAL ANALYSIS

Immediately after blood collection the animals were sacrificed by an overdose of phenobarbitone 200 mg/kg, i/p. The liver of each rat was promptly removed and fixed in 10% formaldehyde solution for at least 24 hours before histopathological study. Samples were then embedded in paraffin wax and thin sections were stained with hematoxylin and eosin (H&E) and mounted on glass slides. The degree of liver damage was estimated under light microscope and images were captured with Nikon Pentahead Microscope (ECLIPSE 80i, Y-THR-L, Japan) at original magnification of 210 X.

## STATISTICAL ANALYSIS

The data were analyzed with the help of computer software SPSS version 16 for windows. All data are expressed as mean ± SEM. The results were inferred by one-way analysis of variance (ANOVA) test followed by histopathological analysis. For multiple group comparison, Fisher's LSD test was used. P values (two tailed) <0.05\* & <0.001\*\* were considered statistically significant and highly significant respectively.

## RESULTS

Effects of berberine on AST, ALT, ALP and T. bilirubin levels in rats from various treatment groups are shown in Table 1 as below:

**Table:1 Effects of Berberine chloride on Chemical induced Acute Hepatotoxicity in rats**

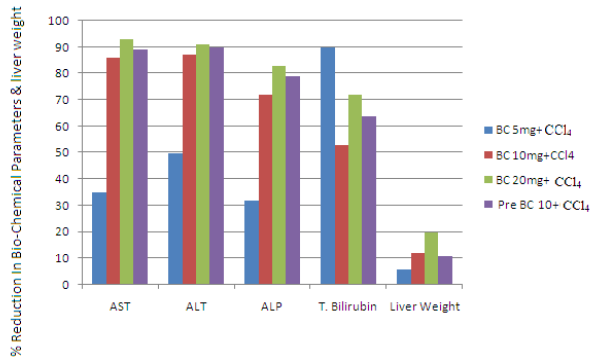
Treatment Group (n=6)	Biochemical parameters (mean±S.E.M)				
	AST(IU/L)	ALT(IU/L)	ALP(IU/L)	T.Bil(IU/L)	Liver Weight
NEGATIVE CONTROL (L.paraffin)	* 42.773 ±13.10	* 34.17 ±4.84	* 47.012 ±4.03	* 0.2733 ±0.05	* 1.95 ±0.05
TOXIC CONTROL (CCl <sub>4</sub> )	529.39 ±86.13	502.56 ±47.03	*293.84 ±32.37	0.81 ±0.06	2.54 ±0.11
BC5mg+CCl <sub>4</sub>	* 343.11 ±175.70	* 250.65 ±25.34	* 200.83 ±32.20	* 0.74 ±0.09	2.38 ±0.08
BC10mg+CCl <sub>4</sub>	* 70.27 ±20.33	* 65.11 ±7.63	* 81.28 * ±15.03	* 0.38 ±0.10	* 2.22 ±0.015
BC20mg+CCl <sub>4</sub>	* 37.277 ±16.90	* 41.3586 ±6.47	* 48.886 ±6.04	* 0.23 ±0.03	* 2.0329 ±0.05
PRE BC10+CCl <sub>4</sub>	* 57.61 18.80±	* 52.3267 ±6.69	* 62.695 ±13.07	* 0.2883 ±0.06	2.2717 ±0.13
<i>* p-value &lt;0.05 significant in comparison to Control Group(Fisher LSD)</i>					
One -way ANOVA	F=39.438 Df 30,5 P= .000*	F=72.524 Df 30,5 P= .000*	F=25.178 Df 30,5 P= .000*	F=15.544 Df 30,5 P= .000*	F=5.092 Df 30,5 P= .002*

Values are expressed as mean ± SEM for albino rats in each group. P values: \* <0.05, \*\* <0.01, when compared with control group

The serum levels of AST, ALT, ALP and T. bilirubin were significantly increased (p<0.01) in CCl<sub>4</sub> treated group 2 rats. Group 3-5 rats treated with CCl<sub>4</sub> followed by berberine chloride at doses of 5, 10 and 20 mg/kg, i/p respectively showed significant decrease (p<0.05) in AST, ALT, ALP and T. bilirubin levels when compared to group 2 rats. The CCl<sub>4</sub> (1ml/kg, i/p) intoxication elevated levels of serum biochemical parameters: AST(529.39±86.13), ALT(502.56±47.03), ALP (293.84±32.37), T. bilirubin (0.81±0.06). The total liver weight was also increased significantly (2.54±0.11, p<0.05) indicating acute hepatocellular damage and fatty degeneration.

When compared with CCl<sub>4</sub> toxic control group, the groups post treated with berberine chloride at doses of 5,10 and 20 mg/kg, i/p in CCl<sub>4</sub> intoxicated rats exhibited significant reduction of AST(343.11±175.70,70.27±20.33, 37.27±16.90), ALT (250.65±25.34,65.11±7.63,41.35±6.47), ALP(200.83±32.20,81.28±15.03,48.88±6.04) and T.bilirubin (0.74±0.09,0.38±0.10, 0.23±0.03) levels and liver weight (2.38±0.08,2.22±0.01,2.03±0.05), (p<0.005). Hence, the activities of the liver enzymes in berberine post treated groups of low dose, medium dose and high dose decreased significantly in a dose dependent manner(AST:F=39.43, p<0.05;ALT:F=72.52, p<0.05;ALP: F=25.17, p<0.05) when compared with CCl<sub>4</sub> toxic control group. The high dose (20mg/kg) of berberine suppressed the AST,ALT, ALP and T.bilirubin levels to lower than normal levels as in group 1 (table1). The effects of Berberine pretreatment on enzyme levels,T. bilirubin and liver weight show that, at dose of 10 mg/kg, the extract could offer significant degree of protection against CCl<sub>4</sub> induced hepatotoxicity. The serum levels of AST,ALT,ALP and T. bilirubin decreased to 57.61±18.80,52.32±6.69,62.69±13.07 and 0.28±0.06 respectively as compared to CCl<sub>4</sub> toxic control group. The liver weight also remained within the normal limits indicating the preventive action of Berberine.The results shown by the pre treatment group are comparable to the results with the medium dose of Berberine post treatment group and are statistically significant (p<0.05 in both groups).

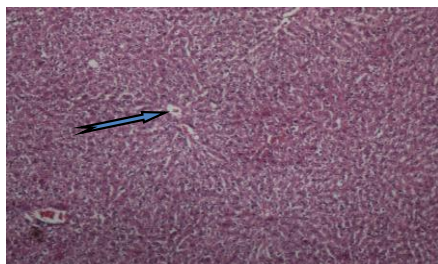The efficacy of extract was tested for its hepatoprotective activity, the relationship between dose and percentage reduction in each case has been shown in Fig 2a as below:



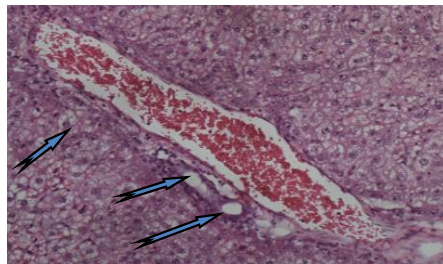
**Figure 2a:** shows effect of *Berberine chloride* on biochemical estimation of AST, ALT, ALP, T. bilirubin & liver weight and percentage reduction in various parameters after treatment with different doses

The percentage reduction of various biochemical parameters after treatment with berberine also showed significant results ( $p < 0.05$ ) in AST (35%, 86%, 93%), ALT (50%, 87%, 91%), ALP (32%, 72%, 83), T. bilirubin (90%, 53%, 72%) and liver weight reduced to 6%, 12% and 20%.

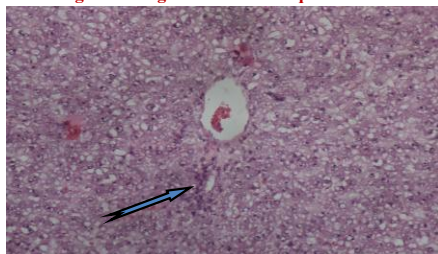### HISTOPATHOLOGY



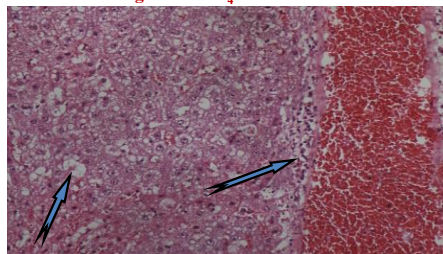
**Figure 1:** Negative control- Liquid Paraffin



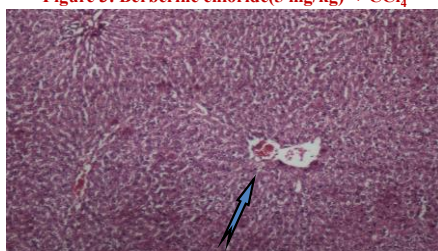
**Figure 2:** CCl<sub>4</sub> Toxic Control



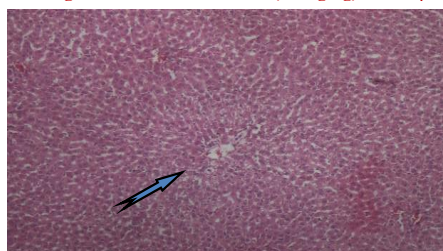
**Figure 3:** Berberine chloride (5 mg/kg) + CCl<sub>4</sub>



**Figure 4:** Berberine chloride (10 mg/kg) + CCl<sub>4</sub>



**Figure 5:** Berberine chloride (20 mg/kg) + CCl<sub>4</sub>



**Figure 6:** Pre-Berberine chloride (10 mg/kg) + CCl<sub>4</sub>

**Figure 1-6:** show representative photographs of histopathological changes showing the effects of berberine chloride at different doses on liver tissue of CCl<sub>4</sub> intoxicated rats

Hepatic tissue changes were improved in the histopathology sections in berberine post and pre treated rats as compared to the toxic control group. The above results indicate the curative and preventive effect of berberine against CCl<sub>4</sub> induced acute liver damage in dose dependent manner.

### DISCUSSION

The aqueous root extract of *Berberis aristata* showed good hepatoprotective activity when administered at doses of 10mg/kg and 20 mg/kg; i/p and the effects were dose dependent. The effects

The results from the histopathological studies of liver sections in various groups are in agreement with the observed serum levels of biochemical parameters.

Group 1-(Liquid paraffin- control, Fig 1) Section shows central veins with radiating chords of hepatocytes (normal architecture)

Group 2-(CCl<sub>4</sub> Toxic control, Fig 2) Section shows macro vesicular fatty change around central vein and large areas of necrosis with inflammation.

Group 3-(Berberine chloride-5 mg/kg +CCl<sub>4</sub>, Fig 3) section shows leaky hepatocytes, macrovesicular fatty change

Group 4-(Berberine chloride-10 mg/kg +CCl<sub>4</sub>, Fig 4) section shows lymphomononuclear cell infiltrate in periportal and centrilobular areas as well as scattered feathery degeneration with significantly dilated and congested sinusoids.

Group 5-(Berberine chloride-20mg/kg +CCl<sub>4</sub>, Fig 5) section shows presence of normal hepatic cords, absence of necrosis and macrovesicular fatty change (near normal architecture)

Group 6-(Pre- Berberine chloride 10 mg+CCl<sub>4</sub>, Fig 6) section shows normal hepatic architecture, nearly similar to that of healthy control with very mild hepatic steatosis.

[15]. The root extract of *Berberis aristata* known to have anti oxidant activity [6,7]. The CCl<sub>4</sub> induced significant increase in liver enzymes and T.bilirubin levels. Liver weight was increased due to blocking of secretion of hepatic TGs into plasma[16]. Medium and high dosepost-treatment of the extract cured the increased liver enzyme levels and liver weight in group 2-5 rats and in group 6, pre-treatment with 10mg/kg berberine chloride prevented further increase in liver enzymes and liver weight. Thus, the results presented in our study are in agreement with the previous study conducted by the Feng et al, 2010 on berberine extracted from a Chinese herb, *Coptidisrhizome*. However, the study conducted by Janbaz and Gilani reported that low doses of berberine exhibit no effect in reducing hepatic damage but in our study the lower doses of berberine (5mg/kg, i/p) produced a significant reduction in the biochemical parameters and offered protection to liver tissue. In addition, the histological changes in the rat liver sections post-treated with berberine showed reduced incidence of liver necrosis, fatty degeneration,leukocyte infiltration induced by CCl<sub>4</sub> (Fig 2 to 6).

There are reports about the habitat dependent variations in the Berberine content of *Berberis species* found in the North Himalayan region of India [11]. Due to the discrepancies observed in the actions of the extract at different doses, this study was planned to explore more about the actions of the *Berberis species* found in India. The present study found that Berberine has both preventive and curative effects againstCCl<sub>4</sub> induced liver injury. Additionally, the habitat might have played role in the potency of the extract at a particular dose as lowest dose of 5 mg/kg, i/p could produce significant reduction in serum enzyme and T. bilirubin levels.

#### CONCLUSION

In conclusion, the root extract of *Berberis aristata* showed good hepatoprotective activity against CCl<sub>4</sub> induced acute liver damage. The effects are both preventive and curative in nature and were further endorsed by the histopathological changes in the liver.

#### ACKNOWLEDGEMENT

The authors are immensely grateful to Mr. Parmod Kumar for his constant support throughout this research work.

#### CONFLICT OF INTEREST

The authors declare no conflict of interest.

#### REFERENCES

1. Mehta N and Pinsky MR. Drug-Induced Hepatotoxicity. Medscape Reference: Drugs, Diseases & Procedures. Available at:<http://emedicine.medscape.com/article/169814-overview>.
2. Dey P, Saha MR, Sen A:An overview on drug-induced hepatotoxicity.Asian J Pharm Clin Res. 2013;6(4): 1-4.
3. Chatterjee TK. Medicinal Plants with Hepatoprotective Properties. Herbal Options Books & Allied(P)Ltd.,Calcutta; 2000.p.155.
4. Gupta AK,Misra N: Hepatoprotective Activity of Aqueous Ethanolic Extract of Chamomile capitula in Paracetamol Intoxicated Albino Rats. American Journal of Pharmacology and Toxicology. 2006;1(1):17-20.
5. Sachdeva M, Bajpai M, Razdan BK: Toxicity studies of a developed hepatoprotective polyherbal formulation in experimental rats. Asian J Pharm Clin Res. 2013;6(4): 47-50.
6. Clawson GA: Mechanism of carbon tetrachloride hepatotoxicity. PatholImmunopathol Res.1989;(8):104-112.
7. Recknagel RO,Glende EA, Dolak JA, Waller RL:Mechanism of carbon tetrachloride toxicity. PharmacolTher.1989;(43):139-154.
8. Janbaz KH, Gilani AH: Studies on preventive and curative effects of berberine on chemical induced hepatotoxicity in rodents. Fitoterpia. 2000; (71):25-33.
9. Ye X, Feng Y, Tong Y, Ng KM, Tsao SW, Lau GKK et al: Hepatoprotective effects of Coptidis rhizome aqueous extract on carbon tetra chloride-induced acute liver hepatotoxicity in rats. J Ethnopharmacol. 2009;(124):130-136.
10. Yokozawa T, Ishida A, Cho EJ, Kim HY, Kashiwada Y, Ikeshiro Y:CoptidisRhizoma protective effects against peroxynitrite-induced oxidative damage and elucidation of its active components. J Pharmacol. 2004;(56):547-556.
11. Feng et al: Hepatoprotective effects of berberine on carbon tetrachloride- induced acute hepatotoxicity in rats. Chinese Medicine. 2010;(5):33.
12. Hsieh YS, Kuo WH, Lin TW, Chang HR, Lin TH, Chen PN et al. Protective effects of berberine against Low-Density Lipoprotein(LDL) oxidation and oxidized LDL-induced cytotoxicity on endothelial cells. J Agne hood Chem. 2007;(55):10437-10445.
13. Andola HC, Gaira KS, Rawal RS, Rawat MS, Bhatt ID: Habitat-dependent variations in berberine content of *Berberis asiatica*Roxb. ex. DC. In Kumaon, Western Himalayan. Chem Biodivers.2010; 7(2):415-20.
14. Health Effect Test Guidelines: Acute Oral Toxicity (Computer Program) OPPTS 870,1100. United States Environmental Protection Agency. December 2002;(7101):1-37.
15. Shenoy KA, Somayaji SN, Bairy KL: Hepatoprotective effect of Ginkgo biloba in carbon tetrachloride induced hepatic injury in rats. Indian J Pharamcol. 2001;(33):260.
16. Yoko A, Koyama T, Miyagie C, Miyahira M, Inomata C, Kinoshita S et al: Free radical scavenging and hepatoprotective action of the medicinal herb, *Crassocephalumcrepietioides* from Okinowa Islands. Biol Pharm Bull.2005;(28):19.