

Article now published at:

<https://pn.bmj.com/content/early/2021/07/01/practneurol-2021-003019>

## Suspecting dementia

### Canaries, chameleons and zebras

Jeremy CS Johnson<sup>1</sup>, Laura McWhirter<sup>2</sup>, Chris JD Hardy<sup>1</sup>, Sebastian J Crutch<sup>1</sup>, Charles R Marshall<sup>3</sup>,  
Catherine J Mummery<sup>1</sup>, Jonathan D Rohrer<sup>1</sup>, Martin N Rossor<sup>1</sup>, Jonathan M Schott<sup>1</sup>,  
Rimona S Weil<sup>1</sup>, Nick C Fox<sup>1</sup>, Jason D Warren<sup>1</sup>

- 1 Dementia Research Centre, UCL Queen Square Institute of Neurology, University College London, London
- 2 Centre for Clinical Brain Sciences, University of Edinburgh
- 3 Preventive Neurology Unit, Wolfson Institute of Preventive Medicine, Queen Mary University of London, London

Correspondence to: Prof Jason Warren  
Dementia Research Centre  
UCL Queen Square Institute of Neurology  
University College London  
8 – 11 Queen Square  
London WC1N 3BG, UK  
Email: [jason.warren@ucl.ac.uk](mailto:jason.warren@ucl.ac.uk)  
Tel: +44 (0)203 448 4773

Key words: Dementia, diagnosis, Alzheimer's, Lewy body disease, frontotemporal dementia, primary progressive aphasia, semantic dementia

Abstract: 127 (150)

Word Count: 2934 (2000)

Refs: 36 (40)

## **Abstract**

Early and accurate diagnosis of dementia is more important than ever before but remains challenging. Dementia is increasingly the business of neurologists and with ageing populations worldwide, will become more so amongst almost all neurologists. Here we outline a practical, symptom-led, bedside approach to suspecting dementia and its likely diagnosis inspired by clinical experience and based on recognition of characteristic syndromic patterns. We show how clinical intuition reflects underlying signature profiles of brain involvement by the diseases that cause dementia and suggest next steps that can be taken to define the diagnosis. We propose 'canaries' that provide an early warning signal of emerging dementia and highlight the 'chameleons' that disguise or mimic this as well as the 'zebras' that herald a rare (and sometimes curable) diagnostic opportunity.

## Introduction

As the number of people worldwide with dementia approaches fifty million, the need for early and accurate diagnosis is more urgent than ever(1). Timely diagnosis avoids the limbo of diagnostic uncertainty and futile cycles of investigation, equips patients and families to engage appropriate support and plan for the future, and directs rational and appropriate management(2). It will also be essential for the effective deployment of disease modifying therapies that are on the horizon. However, early diagnosis of dementia is challenging and remains peculiarly reliant on clinical judgment (Box 1); the target diseases are complex and affect aspects of higher brain function that are generally not assessed in routine neurological practice. Treatises on dementia often list the clinical features of particular diseases – in the trenches, however, suspecting dementia in the first place and deciding why this is not ‘just’ Alzheimer’s disease is often the biggest challenge.

Dementia is a syndrome that can be defined very generally as a progressive decline in cognitive function and/or behaviour that impacts daily life functioning. As such, it has a multiplicity of causes. Most of these are neurodegenerative pathologies that are not presently reversible, however, the rare exceptions are not to be missed. A key theme in dementia (particularly in neurodegenerative disease) is that the causative pathologies initially target certain brain functions relatively selectively, due to a predilection of pathogenic proteins to involve particular brain networks(3). Over time, these signature patterns become obscured as spread of the pathological process leads to convergent, widespread damage and impairment. The window of greatest opportunity for accurate diagnosis (and anticipated interventions) is therefore early-stage disease. Appreciating how profiles of brain damage relate to cognitive deficits is key to deciding which diseases are likely in patients presenting with suspected dementia.

Here we outline a symptom-led, bedside approach to suspecting dementia that we have found useful in busy neurological clinics. We consider, firstly clues that help one decide whether or not cognitive decline is present and if so, the likely cause. We show how these clues predictably reflect underlying signature patterns of brain involvement by particular causative pathologies and suggest next steps that can be taken to define the diagnosis. As with many other disorders, the neurologist’s essential task is to identify ‘canaries’ that provide an early warning signal of emerging disease, avoid being misled by ‘chameleons’ that disguise or mimic this and remain alert to the occasional ‘zebra’ that heralds a rare (and sometimes curable) diagnosis.

We suggest some general principles and tools for cognitive assessment in Box 1 and Figure 1 and outline a bedside framework for cognitive history-taking and examination in Table 1. Diagnostic ‘canaries’ based on characteristic patterns of cerebral involvement are listed in Table 1, potential pitfalls in Table 2, ‘chameleons’ in Table 3 and ‘zebras’ in Table 4.

### Does this patient have dementia?

Distinguishing early dementia from the ‘worried well’ or ‘functional’ cognitive disorder is an increasingly frequent challenge faced by neurologists as public awareness and anxiety about dementia continues to

increase(4). A functional cognitive disorder should be considered if there are positive features of internal inconsistency, i.e. ability to perform a task well at certain times, but with significant difficulty when it becomes the focus of attention. The person who gives a detailed (or even over-inclusive) account of their memory lapses, attributes their difficulties eloquently to specific past events and who is substantially more concerned about their cognitive function than their partner, children or colleagues - often attending clinic unaccompanied - is more likely to be anxious or have a functional cognitive disorder than dementia. People with obsessional personalities are more prone to over-interpret the imperfections of normal memory. There is often a flavour of wavering concentration, such as being unable to remember why one has entered a room, misplacing household items in odd locations (e.g., keys in the fridge) or 'going blank' during a conversation only to have the required information re-emerge soon afterward. Cognitive testing frequently generates considerable anxiety, inducing 'thought-blocking' and performance may vary widely between assessments, often leading to marked inconsistencies (disastrous test scores despite evident competence in daily life). This contrasts with the 'face-saving', humour and minimisation often seen in Alzheimer's disease, or indifference in diseases where insight is impaired. However, particularly in older patients, functional cognitive impairment may signal an emerging neurodegenerative process.

Depression or other primary psychiatric diagnoses must not be overlooked - these are potentially treatable and undetected carry significant risk of harm. There is often a history of previous psychiatric episodes. Core depressive symptoms are low mood or anhedonia, variably accompanied by fatigue, psychomotor retardation, impaired concentration, a sense of personal worthlessness, significant change in appetite or recurrent morbid thoughts(5). Depressed patients are often downcast and disengaged, giving frequent 'don't know' responses. Active psychosis also leads to poor engagement and there may be evidence of delusional thinking or verbal hallucinations. It is important to keep in mind that anxiety, mood changes and psychosis occur not uncommonly in 'organic' dementias and may be early features(6,7); moreover, organic deficits may be elaborated by patients with abnormal illness behaviour; and certain syndromes (such as parietal presentations of Alzheimer's disease and behavioural variant frontotemporal dementia) are notoriously prone to psychiatric mislabelling even by experienced clinicians.

## Some important canaries

**Alzheimer's disease.** Older patients with episodic and topographical memory impairment that declines over time will most commonly have emerging Alzheimer's disease. Details of important events and conversations are not retained, questions become repetitive and there is often a loss of facility with route-finding and a history of becoming lost. There may be a signal 'catastrophic' episode (often, disorientation in unfamiliar surroundings, e.g. while on holiday) preceding more pervasive deterioration. Difficulty following conversations in background noise and dislike of noisy environments (due to impaired auditory scene processing) tend to develop early(8). Loss of pleasure in reading (probably multifactorial in nature) is also frequently reported. Retained (partial) awareness of limitations as well as endogenous emotional changes wrought by the disease

often lead to loss of confidence or initiative, embarrassment, anxiety and withdrawal from social activities, manifesting in the clinic as a tendency to 'trail' the accompanying person into the room and to turn to them ('head-turning sign') when asked a question(6,9). On bedside testing, the extent to which cognitive impairment has been masked by well-preserved social façade may be surprising: knowledge of current affairs tends to be vague, recall of previously presented items does not benefit from cueing and topographical material (such as reconstructing the journey to the hospital) may be particularly challenging.

Beyond memory, parietal cortical functions including word retrieval, praxis, calculation and visuospatial function are affected relatively early in Alzheimer's disease. There may be difficulties with word finding, handling household appliances, managing money or visuospatially demanding activities such as driving or DIY. Coming to grips with new technology taxes learning, executive and parietal functions and is often particularly challenging.

**Lewy body dementia.** Dementia commonly develops in Parkinson's disease (particularly in older patients) and is a core feature of Lewy body pathology(10). Clues include an early predisposition to severe, prolonged delirium (for example, attending a minor infection or surgical procedure) and sometimes acting out of dream content (REM sleep behaviour disorder, due to loss of normal skeletal muscle atonia). Later, misperceptions and hallucinations (usually predominantly visual) develop, though these may not be volunteered. Initially, they may be brief transients glimpsed in the periphery but evolve into vivid, animate entities (commonly faces, people or animals) that emerge out of background features (such as foliage or a pile of clothes) in stereotyped fashion, particularly under low-light conditions. In contrast to psychotic or dopamine-driven hallucinations, these are typically non-threatening though insight into their nature may be impaired. An 'extracampine' sense of a presence beyond the field of vision is common. Marked fluctuations in alertness, attention and cognitive competence even within the course of a day (particularly deterioration later in the day) are also characteristic(11). Complaints of 'double vision' and problems reading (without identifiable ocular pathology) are common, and difficulty using gadgets such as a smartphone exposes executive and parietal dysfunction. Features of associated Parkinsonism (such as hypomimia or gait changes) may be subtle initially but it is worth asking about autonomic symptoms (particularly urinary urgency, nocturia or unexplained collapses)(12,13).

**Vascular cognitive impairment.** The most common cognitive syndrome of cerebrovascular disease is not the stepwise decline in function of classical teaching, but an insidious deterioration characterised by disorganisation, loss of verve and initiative, irritability, mental rigidity, emotional lability and other mood changes, and sometimes inappropriate or disinhibited social behaviour. Vascular risk factors are common, but their absence does not exclude the diagnosis. Examination typically reveals cognitive and affective blunting, executive dysfunction, impaired attention and recall (which in contrast to Alzheimer's disease, does generally benefit from cueing) with variable additional, more focal deficits(14,15), however these may be over-estimated due to often significant slowing of mentation. Brisk tendon and pout reflexes (despite flexor plantar responses) where present are characteristic and in more advanced cases gait may be wide-based and shuffling.

Dysphagia may develop later in the disease. Though this is one of the few diagnoses in neurology where a compatible scan is sine qua non; over-diagnosis of incidental vascular changes is a significant pitfall, compounded by the frequent coexistence of cerebrovascular with primary neurodegenerative pathologies.

## Some chameleons and zebras

**Alzheimer's disease variants.** Atypical presentations of Alzheimer's disease dominated by non-amnestic deficits are not uncommon, particularly in younger patients(16,17); conversely, Alzheimer's disease is simulated by a variety of other disease processes(18). Some of these 'chameleons' are summarised in Table 3; it is particularly important to consider potentially reversible mimics, such as transient epileptic amnesia or obstructive sleep apnoea(18–24). There are three major Alzheimer variant syndromes, likely reflecting differential involvement of the same core temporo-parieto-frontal brain network targeted by Alzheimer pathology (see Tables 1 and 2, Figure 2)(16–18). These variants lie on a clinical continuum and overlap is frequent.

Posterior cortical atrophy, the 'visual variant' of Alzheimer's disease, usually presents with impairments of visuospatial awareness, reading and praxis(17). Beware the patient who has made numerous futile visits to the optician or who describes more difficulty reading pixelated signs than newsprint (signifying visual apperceptive agnosia): this is the cardinal degenerative disorder of the visual brain, disrupting the interpretation of visual scenes despite normal sensory acuity. There is usually a full hand of accompanying parietal lobe deficits but episodic memory early on is often well preserved.

Logopenic aphasia is the language-led variant of Alzheimer's disease within the primary progressive aphasia spectrum(25). It is characterised by prominent word finding difficulty, conversational pauses (sentences tend to trail off) with speech sound (phonological) errors and, on examination, impaired repetition of phrases despite intact repetition of single words (due to reduced verbal working memory)(26).

The 'frontal' (behavioural / dysexecutive) variant of Alzheimer's disease remains the least well defined(27). Clinically it can closely resemble the behavioural variant of frontotemporal dementia, but prominent accompanying memory impairment may be a bedside clue to the diagnosis.

**Frontotemporal dementia syndromes.** Among the 'zebras' of dementia diagnosis, the frontotemporal dementias are particularly important because they are collectively a major cause of dementia in middle life and wreak havoc on social and occupational functioning. This is a diverse group of diseases with complex neurobiology(28), however three major clinical presentations are recognised.

The behavioural variant of frontotemporal dementia presents with abnormalities of social and emotional awareness and reactivity(28,29). The patient generally lacks insight, but the family complains bitterly that they have 'changed', typically with loss of warmth and social skills (there may have been embarrassing faux pas), and frequently prominent apathy, rituals and/or impulsivity that may have resulted in loss of a job or ill-advised decisions. Gluttony and development of a pathological sweet tooth are characteristic, exemplifying a much

broader repertoire of odd, inflexible and maladaptive behaviours with valuation of abstract or impersonal interests over other people. These features may be particularly striking in patients with selective right temporal lobe atrophy(30), who also frequently exhibit prosopagnosia. Behavioural variant frontotemporal dementia is challenging to diagnose, particularly early on, as reliable biomarkers are lacking. Patients may do well on formal cognitive (including executive) tests. There are several highly pertinent clinical issues surrounding the diagnosis: it is genetically mediated in up to perhaps a third of cases (genetic testing for the three major causative, autosomal dominant mutations should be considered in all younger patients) and vigilant neurological follow-up is indicated, both to detect the emergence of major associations (atypical parkinsonism or motor neuron disease) and to identify patients who fail to manifest abnormalities on brain MRI or metabolic (FDG-PET or SPECT) imaging. The nosological status of these latter ‘phenocopy’ cases is still unclear.

Among language-led dementia syndromes (the primary progressive aphasia), the nonfluent-agrammatic variant is the most immediately clinically striking. These patients characteristically have effortful, unmelodious, misarticulated ‘apraxic’ speech and their utterances may be terse and agrammatic (‘telegraphic’). Initially, naming and comprehension are largely intact and written expression is usually more fluent than speech(25,31). As the syndrome evolves, impairments of orofacial praxis (affecting volitional movements such as whistling) and dysphagia often supervene, frequently with emergence of an extrapyramidal syndrome in the corticobasal – progressive supranuclear palsy spectrum.

In contrast, the semantic variant of primary progressive aphasia presents with increasingly circumlocutory and vacant speech that is well constructed and fluent (even garrulous). These patients characteristically have asked family members the meanings of words (‘What’s a tornado?’) and often compile personal ‘dictionaries’. They have early, profound anomia, underpinned by impaired single word comprehension and vocabulary loss affecting all language channels, often extending to a tendency to sound irregular words (such as ‘yacht’) as they are printed (‘surface dyslexia’ (25,31)). The true nature of this syndrome is captured in its older designation, ‘semantic dementia’: this is the paradigmatic disorder of the semantic memory system that mediates knowledge about words, objects and concepts. As it evolves, nonverbal semantic knowledge about visual and other sensory objects and about the emotional and social signals of other people also disintegrates. Patients generally develop a behavioural syndrome similar to behavioural variant frontotemporal dementia. In our experience, patients invariably have focal, asymmetric, usually predominantly left sided anterior temporal lobe atrophy on MRI at presentation (Figure 2); if this is absent, we hesitate to invoke the diagnosis.

**Other ‘zebras’.** These are many and diverse (Table 4): clues to their presence include younger age of onset, a family history of younger onset dementia (often labelled as Alzheimer’s disease or psychiatric illness), prominent extra-cognitive neurological or systemic features or a rapid course. The last group includes catastrophic illnesses such as prion disease but also a number of reversible processes that demand careful exclusion (Table 4). Diagnosis of the many rare diseases that cause dementia in younger adults due to

metabolic, biochemical, storage and other inherited disorders generally depends on clinical features or markers beyond cognition(32–34): these disorders tend to produce a fairly nondescript ‘fronto-subcortical’ cognitive syndrome led by executive and neuropsychiatric dysfunction.

## Next steps after suspecting dementia

If available, more detailed cognitive testing with a neuropsychologist is often a valuable extension to the bedside assessment to: quantify suspected deficits in relation to age-appropriate norms and premorbid attainment; to detect deficits in domains (such as executive function) that are challenging to assess at the bedside; and to compare performance over serial assessments, which may be diagnostic in cases of clinical doubt.

Any patient with suspected dementia should have brain imaging (ideally MRI) – occasionally this will reveal a surgically remediable process but more generally it defines the profile of atrophy in neurodegenerative diseases (Figure 2) and detects signal alterations such as those associated with cerebrovascular disease, leukodystrophies and prion disease. Serial imaging of change over a year or more can be informative if the first scan is normal. Conversely, frontal or parietal ‘atrophy’ is quite commonly over-interpreted on MRI. Brain FDG-PET or SPECT is sometimes useful to demonstrate regional cerebral hypometabolism where Alzheimer’s disease or a frontotemporal dementia is suspected but MRI is inconclusive.

Although screens of basic haematological and metabolic parameters are worthwhile to detect potentially reversible factors that may contribute to cognitive decline, these are rarely the primary culprit. Diagnostic markers of dementia are currently largely derived from CSF analysis, which should be considered in any patient with younger onset dementia (arbitrarily, before age 65) or rapid evolution, when it is likely to have the most useful predictive value (see Tables 3 and 4) – relevant CSF constituents include cells and oligoclonal bands (pointers to brain inflammation), neurofilament light chain (a nonspecific indicator of the presence and severity of neuronal damage) and more specific protein profiles of Alzheimer pathology (raised total and phospho-tau, elevated tau:beta-amyloid42 or beta-amyloid40:amyloid42 ratio).

Diagnostic testing for causative genetic mutations should be considered in younger patients where there is a compatible phenotype and in particular a suggestive (autosomal dominant) family history, but only after appropriately informed counselling in the clinic, particularly with respect to the implications for other family members. Other more specialised investigations may be appropriate in certain clinical contexts (see Table 4).

Local services should be engaged for support early and for atypical and non-AD, patients should be directed to Rare Dementia Support (<https://www.raredementiasupport.org/>) for advice and services.

## Conclusions

Early and accurate diagnosis of dementia is desirable and achievable, but it must first be suspected. As always in neurology, pattern recognition is key. The first challenge is to determine whether dementia is likely; and



then, based on a functionally oriented history and systematic examination, to determine the profile of cerebral involvement and thus the candidate underlying pathology. Despite a growing array of ancillary tools, clinical judgement is likely to remain essential and indeed, to assume even greater importance as effective treatments become available.

## Key points

- Dementia is a syndrome of progressive decline in cognitive function and/or behaviour that impacts daily life functioning and has multiple potential causes
- Timely diagnosis is desirable and achievable with a systematic approach to cognitive assessment
- The major dementias target particular brain networks and accordingly have distinct phenotypes
- Diagnosis rests primarily on clinical assessment, with neuropsychological, neuroimaging and biomarker support where appropriate

## Suggestions for further reading

- Oxford Textbook of Cognitive Neurology and Dementia. Husain M, Schott JM, editors. Oxford University Press; 2016(34).
- Cognitive Assessment for Clinicians. Hodges, J. Oxford University Press; 2017(35).

## Author Declaration

The authors declare no competing interests.

## Acknowledgments

The Dementia Research Centre is supported by Alzheimer's Research UK, Brain Research UK, and the Wolfson Foundation. This work was supported by the Alzheimer's Society, Alzheimer's Research UK and the National Institute for Health Research University College London Hospitals Biomedical Research Centre. JCSJ is supported by an Association of British Neurologists Clinical Research Training Fellowship, funded by Guarantors of Brain. CJDH is supported by a RNID-Dunhill Medical Trust Pauline Ashley Fellowship (PA23). SJC receives support from the ESRC/NIHR Dementia Research Initiative (ES/S010467/1). CRM is supported by a grant from Bart's Charity. RSW is supported by a Wellcome Clinical Research Career Development Fellowship (201567/Z/16/Z). LW receives philanthropic funding from Baillie Gifford. JDW receives grant support from Alzheimer's Research UK, the Alzheimer's Society and the National Brain Appeal (Frontotemporal Dementia Research Studentship in Memory of David Blechner).

## References

1. Livingston G, Sommerlad A, Orgeta V, Costafreda SG, Huntley J, Ames D, et al. Dementia prevention, intervention, and care. *Lancet* [Internet]. 2017 Dec 16 [cited 2019 Dec 18];390(10113):2673–734. Available from: <https://linkinghub.elsevier.com/retrieve/pii/S0140673617313636>
2. Dubois B, Padovani A, Scheltens P, Rossi A, Dell’Agnello G. Timely Diagnosis for Alzheimer’s Disease: A Literature Review on Benefits and Challenges. Saykin A, editor. *J Alzheimer’s Dis* [Internet]. 2015 Oct 17 [cited 2021 Apr 1];49(3):617–31. Available from: <https://www.medra.org/servlet/aliasResolver?alias=iospress&doi=10.3233/JAD-150692>
3. Warren JD, Rohrer JD, Schott JM, Fox NC, Hardy J, Rossor MN. Molecular nexopathies: a new paradigm of neurodegenerative disease. *Trends Neurosci* [Internet]. 2013 Oct 1 [cited 2021 Apr 1];36(10):561–9. Available from: <https://linkinghub.elsevier.com/retrieve/pii/S0166223613001288>
4. McWhirter L, Ritchie C, Stone J, Carson A. Functional cognitive disorders: a systematic review. *The Lancet Psychiatry* [Internet]. 2020 Feb 1 [cited 2021 Jan 15];7(2):191–207. Available from: <https://pubmed.ncbi.nlm.nih.gov/31732482/>
5. Association AP, Force APAD-5 T, editors. Depressive Disorders. In: *Diagnostic and Statistical Manual of Mental Disorders* [Internet]. Arlington, VA: American Psychiatric Association; 2013. Available from: <https://psychiatryonline.org/doi/10.1176/appi.books.9780890425596.dsm04>
6. Johansson M, Stomrud E, Lindberg O, Westman E, Johansson PM, van Westen D, et al. Apathy and anxiety are early markers of Alzheimer’s disease. *Neurobiol Aging* [Internet]. 2020 Jan 1 [cited 2020 Dec 7];85:74–82. Available from: <https://linkinghub.elsevier.com/retrieve/pii/S0197458019303719>
7. Segers K, Benoit F, Meyts J, Surquin M. Anxiety symptoms are quantitatively and qualitatively different in dementia with Lewy bodies than in Alzheimer’s disease in the years preceding clinical diagnosis. *Psychogeriatrics* [Internet]. 2020 May 28;20(3):242–6. Available from: <https://onlinelibrary.wiley.com/doi/abs/10.1111/psyg.12490>
8. Johnson JCS, Marshall CR, Weil RS, Bamiou D-E, Hardy CJD, Warren JD. Hearing and dementia: from ears to brain. *Brain* [Internet]. 2021 Mar 3 [cited 2021 Jan 19];144(2):391–401. Available from: <https://academic.oup.com/brain/advance-article/doi/10.1093/brain/awaa429/6044086>

9. Fukui T, Yamazaki T, Kinno R. Can the 'Head-Turning Sign' Be a Clinical Marker of Alzheimer's Disease? *Dement Geriatr Cogn Dis Extra* [Internet]. 2011 Oct 12 [cited 2021 Apr 1];1(1):310–7. Available from: <https://www.karger.com/Article/FullText/332605>
10. McKeith IG, Boeve BF, Dickson DW, Halliday G, Taylor J-P, Weintraub D, et al. Diagnosis and management of dementia with Lewy bodies. *Neurology* [Internet]. 2017 Jul 4 [cited 2020 Sep 15];89(1):88–100. Available from: <https://pubmed.ncbi.nlm.nih.gov/28592453/>
11. Matar E, Shine JM, Halliday GM, Lewis SJG. Cognitive fluctuations in Lewy body dementia: towards a pathophysiological framework. *Brain* [Internet]. 2020 Jan 1 [cited 2021 Feb 19];143(1):31–46. Available from: <https://academic.oup.com/brain/article/143/1/31/5587662>
12. McKeith IG, Ferman TJ, Thomas AJ, Blanc F, Boeve BF, Fujishiro H, et al. Research criteria for the diagnosis of prodromal dementia with Lewy bodies. *Neurology* [Internet]. 2020 Apr 28 [cited 2021 Jan 19];94(17):743–55. Available from: </pmc/articles/PMC7274845/?report=abstract>
13. Fujishiro H, Iseki E, Nakamura S, Kasanuki K, Chiba Y, Ota K, et al. Dementia with Lewy bodies: early diagnostic challenges. *Psychogeriatrics* [Internet]. 2013 Jun 1 [cited 2021 Jan 19];13(2):128–38. Available from: <http://doi.wiley.com/10.1111/psyg.12005>
14. van der Flier WM, Skoog I, Schneider JA, Pantoni L, Mok V, Chen CLH, et al. Vascular cognitive impairment. *Nat Rev Dis Prim* [Internet]. 2018 Jun 7;4(1):18003. Available from: <http://dx.doi.org/10.1038/nrdp.2018.3>
15. Dichgans M, Leys D. Vascular Cognitive Impairment. *Circ Res* [Internet]. 2017 Feb 3 [cited 2021 Jan 19];120(3):573–91. Available from: <http://circres.ahajournals.org>
16. Warren JD, Fletcher PD, Golden HL. The paradox of syndromic diversity in Alzheimer disease. *Nat Rev Neurol* [Internet]. 2012 Aug 17 [cited 2020 May 13];8(8):451–64. Available from: <http://www.nature.com/articles/nrneurol.2012.135>
17. Crutch SJ, Lehmann M, Schott JM, Rabinovici GD, Rossor MN, Fox NC. Posterior cortical atrophy. *Lancet Neurol* [Internet]. 2012 Feb [cited 2020 Dec 17];11(2):170–8. Available from: </pmc/articles/PMC3740271/?report=abstract>
18. Schott JM, Warren JD. Alzheimer's disease: mimics and chameleons. *Pract Neurol* [Internet]. 2012 Dec 8 [cited 2021 Jan 19];12(6):358–66. Available from: <http://pn.bmj.com/>
19. Atherton KE, Filippini N, Zeman AZJ, Nobre AC, Butler CR. Encoding-related brain activity and accelerated forgetting in transient epileptic amnesia. *Cortex* [Internet]. 2019 Jan 1 [cited 2021 Jan 19];110:127–40. Available from: <https://pubmed.ncbi.nlm.nih.gov/29861041/>

20. Zeman A, Butler C. Transient epileptic amnesia. *Curr Opin Neurol* [Internet]. 2010 Dec;23(6):610–6. Available from: <http://journals.lww.com/00019052-201012000-00011>
21. Olaithe M, Bucks RS, Hillman DR, Eastwood PR. Cognitive deficits in obstructive sleep apnea: Insights from a meta-review and comparison with deficits observed in COPD, insomnia, and sleep deprivation. *Sleep Med Rev* [Internet]. 2018 Apr 1 [cited 2021 Jan 19];38:39–49. Available from: <https://pubmed.ncbi.nlm.nih.gov/28760549/>
22. Bubu OM, Pirraglia E, Andrade AG, Sharma RA, Gimenez-Badia S, Umasabor-Bubu OQ, et al. Obstructive sleep apnea and longitudinal Alzheimer’s disease biomarker changes. *Sleep* [Internet]. 2019 Jun 11 [cited 2021 Jan 19];42(6). Available from: <https://pubmed.ncbi.nlm.nih.gov/30794315/>
23. Müller-Schmitz K, Krasavina-Loka N, Yardimci T, Lipka T, Kolman AGJ, Robbers S, et al. Normal Pressure Hydrocephalus Associated with Alzheimer’s Disease. *Ann Neurol*. 2020;88(4):703–11.
24. Oliveira LM, Nitrini R, Román GC. Normal-pressure hydrocephalus: A critical review. *Dement Neuropsychol* [Internet]. 2019 Jun 1 [cited 2021 Jan 19];13(2):133–43. Available from: <https://pubmed.ncbi.nlm.nih.gov/31285787/>
25. Marshall CR, Hardy CJD, Volkmer A, Russell LL, Bond RL, Fletcher PD, et al. Primary progressive aphasia: a clinical approach. *J Neurol* [Internet]. 2018 Jun 1;265(6):1474–90. Available from: <https://doi.org/10.1007/s00415-018-8762-6>
26. Gorno-Tempini ML, Hillis AE, Weintraub S, Kertesz A, Mendez M, Cappa SF, et al. Classification of primary progressive aphasia and its variants. *Neurology* [Internet]. 2011 Mar 15 [cited 2019 Nov 5];76(11):1006–14. Available from: <http://www.neurology.org/cgi/doi/10.1212/WNL.0b013e31821103e6>
27. Ossenkoppele R, Pijnenburg YAL, Perry DC, Cohn-Sheehy BI, Scheltens NME, Vogel JW, et al. The behavioural/dysexecutive variant of Alzheimer’s disease: clinical, neuroimaging and pathological features. *Brain* [Internet]. 2015 Sep 1 [cited 2021 Apr 7];138(9):2732–49. Available from: <https://academic.oup.com/brain/article-lookup/doi/10.1093/brain/awv191>
28. Sivasathiseelan H, Marshall C, Agustus J, Benhamou E, Bond R, van Leeuwen J, et al. Frontotemporal Dementia: A Clinical Review. *Semin Neurol* [Internet]. 2019 Apr 29 [cited 2019 Aug 22];39(02):251–63. Available from: <http://www.thieme-connect.de/DOI/DOI?10.1055/s-0039-1683379>
29. Rascovsky K, Hodges JR, Knopman D, Mendez MF, Kramer JH, Neuhaus J, et al. Sensitivity of revised diagnostic criteria for the behavioural variant of frontotemporal dementia. *Brain*

- [Internet]. 2011 Sep [cited 2019 Dec 9];134(9):2456–77. Available from:  
<https://academic.oup.com/brain/article-lookup/doi/10.1093/brain/awr179>
30. Ulugut Erkoyun H, Groot C, Heilbron R, Nelissen A, van Rossum J, Jutten R, et al. A clinical-radiological framework of the right temporal variant of frontotemporal dementia. *Brain* [Internet]. 2020 Sep 1 [cited 2021 Apr 7];143(9):2831–43. Available from:  
<https://academic.oup.com/brain/article/143/9/2831/5896255>
31. Gorno-Tempini ML, Hillis AE, Weintraub S, Kertesz A, Mendez M, Cappa SF, et al. Classification of primary progressive aphasia and its variants. *Neurology* [Internet]. 2011 Mar 15;76(11):1006–14. Available from:  
<http://www.pubmedcentral.nih.gov/articlerender.fcgi?artid=3059138&tool=pmcentrez&rendertype=abstract>
32. Lynch DS, Wade C, Paiva ARB De, John N, Kinsella JA, Merwick Á, et al. Practical approach to the diagnosis of adult-onset leukodystrophies: an updated guide in the genomic era. *J Neurol Neurosurg Psychiatry* [Internet]. 2019 May 1 [cited 2021 Jan 19];90(5):543–54. Available from: <http://dx.doi.org/10.1136/jnnp-2018-319481>
33. Rossor MN, Fox NC, Mummery CJ, Schott JM, Warren JD. The diagnosis of young-onset dementia. *Lancet Neurol* [Internet]. 2010 Aug [cited 2020 Nov 27];9(8):793–806. Available from: [www.thelancet.com/neurology](http://www.thelancet.com/neurology)
34. Husain M, Schott JM. *Oxford Textbook of Cognitive Neurology and Dementia* [Internet]. Husain M, Schott JM, editors. Oxford, UK: Oxford University Press; 2016. Available from: <https://oxfordmedicine.com/view/10.1093/med/9780199655946.001.0001/med-9780199655946>
35. Hodges JR. *Cognitive Assessment for Clinicians* [Internet]. Vol. 1. Oxford, UK: Oxford University Press; 2017. Available from: <https://oxfordmedicine.com/view/10.1093/med/9780198749189.001.0001/med-9780198749189>
36. Mitchell AJ. A meta-analysis of the accuracy of the mini-mental state examination in the detection of dementia and mild cognitive impairment. *J Psychiatr Res* [Internet]. 2009 Jan 1 [cited 2020 Dec 7];43(4):411–31. Available from:  
<https://linkinghub.elsevier.com/retrieve/pii/S002239560800112X>

## Box 1. Some principles of bedside cognitive assessment

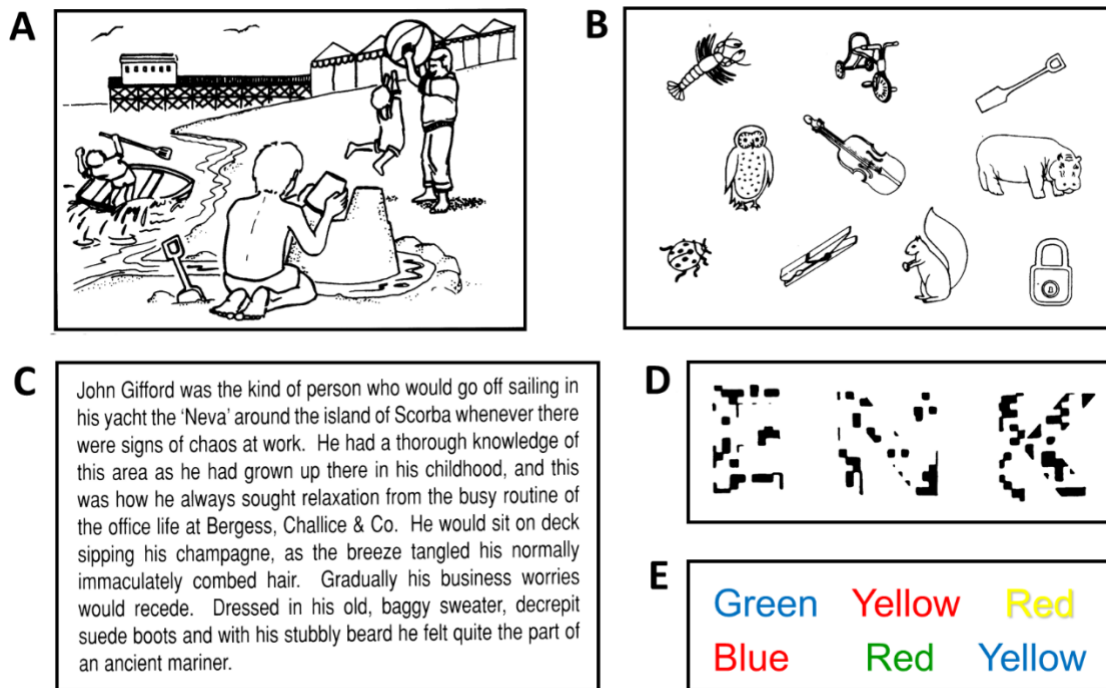
### History taking

- History is the most important aspect of successful dementia diagnosis
- Obtaining a history from a reliable informant who knows the patient well is integral and interviewing them separately may encourage sharing of sensitive or embarrassing clues to the diagnosis
- A minute or two spent putting the patient and family at ease is well invested
- How organised and detailed the patient seems when describing their symptoms is informative, particularly if at odds with performance on formal cognitive tests
- Interpretation of cognitive or behavioural changes depends on an appreciation of the patient's socio-cultural background, education, occupation, premorbid language skills, any pre-existing specific developmental or other deficits and past medical and psychiatric history (including medications)
- Cognitive concerns will most frequently be framed as a non-specific 'memory' problem: this is the most ubiquitous of several potential 'pitfall' symptoms which must be deconstructed (see Table 2).
- Domains of cognitive function and behaviour that may not be volunteered should also be explored (as these help define the cognitive profile), framing these as questions about functioning in daily life
- Particularly in younger people, a detailed family history is essential (including parents' diagnoses and age at death if relevant, and the ages of any siblings)

### Examination

- It is first essential to establish that the patient is alert and cooperative and that their peripheral vision and hearing are adequate (or corrected as appropriate)
- Observing the patient's conduct and interaction with the examiner and others is often telling (it may point to frontal lobe dysfunction more clearly than any test; see Table 2)
- To corroborate the history and build a diagnostic profile of cognitive deficits, it is helpful to have a scheme for testing cognition (a 'walk around the brain', Table 1), armed with some tools to elicit cognitive deficits (Figure 1): the cognitive profile in turn predicts the underlying pattern of brain involvement (Figure 2)
- Quantitative cognitive assessments such as the Mini-Mental State Examination (MMSE), Montreal Cognitive Assessment (MoCA) and Addenbrooke's Cognitive Examination (ACE) are widely available, however each has its limitations (1,36) and none in itself should be used to diagnose or exclude dementia
- The general neurological and systemic examinations are essential, particularly for substantiating diagnoses other than Alzheimer's disease (see Tables 3 and 4)

Figure 1. Examples of aids for testing cognition at the bedside



Here we show some examples of materials that we use to sample a range of cognitive domains (see also **Table 1, Figure 2**) when examining a patient with suspected dementia (shown with permission of Prof EK Warrington). **A**, a pictorial scene for description, to assess connected language (fluency, word finding and expressive grammar) and ability to parse a complex environment (visuospatial processing); **B**, an array of pictures of familiar items, for assessing word retrieval (naming), single word comprehension (pointing to an item nominated by the examiner) and subsequent item recall (anterograde episodic memory); **C**, a passage for reading aloud, to elicit difficulties sounding non-words (personal names, e.g. 'Scorba'; phonological dyslexia) or irregular words (e.g., 'yacht', regularised as 'yached'; surface dyslexia) or with tracking lines of text (visuospatial processing); **D**, fragmented letters, to assess visual apperceptive function; **E**, a Stroop task, requiring the patient to state the (conflicting) colour of the ink in which each colour name is printed (in fluent readers of English, a test of response inhibition – one aspect of executive function).



## Tables and Figures

**Table 1.** Bedside assessment of the patient with suspected dementia – a “walk around the cognitive brain”

Cognitive domain	Leading or early symptoms	Associated symptoms	Examination findings	Brain region(s)	First thoughts
<b>Behaviour</b> (social, emotional)	Loss of empathy/emotional awareness (e.g., family events such as funerals, illnesses, warmth toward children/pets), self-centred	Disinhibition, loss of initiative, obsessiveness/rituals (e.g. clock watching), gluttony/sweet tooth/food faddism, altered interests/ humour, loss of insight / anosognosia	Impulsive, inert, disinhibited interaction, ‘1000-yard stare’	Frontal lobe (especially right), right temporal lobe, other	Behavioural variant frontotemporal dementia
	Irritability, more anxious, ‘clingy’,	Quieter in social situations	Diffident / head turning		Alzheimer’s*
<b>Language output</b> (speech sounds, sentences, prosody)	Stumbling over words, especially public speaking	Mixing up ‘yes’/‘no’, mispronunciations Monotonous/odd accent Grammatical/spelling slips	Effortful speech, reduced articulatory agility (repeating syllable strings, e.g. ‘puh-kuh-tuh’), impaired repeating single words, following complex commands	Left inferior frontal gyrus/peri-Sylvian <sup>1</sup>	Nonfluent primary progressive aphasia
	Word finding difficulty, losing thread of sentences	Reduced speech quantity, pauses	Reduced picture naming	Left temporo-parietal junction	Logopenic aphasia
<b>Knowledge of words</b> (vocabulary) and concepts	Forgetting names, circumlocutions, vague expressing thoughts, ‘going deaf’	Asking meaning of words, keeping personal ‘dictionaries’, decline in spelling / understanding written words	Reduced knowledge of specialist vocab <sup>3</sup> , reduced naming of objects/ability to identify pictures/define words named by examiner, surface dyslexia (irregular words, e.g. ‘yacht’)	Left antero-inferior temporal lobe	Semantic primary progressive aphasia
		Difficulty choosing groceries/tools, etc <sup>2</sup>	Unable to describe / demonstrate use of an object <sup>2</sup> (visual agnosia)		
<b>Reading, spelling and calculation</b>	Loss of pleasure reading Less numerical facility (e.g. change)	Losing place reading text, difficulty resolving closely spaced text Decline in spelling ability	Difficulty reading blocked text Acalculia on simple mental arithmetic	Left parietal lobe	Posterior cortical atrophy, logopenic aphasia, Alzheimer’s
<b>Working memory</b> (verbal)	Poor ‘concentration’	Difficulty holding information e.g. a new phone number online Losing thread of conversation	Reduced forward (passive) digit span, reduced reverse (active) digit span, reduced repetition of phrases > words	Left temporo-parietal junction / frontal lobe	Logopenic aphasia, Alzheimer’s
<b>Action</b> (learned /	Difficulty learning new devices, loss of facility with	Difficulty using household gadgets	Ideomotor limb apraxia: impaired copying meaningless / sequential gestures (Luria)	Left parietal lobe	Posterior cortical atrophy, corticobasal

voluntary: praxis)	DIY etc		Ideational limb apraxia: impaired pantomime of learned actions (e.g. tool, waving)		syndrome
		Difficulty positioning self in space	Bottom apraxia (difficulty sitting on chair)		
	Loss of facility whistling / singing	Difficulty swallowing	Orofacial apraxia: volitional cough/yawn/blow kiss, etc	Left frontal lobe <sup>1</sup>	Nonfluent primary progressive aphasia
<b>Object analysis</b> (visual)	Difficulty reading large/unusual (e.g. pixelated/CAPTCHA) font Not confident on escalators Often multiple optician visits	Difficulty interpreting complex scenes with patterns, overlaid objects, identifying slopes / steps, etc Difficulty recognising or misrecognising objects in suboptimal lighting conditions	Difficulty perceiving fragmented letters/pictures, distorted views	Right parietal lobe	Posterior cortical atrophy, dementia with Lewy bodies
<b>Spatial awareness</b> (visual)	Bumps / scrapes in car, difficulty parking, difficulty filling forms etc	Unable to find items in an array, placing items too close to table edge	Difficulty drawing clockface/ copying design/counting dots, finding examiner's outstretched hand (visual disorientation)	Right parietal lobe	Posterior cortical atrophy, Alzheimer's
<b>Perception</b> (early sensory – visual, auditory, somatic, interoceptive)	Difficulty driving if night/rain	Abnormally prolonged afterimages (colour 'washes', often red / green)	Impaired colour / shape discrimination (e.g. oblong vs square)	Sensory cortices/ thalamus <sup>4</sup>	Posterior cortical atrophy
	'Double vision', brief misperceptions	Illusions / hallucinations	Check visual acuity		Dementia with Lewy bodies
	Dislikes noisy environments	Difficulty conversing in noise	Check peripheral hearing		Alzheimer's and variants
	Tinnitus / hyperacusis	Altered pain / temperature awareness	Check basic sensory function		Semantic primary progressive aphasia, behavioural variant frontotemporal dementia
<b>Face recognition</b>	Loss of facility recognising faces	'Blanking' familiar people Misidentification of 'impostors'	Impaired famous face recognition <sup>5</sup>	Right antero-inferior temporal lobe and connections	Semantic primary progressive aphasia, right temporal lobe atrophy†
			Impaired perception of faces (age/gender)	Right temporal lobe / parietal lobe	Alzheimer's, dementia with Lewy bodies
<b>Executive</b>	Disorganised, distractible,	Difficulty with inference / abstraction,	Reduced / bizarre verbal fluency	Bilateral frontal	May be behavioural

<b>function</b>	poor planning/decision making/multi-tasking/prioritising	choosing alternatives, envisaging/learning from consequences, dealing with novelty	(category/letter – no. animals / ‘S’ words in 1 min) <sup>6</sup> , Stroop task errors, concrete proverb interpretation, inaccurate cognitive estimates (e.g., ‘How many lions in Belgium?’) <sup>7,8</sup>	lobe and connections	variant frontotemporal dementia but depends on associated problems
<b>Memory</b> (episodic and topographical)	More repetitive, less facility with route finding	Vague knowledge of current affairs, getting lost	Orientation to date / time / place, details of hospital journey/stay, incidental recall of pictures from naming test	Hippocampi and connections	Alzheimer’s (but beware)
	Forgetful, absentminded	Poor concentration, disorganised	Improves on cueing / foils; ‘Did you see a...?’)		Vascular / other

This Table presents early symptoms (‘canaries’; see also **Table 2**) that signal difficulty in each major cognitive domain, together with associated symptoms that may be elicited on history. For each domain, we suggest bedside tests (see also **Box 1**) and features that may be used to corroborate the historical impression and indicate major neuroanatomical associations (see also **Figure 2**) and leading diagnostic considerations. \*here refers to the clinical syndrome of typical (memory-led) Alzheimer’s disease; †here refers to the syndrome associated with right temporal lobe atrophy, within the behavioural variant frontotemporal dementia spectrum; **1**, prosody / singing may be additionally linked to right peri-Sylvian cortical regions; **2**, may indicate visual agnosia (the patient with a apraxia can describe how an object is used); **3**, initially loss of knowledge of lower frequency words reflecting patient’s interests / occupation; **4**, usually conjoint ‘top-down’ abnormalities in attentional / executive / semantic functions; **5**, ask for other biographical details if patient cannot name; **6**, in non-aphasic patients; **7**, dependent on education and culture; **8**, the manner in which patient approaches executive tests is also informative, e.g. are they impulsive, do they produce odd items on fluency tasks, do they produce over-precise incorrect estimates that they cannot revise, etc.

**Table 2.** Some noteworthy potential ‘pitfall’ symptoms and signs requiring further clarification or interpretation in suspected dementia

Feature	Clarification / interpretation	Major causes
<b>Ambiguous symptoms</b>		
‘Poor memory’	Often used as a shorthand for ‘cognitive problem’; does it mean episodic memory (events, routes, conversations, etc), semantic memory (words, concepts) or another domain of cognition? If the issue is with memory, is it with encoding information (attention), retaining new information (anterograde memory) or retrieving old information?	Any (may have poor episodic memory in dementia with Lewy bodies, frontotemporal dementia, etc as well as Alzheimer’s*)
‘Getting lost’	Is this truly difficulty completing a route without assistance (topographical disorientation) or wandering (but ultimately getting there)? A useful question can be “how would you make your way home from here if you had to do it alone”?	Alzheimer’s (topography), behavioural variant frontotemporal dementia (wandering)
‘Word finding difficulty’	Often used as a shorthand for ‘language problem’; is it difficulty retrieving the name (very common), loss of vocabulary or difficulty pronouncing the word (uncommon)?	Alzheimer’s/others (retrieval), semantic primary progressive aphasia (vocab), nonfluent primary progressive aphasia (articulation)
‘Lost interest in reading’	Is this a general loss of concentration or initiative, anhedonia, difficulty following the plot or a more specific problem tracking lines of text?	Alzheimer’s (multifactorial), posterior cortical atrophy (text tracking)
‘Doesn’t recognise people’	Is this inability to recall their name (personal anomia; common) or to recognise faces or voices, ‘blinking’ familiar people? (true prosopagnosia or phonagnosia; uncommon)	Alzheimer’s / others (names), semantic primary progressive aphasia / right temporal lobe atrophy† (familiarity)
‘More anxious / irritable’	Might be psychiatric (e.g., atypical depression) but also an early feature of many ‘organic’ dementias	Alzheimer’s, dementia with Lewy bodies, vascular, some frontotemporal dementias (e.g. <i>C9orf72</i> mutations)
‘Black sheep of family’	Youthful delinquency that contrasts with law-abiding siblings	Latent learning disability, very rarely genetic prion disease
<b>Counter-intuitive symptoms</b>		
‘Asks meaning of words’	Loss of ability to understand words in a familiar language	Semantic primary progressive aphasia
‘Reads fine print but not the headlines’	Visual apperceptive agnosia exposed by non-canonical (e.g., very large, pixelated) text	Posterior cortical atrophy
‘Can play tennis [etc] but can’t find ball on ground’	Static visual localisation more impaired than motion vision (or occasionally the reverse), reflecting separable neuroanatomical substrates	Posterior cortical atrophy
‘Says spouse is impostor’	Misidentification delusion (Capgras, etc), can also be for location (e.g. asks to go home)	Alzheimer’s, dementia with Lewy

		bodies
'Much nastier / nicer now'	Altered inter-personal awareness and conduct	Behavioural variant frontotemporal dementia (nasty), Alzheimer's (nice)
'Become very musical / religious / punctual / good at Sudoku'	Enhanced (sometimes loss of) interest /ability in abstract pursuits, usually with loss of interest / affection for other people, on a spectrum of alterations ranging from basic rewards (sweet food, sleep), through sense of humour and timekeeping, to puzzles /complex stimuli	Behavioural variant frontotemporal dementia, semantic primary progressive aphasia
<b>Potentially misleading symptoms</b>		
'It all started after that... [accident/operation/etc]'	Usually this is attribution bias; occasionally we have seen patients in whom severe psychological trauma did seem to provoke catastrophic cognitive decline in a previously asymptomatic person	Any
'Distant memories are fine'	Usually they are not, but highly over-learned or emotional memories tend to become the focus of cherished anecdote	Alzheimer's
'Poor short-term memory'	To a neuropsychologist, this refers to the immediate span of working memory (up to ~30 seconds) but used colloquially to refer to recent episodic memory of variable span	Any
'Thinks people are stealing from them'	Usually not a harbinger of psychosis but a specific delusion of theft (or infidelity)	Alzheimer's, dementia with Lewy bodies
'Going deaf'	Peripheral hearing should always be checked but in context may signify difficulty understanding word meaning	Semantic primary progressive aphasia
'Always been spiritual'	Apparent receptivity to 'ghosts'/presences may signify visual/extracampine hallucinations	Dementia with Lewy bodies
'Unexplained aches/pains'	Hypochondriasis can occasionally reflect abnormal processing of interoceptive signals such as pain	Right temporal lobe atrophy, semantic primary progressive aphasia
<b>Signs not to miss / misinterpret</b>		
Bottom apraxia	Difficulty orienting / positioning self in space as when sitting down in a chair	Posterior cortical atrophy, corticobasal syndrome
Closing-in	Patient overlays their hand or drawing on examiner's target – feature of organic apraxia	Alzheimer's, posterior cortical atrophy
'(Vicar of) Dibley' sign	Binary reversals during conversation - says 'yes' when means 'no', etc	Nonfluent primary progressive aphasia
Dysprosodia (isolated)	Most cases of 'foreign accent syndrome' (recognisable as such, sometimes simulated with pantomime exuberance) will be functional but occasionally patients present with altered prosody and linguistic deficits only supervene (much) later	Nonfluent primary progressive aphasia
Executive dysfunction	As used for example in neuropsychological reports, it is not synonymous with 'frontal lobe problem' but reflects processing across distributed brain networks; moreover, patients with significant frontal lobe dysfunction (as reflected in abnormal behaviour) may perform well on executive tests	Any

Head-turning	To accompanying person, during history taking - lack of confidence / awareness of problem / poor memory	Alzheimer's
Peri-oral dyskinesias	Subtle trembling movements of lips / lower face	Alzheimer's (younger onset)
Pigeon sign	Turns head this way and that trying to make sense of a picture or visual array	Posterior cortical atrophy
Repetitiveness conversing	Signifies an organic problem with anterograde episodic memory / accelerated forgetting	Alzheimer's
Semantic paraphasias	Substitution of related words on a naming task usually will not reflect a primary semantic problem but more likely anomia (impaired word retrieval) with attempted compensation	Alzheimer's, others
Surface dyslexia	Sounds irregularly-pronounced words as they are printed, due to loss of vocab-based reading	Semantic primary progressive aphasia
'Thousand yard stare'	Sense of unease / threat conveyed by patient who lacks normal social facial micro-reactivity	Right temporal lobe atrophy
Tie sign†	Patient touches examiner's tie / face when trying to locate their outstretched hand, due to visuospatial disorientation	Posterior cortical atrophy
'Variable deficit'††	Apraxia is intrinsically variable; organic cognitive impairment of any cause can be impacted by stress or fatigue and certain entities are characterised by marked fluctuation (sometimes sleep benefit / deterioration), due to seizures, channel dysfunction or impaired dopaminergic/cholinergic switching between brain states*	Dementia with Lewy bodies (sleep benefit), transient epileptic amnesia (sleep deterioration), inflammatory, immune

\*here refers to the clinical syndrome of typical (memory-led) Alzheimer's disease; †here refers to the syndrome associated with right temporal lobe atrophy, within the behavioural variant frontotemporal dementia spectrum; ††not the same as inconsistency – organic cognitive fluctuations are internally consistent.

**Table 3.** Some important ‘chameleons’ of dementia diagnosis

Disease	Chameleons	Some useful features to identify the chameleon
<b>Alzheimer’s</b>	<b>Mimics*</b>	
	Transient epileptic amnesia**	Clinical seizures (not invariable), prominent fluctuation, ‘vacational amnesia++’; abnormal (extended) EEG, may have other features of limbic encephalitis, auto-antibodies / cancer
	Obstructive sleep apnoea**	Daytime somnolence, non-refreshing sleep, heavy snoring (from partner); abnormal sleep study
	Normal-pressure hydrocephalus**	May have gait apraxia, urinary dysfunction; MRI hydrocephalus and associated feature
	Vascular	MRI: strategic (e.g., thalamic) infarct, other vascular patterns (including deep micro-haemorrhages)
	Traumatic brain injury / chronic traumatic encephalopathy	History of significant (especially recurrent) head trauma
	Dementia with Lewy bodies frontotemporal dementia, other neurodegenerative	Vary according to underlying pathology; may have genetic mutation (frontotemporal dementia, familial prion), some entities (e.g. argyrophilic grain disease, limbic-predominant age-related TDP-43 encephalopathy) currently only diagnosed post-mortem
	<b>Variants</b>	
	Posterior cortical atrophy Logopenic aphasia Behavioural variant frontotemporal -like Corticobasal syndrome Young onset (sporadic)	Positive Alzheimer markers in CSF (raised total / phospho-tau, reduced beta-amyloid42 and beta-amyloid42/40 ratio), cortical micro-haemorrhages associated with amyloid angiopathy
	Rapid (may have beta-amyloid angiitis)	Positive Alzheimer CSF and MRI markers, cortical micro-haemorrhages / siderosis on MRI
Familial	Young, autosomal dominant family history (may be censored); may have spastic paraparesis / other neurological signs (especially <i>PS1</i> mutation), prominent neuropsychiatric features, white matter change on MRI; <i>PS1,PS2</i> or <i>APP</i> mutation (in addition to Alzheimer CSF markers)	
<b>Dementia with Lewy bodies</b>	<b>Mimics</b>	
	Progressive supranuclear palsy, corticobasal syndrome	Supranuclear gaze palsy, prominent asymmetric apraxia/axial rigidity; poor levodopa response
	<b>Variants</b>	
	Alzheimer-like Behavioural variant frontotemporal-like Rapid	Florid delirium, prominent fluctuations, early visual hallucinations, REM-sleep behaviour disorder, emerging parkinsonism
<b>Vascular cognitive impairment</b>	<b>Mimics</b>	
	Infectious / inflammatory / autoimmune**	Suggestive history, auto-antibodies, blood / CSF serology (e.g. HIV, syphilis)
	Genetic arteriopathies	Young, lack of vascular risk factors, suggestive family history; migraine, MRI involvement of anterior

		temporal lobe, <i>NOTCH3</i> mutations with CADASIL
	Primary leukodystrophies	Young, lack of vascular risk factors, suggestive MRI (confluent, symmetric white matter change), positive diagnostic tests
	<b>Variants</b>	
	Behavioural variant frontotemporal-like	MRI: significant vascular change, lack of suggestive atrophy profile
	Prominent amnesic/ focal 'cortical' deficits	MRI: strategic infarct (especially thalamus, left parietal)
<b>Fronto-temporal dementia†</b>	<b>Mimics</b>	
	'Frontotemporal dementia phenocopy' (especially older males)	Normal MRI, brain FDG-PET; some frontotemporal dementia cases (especially <i>C9orf72</i> mutations) may be very slowly progressive – phenocopy cases often show better preserved insight than is usual with frontotemporal dementia
	Frontal variant of Alzheimer's disease	Prominent associated episodic memory deficit, relatively prominent posterior atrophy on MRI, Alzheimer biomarkers (CSF, amyloid PET)
	Vascular	MRI: vascular features
	Dementia with Lewy bodies	Visual hallucinations, REM-sleep behaviour disorder
	<b>Variants</b>	
	Amnesic / Alzheimer-like	Negative Alzheimer biomarkers
	Corticobasal syndrome	May have <i>GRN</i> mutation
	Motor neuron disease	May have <i>C9orf72</i> mutations
	Very young onset / rapid	MRI: disproportionate caudate atrophy (FUS-opathy)

Here, chameleons are either 'mimics' - a different disease that presents similarly to the typical syndrome, listed in the left-most column - or 'variants' - an alternative, atypical presentation of the same disease process that causes the typical syndrome. \*negative Alzheimer markers may be helpful but Alzheimer pathology frequently coexists with other entities (seizures, obstructive sleep apnoea more common in Alzheimer's disease); †presentation with behavioural variant here taken to be typical (clinical mimics of primary progressive aphasia syndromes are very uncommon); \*\*potentially reversible process; ††no recollection at all of salient events such as vacations (typically in AD there is some recollection of the episode, albeit very degraded). *APP*, amyloid precursor protein; *C9orf72*, mutation of chromosome 9 open reading frame 72; *CADASIL*, cerebral autosomal dominant arteriopathy with subcortical infarcts and leukoencephalopathy; *FUS*, fused-in-sarcoma protein; *GRN*, progranulin gene; *NOTCH3*, neurogenic locus notch homolog protein 3 mutations; *PS1/2*, presenilin 1 / 2 gene mutations.



**Table 4.** Some important ‘zebras’ in dementia diagnosis

Leading clue	Syndromic features (especially early)	Candidate diagnoses		Key investigations
		<i>Sporadic</i>	<i>Genetic†</i>	
<b>Unusual</b>				
Socio-emotional decline leading	Reduced empathy, disinhibition, apathy, obsessionality, stereotypies, altered eating behaviour, executive deficits; atypical parkinsonism (progressive supranuclear palsy / corticobasal syndrome) frequent later	Behavioural variant frontotemporal dementia	<i>C9orf72, GRN, MAPT</i> , others less commonly	MRI (Fig 2), but atrophy highly variable and may be subtle, may have associated midbrain atrophy (progressive supranuclear palsy); genetics
Language decline leading	Effortful, misarticulated, apraxic speech, binary reversals, grammatical errors, orofacial apraxia; atypical parkinsonism (progressive supranuclear palsy / corticobasal syndrome) frequent later	Nonfluent primary progressive aphasia	<i>GRN, C9orf72</i> , others (uncommon)	MRI (Fig 2), but atrophy variable; genetics if young/ suspicious family history
	Loss of vocabulary, severe anomia with impaired single word comprehension despite fluent well-structured speech, often frontotemporal-dementia-like behaviours	Semantic primary progressive aphasia	<i>MAPT</i> , others (rarely)	MRI (Fig 2) characteristic
	Anomia/word-finding pauses, phonemic errors, phrase repetition/verbal working memory deficits	Logopenic aphasia (usually Alzheimer pathology)	<i>GRN</i> (rarely)	MRI asymmetric (predominantly left-sided) temporo-parietal atrophy, CSF Alzheimer markers
Visuospatial decline leading	Difficulty reading unusual fonts/night driving / using gadgets, mispositioning items; later apperceptive agnosia/disorientation, dyscalculia, anomia	Posterior cortical atrophy(usually Alzheimer pathology; some dementia with Lewy bodies, others)		MRI (Fig 2), CSF Alzheimer markers
‘Frontal’ - ataxia	Also urinary urgency / incontinence	Normal-pressure hydrocephalus**		MRI ventriculomegaly and associated features
	May have history of prior neurological episodes	Multiple sclerosis (especially primary / secondary progressive)		MRI (brain / cord) demyelination features, CSF unmatched oligoclonal bands
	History of cranial irradiation (often delayed), also pyramidal / other neurological signs	Post-irradiation vasculopathy		MRI extensive white matter damage
<b>Rapid*</b>	Early widespread cognitive impairment (often prominent visual dysfunction), seizures / myoclonus / other neurological signs	Creutzfeldt-Jakob disease (classically), Alzheimer’s, dementia with Lewy bodies (uncommonly)	Prion (Creutzfeldt-Jakob disease, Gerstmann-Sträussler-Scheinker, familial fatal insomnia, others)††	MRI cortical/basal ganglia signal change, EEG (periodic complexes – Creutzfeldt-Jakob disease),CSF (RT-quIC, Alzheimer markers), DAT

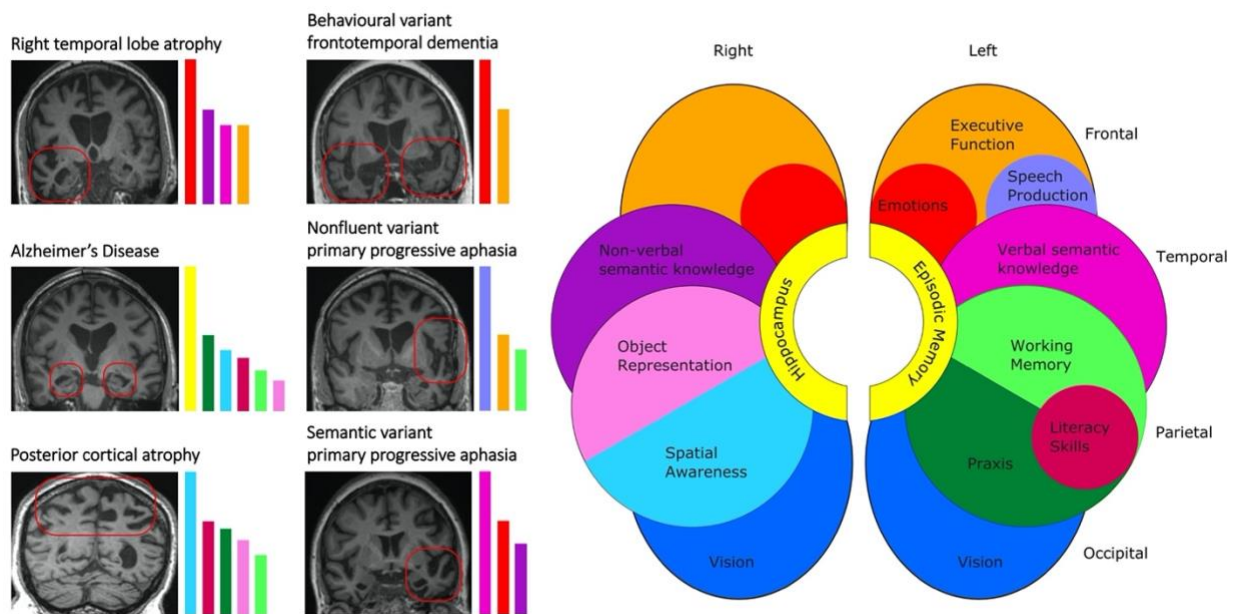
				(?dementia with Lewy bodies), genetics
	Frontotemporal dementia plus deltoid/triceps fasciculations, pyramidal signs	Frontotemporal dementia-motor neuron disease	<i>C9orf72</i>	MRI, EMG (often normal), genetics
	Behavioural variant frontotemporal-dementia-like plus corticobasal syndrome, atypical parkinsonism, young, markedly obsessive/stereotypic behaviour	Frontotemporal dementia (FUS-opathy) <sup>†</sup>		MRI marked caudate atrophy
	Headache, fluctuation, seizures, systemic features	Vasculitis (CNS / systemic)**		MRI, CT angiogram, CSF pleocytosis auto-antibodies/ inflammatory markers; consider brain biopsy
	Seizures, jerks, fluctuation, neuropsychiatric/systemic features	Limbic encephalitis**		MRI high signal in hippocampi / mesial temporal lobe, auto-antibodies, whole body-PET/ neoplasia screens
	Executive/behavioural decline with gait disturbance/variable other neurological features	Tumour (e.g., lymphoma), subdural haematoma, other space-occupying lesions**		MRI mass / gadolinium enhancement, may have non-CNS primary, may need brain biopsy
	Immunosuppressed, compatible history of infection	Human immunodeficiency virus, human herpes viruses, progressive multi-focal leukoencephalopathy, tuberculosis, syphilis, Whipple's, fungal, subacute sclerosing panencephalitis**		MRI abnormal signal / gadolinium enhancement, blood/CSF serology
	Toxic exposure / dietary deficiency states	Alcohol usually nutritional, especially thiamine (Wernicke-Korsakoff syndrome); heroin/other drug abuse, lithium toxicity/ iatrogenic, metals**		MRI various patterns with white/grey matter involvement, abnormal signal; drug, metabolic, metal screens
<i>Young adult</i> <sup>††</sup> <i>Neurological</i>	Ataxia	Paraneoplastic**, superficial siderosis	Spinocerebellar ataxias, Niemann-Pick C, fragile X, mitochondrial, dentato-rubral pallidolusian atrophy, Kuf's, prion	This group in general requires specialist consultation – principles are:
	Akinetic-rigid		Huntington's disease**, neurodegeneration with brain iron accumulation (various)	i) definition of phenotype with brain MRI, plus CSF / electrophysiology depending on presentation
	Autonomic	Sarcoidosis**	Porphyria, adrenoleukodystrophy,	

			hereditary sensory and autonomic neuropathy 1E, familial fatal insomnia	ii) blood screens (metabolic / inflammatory) and/or genetics directed to cause  iii) tissue biopsy if required for diagnosis (especially muscle / axillary skin for storage diseases, etc)
Bucco-lingual mutilation			Neuroacanthocytosis, Lesch-Nyan	
Chorea / dystonia	Antiphospholipid, rheumatological**		Huntington's disease, Wilson's disease**, neuroacanthocytosis, neuronal brain iron accumulation disorders, dentato-rubral pallidolusian atrophy, Kuf's (especially facial)	
Deafness (peripheral)	Susac's syndrome**, Behçet's disease**, siderosis, sarcoidosis**		Mitochondrial, hereditary sensory and autonomic neuropathy 1E	
Eye abnormalities	Behçet's disease, sarcoidosis, Susac's syndrome**		Kayser-Fleischer rings: Wilson's disease** Cataract: cerebrotendinous xanthomatosis **, myotonic dystrophy, mitochondrial Retinopathy: mitochondrial	
Gaze palsy	Chronic meningitides (inflammatory / neoplastic)**		Gaze apraxia: Huntington's disease Supranuclear gaze palsy: (vertical) Niemann-Pick C, (horizontal) spinocerebellar ataxia type 2, Gaucher's** External ophthalmoplegia: mitochondrial	
Peripheral neuropathy	Sarcoidosis**		Mitochondrial, neuroacanthocytosis, Fabry's**, spinocerebellar ataxias, metachromatic leukodystrophy, adrenoleukodystrophy, hereditary sensory and autonomic neuropathy 1E, cerebrotendinous xanthomatosis**, porphyria**	
Pyramidal signs			Spinocerebellar ataxias, familial AD (especially <i>PS1</i> ), adrenoleukodystrophy, Krabbe's	

	Seizures (especially myoclonic)	Poor control, anticonvulsants**	Mitochondrial, dentatorubral-pallidoluysian atrophy, Lafora body disease, Kuf's, progressive multifocal leukoencephalopathy
	Strokes	Antiphospholipid syndrome**	CADASIL, cerebral amyloid angiopathies (familial), Fabry's**
Systemic	Hepatic / gastrointestinal	Hepatic encephalopathy**	Wilson's disease**, Gaucher's**, mitochondrial, porphyria**
	Musculo-skeletal abnormalities	Rheumatological**	Paget's disease, inclusion body myopathy: VCP Tendon xanthomas: cerebrotendinous xanthomatosis** Bone cysts: polycystic lipomembranous osteodysplasia with sclerosing leukoencephalopathy
	Renal impairment	Uraemic encephalopathy**	Fabry's**, mitochondrial
	Skin abnormalities	Behçet's disease, rheumatological**	Fabry's**
	Splenomegaly		Niemann-Pick C, Gaucher's**

This list is not exhaustive. \*slower onset also occurs and is the rule for common neurodegenerative disorders; \*\*potentially treatable process; †family history suggesting autosomal dominant or maternal inheritance in successive generations is particularly helpful but may be censored or absent (these patients also tend to be younger); ††leading features, not covered above - these tend to be the most striking features but various combinations occur; † can be suspected but not presently confirmed during life; †† although genetic prion diseases tend to be rapid, some present indolently. **C9orf72**, mutation of chromosome 9 open reading frame 72; **CADASIL**, cerebral autosomal dominant arteriopathy with subcortical infarcts and leukoencephalopathy; **DAT**, dopamine transporter scan; **FUS**, fused-in-sarcoma protein; **GRN**, progranulin gene mutations; **MAPT**, microtubule associated protein tau mutations; **PS1**, presenilin 1; **RT-quIC**, real-time quaking-induced conversion prion protein detection; **VCP**, valosin-containing protein gene mutation.

**Figure 2.** Cognitive and neuroanatomical profiles of some major dementia syndromes



The cartoon brain (right) shows cognitive functions predominantly mediated by different cerebral regions in each cerebral hemisphere. The T1-weighted coronal MRI sections (left) show characteristic patterns of regional brain atrophy in representative neurodegenerative disorders (typical **Alzheimer's disease** – disproportionate, bilateral hippocampal atrophy; **behavioural variant frontotemporal dementia** - predominant bilateral but asymmetric, frontal and anterior temporal lobe atrophy; **nonfluent/agrammatic variant primary progressive aphasia** – predominantly left-sided, anterior peri-Sylvian cortical atrophy; **posterior cortical atrophy** - predominant biparietal atrophy; **semantic variant primary progressive aphasia** - selective, predominantly left-sided antero-mesial and inferior temporal lobe atrophy; **right temporal lobe atrophy** – selective, predominantly right-sided frontal and anterior temporal lobe atrophy). In each case, the dementia syndrome reflects a profile of brain network breakdown (see also **Table 1**); this correspondence is indicated by the coloured histograms alongside each scan, which code the major cognitive domains affected in each syndrome. The histogram colours follow the same convention as the central cartoon; the heights of the histogram bars are arbitrary but indicate the relative clinical prominence of deficits across cognitive domains that is typically seen in a particular syndrome. The left hemisphere is projected on the right (following standard clinical convention) throughout.