




Contents lists available at ScienceDirect

Clinical Infection in Practice

journal homepage: www.elsevier.com/locate/clinpr

Case Reports and Series

Epstein-Barr virus associated haemophagocytic lymphohistiocytosis treated with anakinra and rituximab: A case report

Naina McCann^{a,*}, Raj Amarnani^a, Muhammad Shipa^a, Saad Ahmed^b, Fathima Thaahira Mohideen^b, Stefan Vöö^a, Jessica J. Manson^a^a University College London Hospitals NHS Foundation Trust, 235 Euston Road, Bloomsbury, London NW12BU, United Kingdom^b Colchester Hospital, Turner Road, Mile End, Colchester CO4 5JL, United Kingdom

ARTICLE INFO

Article history:

Received 27 July 2020

Received in revised form 28 October 2020

Accepted 3 December 2020

Keywords:

Epstein-Barr virus

Haemophagocytic lymphohistiocytosis

Anakinra

Rituximab

HLH

EBV

ABSTRACT

Background: Haemophagocytic lymphohistiocytosis (HLH) is a severe, life-threatening syndrome characterised by hyperinflammation and macrophage activation. Viral infections such as Epstein-Barr virus (EBV) are a well-recognised trigger of HLH but the treatment of such cases is not well-defined. We present a case of primary EBV driven HLH that was successfully treated with the interleukin-1 inhibitor anakinra in addition to rituximab and high-dose steroids.

Case: A 22-year-old female with no past medical history developed a mononucleosis-like illness lasting five days characterised by fevers, sore throat and neck swelling. Two weeks following this she presented with fevers, night sweats, fatigue and right upper quadrant pain. She was diagnosed with HLH based on high fevers with hyperferritaemia, hypertriglyceridaemia, pancytopenia, abnormal liver function tests and hepatosplenomegaly. Extensive investigation revealed an EBV viral load of 23,000,000 copies/ml with nil other obvious triggers. A diagnosis of primary-driven EBV HLH was made. She was treated with the interleukin-1 inhibitor anakinra, methylprednisolone and IVIG and a single dose of rituximab.

Following the commencement of treatment, the patient made a dramatic improvement. Her EBV viral load reduced to 660 within nine days and her blood counts and liver function returned to normal. She was discharged from hospital on day sixteen. She continued the anakinra for 5 weeks at a weaning dose and completed a 12-week weaning dose of steroids. She has returned to her studies and has no lasting complications from her illness.

Discussion: This case highlights the potential of primary EBV infection to cause fulminant HLH. The prompt diagnosis and treatment of HLH using anakinra and rituximab in addition to conventional HLH treatment was safe, and associated with a dramatic clinical improvement. The use of anakinra has been documented in other cases of HLH but none, to our knowledge, of primary EBV-driven HLH with no underlying haematological or rheumatological condition.

© 2020 The Authors. Published by Elsevier Ltd on behalf of British Infection Association. This is an open access article under the CC BY-NC-ND license (<http://creativecommons.org/licenses/by-nc-nd/4.0/>).

Case

We present a 22-year-old female who initially developed symptoms of a sore-throat, flu-like symptoms and neck swelling that was self-limiting and resolved after five days. Two weeks later she developed fevers, drenching night sweats, significant myalgia, fatigue and right upper quadrant abdominal pain. These symptoms persisted for five days before finally she presented to her local hospital as her family noticed she had jaundiced sclera.

* Corresponding author at: University College London Hospitals NHS Foundation Trust, 235 Euston Road, Bloomsbury, London, NW1 2BU, UK.

E-mail addresses: naina.mccann@nhs.net (N. McCann), raj.amarnani@nhs.net (R. Amarnani), s.ahmed8@nhs.net (S. Ahmed), Stefan.voo@nhs.net (S. Vöö), jessica.manson@nhs.net (J.J. Manson).

<https://doi.org/10.1016/j.clinpr.2020.100060>

2590-1702/© 2020 The Authors. Published by Elsevier Ltd on behalf of British Infection Association.

This is an open access article under the CC BY-NC-ND license (<http://creativecommons.org/licenses/by-nc-nd/4.0/>).

She had no previous medical history and was taking no regular medications. Her most recent travel was to South Africa three months prior to this event where she was on holiday for two weeks and remained well. There was no family history of any autoimmune or haematological conditions. She was sexually active with no regular partner and recently had a negative sexually transmitted diseases screen.

On arrival to her local hospital she was found to be tachycardic with a heart rate of 130 bpm and pyrexial with a temperature of 38.2 °C. Significant findings on clinical examination revealed a soft abdomen but palpable hepatosplenomegaly. Her admission blood tests are shown in [Table 1](#).

A computerised tomography (CT) scan of the abdomen confirmed a significant hepatosplenomegaly with a spleen measuring

Table 1
Admission blood results.

Blood test	Day 1
Haemoglobin	87 g/L (115–155 g/L)
White cell count	1.00 × 10 ⁹ /L (3.0–10.0 × 10 ⁹ /L)
Platelets	31 × 10 ⁹ /L (150–400 × 10 ⁹ /L)
Creatinine	276 umol/L (49–92 umol/L)
Ferritin	57,114 ug/L (13–150 ug/L)
LDH	>3000 IU/L (135–214 IU/L)
Fibrinogen	1.58 g/L (1.5–4.0 g/L)
INR	1.28
APTT	34.8 secs (25–37 secs)
PT	15.2 secs (10.0–12.0 secs)
Bilirubin (total)	96 umol/L (0–20 umol/L)
ALT	103 IU/L (10–35 IU/L)
Triglyceride	7.22 mmol/L (0.4–2.3 mmol/L)
CRP	302 mg/L (0–5.0 mg/L)

16 cm. In view of the clinical, laboratory and radiological findings, a diagnosis of haemophagocytic lymphohistiocytosis (HLH) was made. Her HScore (Fardet et al., 2014) was 284 giving her an > 99% probability of HLH using this diagnostic method (see Tables 2 and 3).

The patient was admitted to her local intensive care unit for monitoring and was treated with 15 mg of intravenous rasburicase, 15 mg of intravenous dexamethasone and 10 g of intravenous immunoglobulin on day one. She was also empirically treated with a single dose of 4.5 g of piperacillin/tazobactam that was shortly escalated to 1 g of meropenem and 600 mg of clindamycin following advice from the local microbiology team. On day two she continued to deteriorate and developed new confusion. She was urgently transferred to the intensive care unit at our tertiary specialist centre for further management. On arrival, she was commenced on intravenous immunoglobulin (a further 45 g given), intravenous anakinra 200 mg twice a day and intravenous methylprednisolone 1 g for 3 doses. Antibiotics were not continued after transfer to our centre in view of no clear evidence of a bacterial infection. She was then switched onto once daily intravenous methylprednisolone 40 mg on day three that was slowly weaned to oral prednisolone 40 mg by day ten.

Numerous investigations were carried out to look for a potential driver of her HLH (Table 4). Genetic testing for primary/familial HLH was performed and was negative. The only significant positive finding was her EBV VCA IgM and IgG were positive with a negative EBV EBNA IgG. The EBV viral load performed on plasma using the Qiagen artus PCR assay was 23,000,000 copies/ml. She also had an 18F FDG PET-CT that showed enlarged deep upper cervical nodes as well as enlarged mediastinal and right hilar lymph nodes. The scan also revealed significant hepatosplenomegaly, bilateral pleural effusions and ascites (Fig. 1). Given this finding, the patient underwent a trans-jugular liver biopsy that showed mild inflammatory infiltrate in the portal tracts and bile duct damage containing occasional intraepithelial lymphocytes. It was thought that

Table 2
Calculation of H score in our patient (Fardet et al., 2014).

Feature	Result	Score
Known underlying immunosuppression	No	0
Maximal temperature	>39.4 °C	+49
Organomegaly	Hepatosplenomegaly	+38
Number of cytopenias	3 lineages	+34
Ferritin	>6,000 ug/L	+50
Triglyceride mmol/L	>4 mmol/L	+ 64
Fibrinogen	<2.5 g/L	+30
ALT	>30 U/L	+ 19
Haemophagocytosis on bone marrow	No	0
Total score		284

Table 3
Probability of HLH based on H score (table adapted from (Fardet et al., 2014)).

H score	Probability of HLH (%)
≤90	<1
91–110	1–3
111–130	3–9
131–150	9–25
151–170	25–54
171–190	54–80
191–210	80–93
211–230	93–98
231–240	98–99
>241	>99

Table 4
Important negative investigations.

Virology	
CMV serology	IgG positive, IgM negative
CMV PCR	900 copies/ml
Parvovirus serology	IgG positive, IgM negative
Adenovirus PCR	Negative
HIV serology	Antibody and p24 antigen negative
Parvovirus serology	IgG positive, IgM negative
Hepatitis A serology	Total antibody positive, IgM negative
Hepatitis E serology	IgG negative, IgM negative
Hepatitis E PCR	Negative
Hepatitis B serology	Hepatitis B surface antigen negative
Hepatitis C serology	Antibody negative
Respiratory throat swab	Negative for; influenza A&B, parainfluenza types 1–4, RSV, metapneumovirus, rhinovirus, seasonal coronavirus, adenovirus, parechovirus, enterovirus
Microbiology	
Syphilis serology	CMIA negative
Blood culture	Negative at 5 days
Urine culture	No growth
Gonorrhoea NAAT	Negative
Chlamydia NAAT	Negative
Toxoplasma serology	IgG negative, IgM negative
Malaria RDT	Negative
Malaria blood film	No parasites seen
Rheumatological	
ANA	Negative
ENA	Negative
Rheumatoid factor	Negative
Anti-CCP	Negative
Complement	C3 1.17, C4 0.41 (normal)
Immunoglobulins	IgA 1.31, IgM 0.60, IgG 11.12 (all normal)
Haematological	
Blood film	No immature cells. Features suggestive of infection/inflammation

given the clinical history, the findings of the appearances of the biopsy most likely represented EBV related damage.

A bone marrow biopsy was also conducted on day three however it did not show evidence of haemophagocytosis. Additionally, the flow cytometry sample showed no evidence for a haematological malignancy, although it indicated diminished granulocyte maturation. The trephine also showed no haemophagocytosis but demonstrated dysplastic megakaryocytes, reduced erythropoiesis and a T lymphocytosis with an EBV-positive small lymphocyte population.

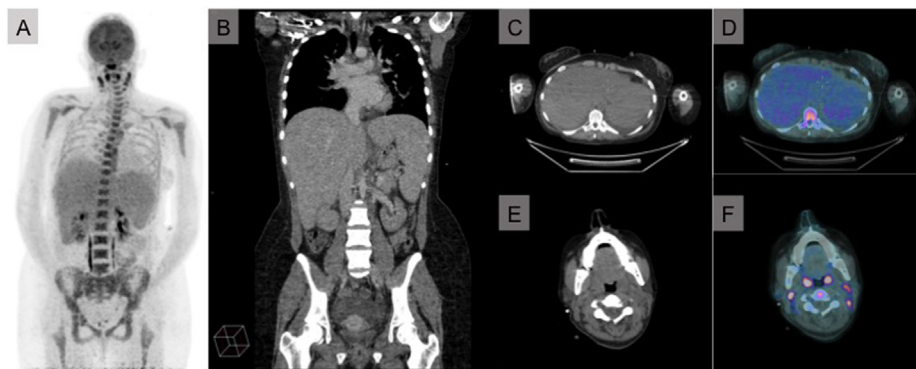

Fig. 1. Images from 18F FDG PET-CT. A. Maximum intensity projection (MIP) showing significant hepatosplenomegaly. B. Coronal view CT showing significant hepatosplenomegaly. C. & D. Axial view CT + 18F FDG PET-CT showing significant hepatosplenomegaly. E. & F. Axial view CT + 18F FDG PET-CT showing enlarged deep upper cervical lymph nodes.

In view of the above investigations, the main differential diagnosis for the patients HLH driver was presumed to be her primary EBV infection in the absence of no other clear diagnosis. In view of this, on day three the patient was given 800 mg of the monoclonal antibody rituximab in addition to the treatment listed above.

The patient clinically improved drastically on treatment and she was discharged to the ward after five days on the intensive care unit. Her ferritin levels began to decrease (Fig. 2) and the rest of her HLH diagnostic markers including triglycerides and fibrinogen slowly normalised. Furthermore, her EBV viral load reduced to 660 copies/ml by day nine. She was eventually discharged from hospital after sixteen days. Her discharge bloods are shown in Table 5.

Although the patient was still significantly anaemic on discharge, this slowly began to resolve and within one month her haemoglobin level returned to normal (Hb 144 g/L). Moreover, the doses of steroid and anakinra were slowly weaned and she was eventually discharged with a dose of 30 mg of oral prednisolone and 100 mg of subcutaneous anakinra once a day. This was eventually further tapered down and within twelve weeks she was taken off all medications and has remained asymptomatic. She remains well at one year post admission and continues to be monitored regularly in our outpatient rheumatology clinic.

Discussion

We report here the successful treatment of severe EBV-driven HLH with the IL-1 antagonist anakinra in addition to steroids, rituximab and IVIG.

HLH is a life-threatening syndrome characterised by hyperinflammation due to excessive immune activation. This is largely driven by activation of macrophages and dysregulation of cytotoxic T-cells causing unregulated cytokine release and cell tissue damage. Clinically, patients present with fevers, cytopenias, hyperferritinaemia, abnormal liver function and coagulopathy, which often leads to multi-organ failure. This syndrome is often difficult to differentiate from severe sepsis or other hyperinflammatory states and indeed many of the hallmarks of symptomatic EBV infection (fever, cytopenias, liver impairment) are similar to the characteristics of HLH. Diagnostic criteria, such as the ‘H score’ (Fardet et al., 2014) exist to aid diagnosis of HLH. In our patient, the H score on admission was extremely high, allowing prompt diagnosis of the condition.

HLH can be classified into primary (genetic) HLH or secondary (acquired) HLH. Primary HLH usually presents early in childhood and represents those cases where a genetic defect affecting immune response (usually T or NK cell) is found. Secondary HLH (sHLH) presents later in life and is caused by an underlying immunologic trigger, such as infection, autoimmune diseases or malignancy. EBV is a well-recognised infective trigger of secondary HLH (Rouphael et al., 2007; Marsh, 2018) but many other infections have also been implicated as triggers including CMV, HIV, mycobacteria and malaria. Non-infective triggers of secondary HLH include autoimmune diseases such as Still’s disease and haematological malignancies, most notably lymphoma.

Epstein-Barr virus (EBV) is a ubiquitous human herpes virus that is spread from person-person by saliva contact and establishes

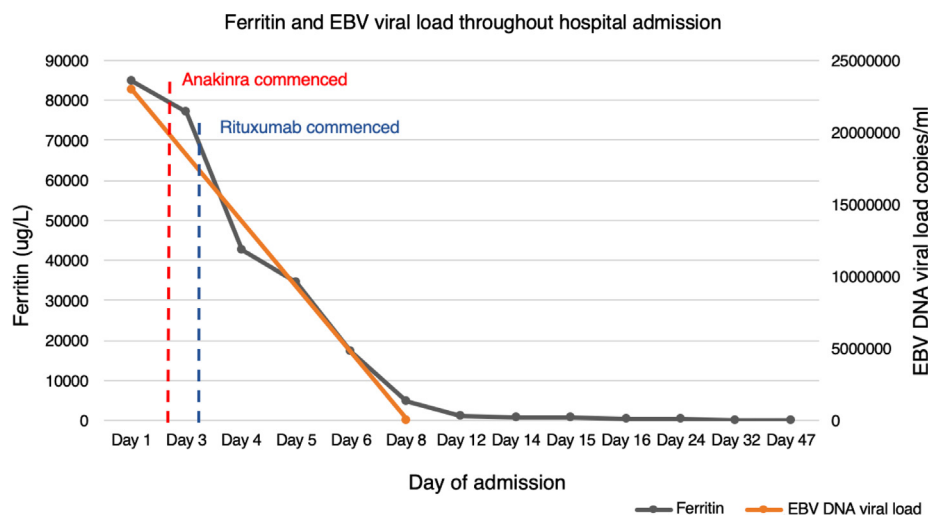


Fig. 2. Ferritin levels (ug/L) and EBV viral load (copies/ml) plotted over time from admission to hospital.

Table 5
Discharge blood tests.

Blood test	Result of day of discharge
Haemoglobin	84 g/L (115–155 g/L)
White cell count	$4.0 \times 10^9/L$ ($3.0\text{--}10.0 \times 10^9/L$)
Platelets	$241 \times 10^9/L$ ($150\text{--}400 \times 10^9/L$)
Creatinine	47 $\mu\text{mol/L}$ ($150\text{--}400 \times 10^9/L$)
Ferritin	593 $\mu\text{g/L}$ (13–150 $\mu\text{g/L}$)
Fibrinogen	1.57 g/L (1.5–4.0 g/L)
INR	1.02
APTT	23 secs (25–37 secs)
PT	11.2 secs (25–37 secs)
Bilirubin (total)	30 $\mu\text{mol/L}$ (0–20 $\mu\text{mol/L}$)
ALT	95 IU/L (10–35 IU/L)
Triglyceride	2.4 mmol/L (0.4–2.3 mmol/L)
CRP	1.1 mg/L (0–5.0 mg/L)

latency within B cells. By adulthood 90% of adults are seropositive for EBV. Most people are asymptotically infected as young children, but adolescents or adults infected in later life are more likely to have symptomatic primary EBV infection with a mononucleosis illness characterised by fevers, lymphadenopathy, sore throat and hepatitis. This is usually a self-resolving illness. However, in a small proportion of cases primary EBV infection persists and can trigger sHLH.

Once identified, HLH requires prompt treatment, as progression occurs rapidly and the mortality rate is high (Ramos-Casals et al., 2014). Treatment for secondary HLH encompasses immunosuppressive treatment to halt the cytokine storm, in addition to treatment of the underlying trigger to switch off the driver. Both arms of treatment are usually required for a good clinical response. Given the complexity of treatment a multi-disciplinary team including rheumatologists, haematologists and infectious disease specialists should be involved.

Evidence for the treatment of the cytokine storm in sHLH in adults is largely extrapolated from paediatric data using the HLH-1994 and HLH-2004 study protocols (Henter et al., 2007). This involves a combination of immunosuppressive agents to attempt to dampen down the hyperinflammatory response. Many different immunosuppressive agents have been used but most frequently used in the literature are high dose steroids, etoposide and cyclosporine.

A recent evidence based review discusses the role of the IL-1 receptor antagonist anakinra in management of HLH (Carter et al., 2019). Anakinra has shown efficacy in several retrospective studies (Simon et al., 2014; Sönmez et al., 2018) and appears to be safe and well-tolerated (Simon et al., 2014; Rajasekaran et al., 2014; Mehta et al., 2020). A benefit of anakinra in this context is that it appears to be safe when used in sepsis (Shakoory et al., 2016). This is particularly helpful in HLH, when infections are often the driver and there is clinical concern about administering potent immunosuppressive medications. With building evidence for its use in HLH, anakinra is increasingly considered as first line treatment (Mehta et al., 2020). This is the first report in the literature of its use in HLH secondary to primary EBV infection.

In our patient primary EBV infection was the identified trigger for secondary HLH. There are no licensed antivirals for treatment of EBV. However rituximab (a chimeric anti-CD20- monoclonal antibody) has frequently been used in EBV-associated HLH to deplete EBV-infected B-cells and therefore reduce the EBV viral

load. The effectiveness of EBV-loaded B-cell depletion with rituximab in EBV associated HLH has been demonstrated (Chellapandian et al., 2013). This study suggested improved survival in patients whose viral load dropped below 1500 copies/ml. In our patient rituximab was well tolerated and the viral load came down to 660 copies/ml from 23,000,000 copies/ml within 7 days.

In this case there was minimal response to initial sHLH treatment with high-dose steroids and IVIg. The addition of anakinra and rituximab caused a significant clinical improvement with associated improvement in all markers of hyperinflammation. It is likely that both treatments contributed to the improvement; anakinra by halting the cytokine storm and rituximab by reducing the driver by reducing the EBV viral load in B-cells.

This case shows that IL-1 inhibition with anakinra can be a safe and effective treatment for EBV-driven sHLH when used in combination with rituximab and conventional sHLH treatment.

Consent for publication

Written consent has been gained from the patient.

Declaration of Competing Interest

The authors declare that they have no known competing financial interests or personal relationships that could have appeared to influence the work reported in this paper.

References

- Carter, S.J., Tattersall, R.S., Ramanan, A.V., 2019. Macrophage activation syndrome in adults: Recent advances in pathophysiology, diagnosis and treatment. *Rheumatology (United Kingdom)*.
- Chellapandian, D., Das, R., Zelle, K., Wiener, S.J., Zhao, H., Teachey, D.T., et al., 2013. Treatment of Epstein Barr virus-induced haemophagocytic lymphohistiocytosis with rituximab-containing chemo-immunotherapeutic regimens. *Br. J. Haematol.*
- Fardet, L., Galicier, L., Lambotte, O., Marzac, C., Aumont, C., Chahwan, D., et al., 2014. Development and validation of the hscore, a score for the diagnosis of reactive hemophagocytic syndrome. *Arthritis Rheumatol.*
- Henter, J.L., Horne, A.C., Aricó, M., Egeler, R.M., Filipovich, A.H., Imshuku, S., et al., 2007. HLH-2004: Diagnostic and therapeutic guidelines for hemophagocytic lymphohistiocytosis. *Pediatric Blood and Cancer*.
- Marsh, R.A., 2018. Epstein-Barr virus and hemophagocytic lymphohistiocytosis. *Front. Immunol.*
- Mehta, P., Cron, R.Q., Hartwell, J., Manson, J.J., Tattersall, R.S., 2020. Silencing the cytokine storm: the use of intravenous anakinra in haemophagocytic lymphohistiocytosis or macrophage activation syndrome. *The Lancet Rheumatology*.
- Rajasekaran, S., Kruse, K., Kovey, K., Davis, A.T., Hassan, N.E., Ndika, A.N., et al., 2014. Therapeutic role of anakinra, an interleukin-1 receptor antagonist, in the management of secondary hemophagocytic lymphohistiocytosis/sepsis/multiple organ dysfunction/macrophage activating syndrome in critically ill children. *Pediatr. Crit. Care Med.*
- Ramos-Casals, M., Brito-Zerón, P., López-Guillermo, A., Khamashta, M.A., Bosch, X., 2014. Adult haemophagocytic syndrome. *The Lancet*.
- Rouphael, N.G., Talati, N.J., Vaughan, C., Cunningham, K., Moreira, R., Gould, C., 2007. Infections associated with hemophagocytic syndrome. *Lancet Infect. Dis.*
- Shakoory, B., Carcillo, J.A., Chatham, W.W., Amdur, R.L., Zhao, H., Dinarello, C.A., et al., 2016. Interleukin-1 receptor blockade is associated with reduced mortality in sepsis patients with features of macrophage activation syndrome: reanalysis of a prior phase III trial. *Crit. Care Med.*
- Simon, D.W., Aneja, R., Carcillo, J.A., Halstead, E.S., 2014. Plasma exchange, methylprednisolone, IV immune globulin, and now anakinra support continued PICU equipoise in management of hyperferritinemia-associated sepsis/multiple organ dysfunction syndrome/macrophage activation syndrome/secondary hemophagocytic lym. *Pediatric Critical Care Med.*
- Sönmez, H.E., Demir, S., Bilginer, Y., Özen, S., 2018. Anakinra treatment in macrophage activation syndrome: a single center experience and systemic review of literature. *Clin. Rheumatol.*