

DR. QADEER ARSHAD (Orcid ID : 0000-0002-6849-6685)

DR. INDRAN DAVAGNANAM (Orcid ID : 0000-0002-0363-1911)

DR. DIEGO KASKI (Orcid ID : 0000-0002-0591-646X)

Article type : Short Communication

TITLE PAGE

TITLE: PREVALENCE OF ACUTE DIZZINESS AND VERTIGO IN CORTICAL STROKE

Running title: Acute vertigo in cortical stroke

Authors: Yuk Man Chan *¹, Yean Wong *², Noorulain Khalid¹, Stephen Wastling², Andreas Flores-Martin³, Lucy-Anne Frank¹, Nehzat Koochi N^{1,4,5}, Qadeer Arshad⁶, Indran Davagnanam⁷, Diego Kaski^{1,4,5}.

* These authors contributed equally

Affiliations

1 Centre for Vestibular and Behavioural Neuroscience, Department of Clinical and Movement Neurosciences, Institute of Neurology, University College London, London WC1N 3BG, UK.; 2 Lysholm Department of Neuroradiology, National Hospital for Neurology and Neurosurgery, Queen Square, WC1N 3BG, UK.; 3 Academic Department of Neurosciences, Royal Hallamshire Hospital and University of Sheffield, Sheffield, UK.; 4 The Ear Institute, University College London, London WC1X 8EE, UK; 5 Neuro-otology Department, University College London Hospitals, London WC1E 6DG, UK; 6 inAmind Laboratory, Department of Psychology, Neuroscience and Behaviour, University of Leicester, Leicester, UK; 7 Brain Repair & Rehabilitation Department, Queen Square Institute of Neurology, UCL, London, UK.

This article has been accepted for publication and undergone full peer review but has not been through the copyediting, typesetting, pagination and proofreading process, which may lead to differences between this version and the [Version of Record](#). Please cite this article as [doi: 10.1111/ene.14964](https://doi.org/10.1111/ene.14964)

This article is protected by copyright. All rights reserved

Corresponding author:

Professor Diego Kaski, Centre for Vestibular and Behavioural Neurosciences, Department of Clinical and Motor Neurosciences, UCL, 33 Queen Square, London WC1N 3BG Tel: +44 20 3448 3135 Fax: +44 20 3448 4775 email: d.kaski@ucl.ac.uk

Figures: 1

Tables: 1

Appendices: 1

Word count: 1443

Keywords: Acute vertigo; stroke, vestibular; dizziness; cortical

ABSTRACT

Background

In posterior circulation stroke, vertigo can be a presenting feature. However, whether isolated hemispheric strokes present with vertigo is less clear, despite a few single case-reports in the literature. Here we, a) explored the prevalence of vertigo/dizziness in acute stroke and, b) considered the cortical distribution of these lesions in relation to both the known vestibular cortex and evolution of these symptoms.

Methods

We conducted structured interviews in 173 consecutive unselected patients admitted to the hyperacute stroke unit at the University College London Hospitals. The interview was used to evaluate whether the patient was suffering from dizziness and/or vertigo before the onset of the stroke and at the time of the stroke (acute dizziness/vertigo), and the nature of these symptoms.

Results

112 patients had subcortical lesions and 53 patients had cortical infarcts, of which 21 patients reported acute dizziness. Out of these 21, five patients reported rotational vertigo. 17 of the total 53 patients had lesions in known vestibular cortical areas distributed within the insular and parietal opercular cortices.

Conclusions

The prevalence of vertigo in acute cortical strokes was 9%, with no single locus of lesion overlap. There is growing evidence supporting a lateralised vestibular cortex, with speculation that cortical strokes affecting the right hemisphere, are more likely to cause vestibular symptoms than left-hemispheric strokes. We observed a trend for this association, with the right hemisphere affected in four of five patients who reported spinning vertigo at the onset of the stroke.

INTRODUCTION

Vertigo is defined as the illusionary sensation of self-motion (1), whereas dizziness more broadly represents disturbed spatial orientation without an illusion of motion (1). Vertigo and dizziness may be early presenting symptoms of acute stroke, most commonly of the posterior circulation, leading to an acute vestibular syndrome (2).

Previous work suggests that in patients with stroke, vertigo and dizziness presents in between 2.7% and 3.2% of all patients (3). Notably though in all cases of vertigo/dizziness – the strokes affected the posterior circulation, confirming the widely-held notion that cortical lesions typically do not cause vertigo (4), although it must be noted that single case reports of isolated hemispheric strokes presenting with vertigo have been reported (5).

Clinical experience and inferences from electrophysiological work in animals and humans, intimates a widespread vestibular cortex, with a core node converging upon the tempo-parietal junction. Indeed, recent coordinate-based activation likelihood estimation (ALE) meta-analysis have revealed vestibular activations mainly in the bilateral insula, retroinsular cortex, inferior parietal lobule, superior temporal gyrus, the caudal part of the anterior cingulate gyrus, and the precuneus (6).

Accordingly, here we propose to clarify the issue of the prevalence of vertigo/dizziness in acute stroke as well as consider the cortical distribution of these lesions in relation to both the known vestibular cortex and evolution of symptoms.

METHODS

Participants

We conducted structured interviews in consecutive unselected adult patients admitted to the hyperacute stroke unit (HASU) in University College London Hospitals (UCLH) between June 2018 and March 2020, with a confirmed clinical diagnosis of stroke (following daily Stroke Consultant

review). Patients underwent a detailed examination as part of the stroke assessment that included the head impulse test, examination for nystagmus, skew deviation, and Dix-Hallpike manoeuvres. We conducted the interviews within one week of stroke symptom onset. Patients who were unable to recall symptoms just prior to the onset of the stroke were excluded from this study. Patients with cognitive dysfunction (mini-mental state examination $<24/30$, dysphasia (as assessed by the stroke team), or unable to communicate in English despite the presence of a carer were excluded from the study. Patients with a history of pre-existing stroke as determined using the structured questionnaire, clinical history, and imaging findings were excluded from further analysis.

Questionnaire

The interview was based on a questionnaire (Appendix 1) designed to evaluate whether the patient was suffering from dizziness 1) before the onset of the stroke, 2) at the time of the stroke and 3) since the onset of the stroke. The questionnaire was validated in a cohort of 45 outpatient dizziness patients (mean age 56yrs SD ± 31 yrs) and 35 healthy controls (mean age 59yrs, SD ± 19). Either one of three individuals, trained in data acquisition (AFM, YMC, LAF), acquired the questionnaire data in a standardized fashion within seven days of stroke onset. All questions were asked sequentially (i.e. even for a 'no' response to 'dizziness' or 'vertigo' symptoms, researchers would explore the presence of associated vestibular symptoms). Questions explored a range of vestibular symptoms including vertigo, dizziness, unsteadiness, and spatial disorientation, in addition to 'light-headedness' and 'faint' sensations that are less specific for vestibular dysfunction. Only 'vertigo' was considered a specific vestibular symptom (1).

Imaging acquisition

The MRI of the participants who were consecutively interviewed was obtained on 1.5T or 3T Siemens (Erlangen, Germany) MRI. Using Carestream (Rochester, New York) Picture Archiving and Communication System (PACS), the MRI studies were retrospectively analysed by experienced consultant neuroradiologists and subsequently independently reviewed for inclusion for analysis by a radiologist (YW) blinded to the questionnaire results. Cases without appropriate MRI sequences or acute infarct on MRI were excluded from the analysis.

Imaging processing and analysis

After extracting and anonymising the DICOM data using DicomCleaner (PixelMed), the regions of acute stroke were identified on the DWI/ADC sequences and segmented on ITK-SNAP (University of Pennsylvania, Pennsylvania). This was followed by automated registration of the segmented regions of interest to the standard Montreal Neurological Institute (MNI) space, by utilising the FMRIB's Linear Image Registration Tool (FLIRT, FMRIB, Oxford). The Harvard-Oxford cortical and subcortical structural atlases (FMRIB, Oxford) were then used to record the anatomy of the regions of interest represented in MNI space.

By referring to the read-outs of anatomical sites of acute infarcts, only cases with involvement of the supratentorial cortex were included for the final analysis. Cases where there was any involvement of the infratentorial structure or deep grey matter were excluded.

RESULTS

In total, 173 patients completed questionnaires. Of these, 120 patients were excluded from further analysis due to incorrect patient details (n=4), questionable conscious level (2), duplicate patient (1), missing MRI data (42), negative for acute infarct on DWI (11), misregistration using FLIRT (25), absence of cortical involvement (17), and involvement of deep grey and infratentorial structures (18). The remaining 53 patients had supratentorial cortical infarcts with appropriate imaging registration for further analysis. Demographic details and symptoms prevalence of these patients are displayed in Table 1. None of the patients with confirmed cortical strokes were found to have additional vestibular disorders at the time of the acute stroke based on clinical examination.

Of 53 patients with supratentorial cortical infarcts, 21 patients reported acute dizziness. A feeling of unsteadiness was the most common vestibular symptom among patients reporting 'dizziness' (Table 1). Of the 21 patients, who had acute dizziness, only five reported rotational vertigo. 12 patients reported spatial disorientation (Table 1), but this was always associated with at least one other

vestibular symptom. Notably, 17 out of 53 patients with supratentorial cortical infarcts had lesions in areas recognised to be core vestibular cortical regions (6) distributed within the insular and parietal opercular cortices. Eight of these patients had acute dizziness of whom two reported acute vertigo.

The distribution of strokes in the 21 patients with dizziness did not differ compared to patients without dizziness symptoms (Figure 1a & b). In the 16 patients who reported dizziness but no vertigo, there was no hemispheric dominance (left hemisphere lesion, n=7; right, n=7; bilateral, n=2). Amongst the five patients who had vertigo, the regions of infarcts are predominantly distributed in the right hemisphere (n=4; Figure 1c & d), and in 75% of these, a lesion overlap in the right parietal lobule, supramarginal gyrus and postcentral gyrus was observed.

DISCUSSION

Vertigo was present in 9% of patients with acute cortical strokes, with no single locus of lesion overlap (n=5; Figure 1d). The prevalence of dizziness/vertigo in patients with cortical strokes in our cohort was 40% and thus higher than those previously reported; across a sample of 112 supratentorial stroke patients (7) there were no patients with spinning vertigo, and in a study of 668 stroke cases, only eight patients demonstrated vestibular symptoms (8). In these studies, the measure of rotational vertigo and dizziness also relied on subjective recall of an “illusory self-spinning sensation”, likely accounting for low prevalence rates. Unsteadiness was a common cause of such dizziness, being a less specific feature of vestibular dysfunction, its inclusion in our questionnaire may account for the larger prevalence of dizziness reported compared to previous studies.

Such variability in the prevalence of vestibular symptoms in stroke forces us to reconsider the validity of binary “Yes”/“No” questions in the acute setting. A novel framework that focuses on the timing and triggers of the symptoms, rather than a more accurate description of the percept itself, has been proposed [TiTrATE-Test method (9)]. Our data endorses such an approach given the inherent variability in subjective reports of dizziness in the acute setting.

Dieterich & Brandt (10) determined the ischaemic areas of the 10 published cases of vertigo following acute cortical stroke and observed that overlap areas were located either in the posterior retroinsular cortex (n = 8) or the separate parietal vestibular cortex (n = 2). They proposed that cortical vertigo is mostly elicited by acute lesions of the retroinsular vestibular network, and that the absence of vertigo when this area affected is explained by suppression of vertigo via the unaffected opposite hemisphere, supporting an interhemispheric account of vestibulo-cortical control (11).

Whilst such an explanation may account for the low prevalence of rotational vertigo in our cohorts, our radiological findings argue for a more widespread network that extends beyond the retroinsular cortex and may account for the range of vestibular perceptions reported in our patient cohort, as well as the higher rates of ‘dizziness’ observed. Supporting this are the results of a seminal stimulation study, whereby they observed that vestibular responses were identified in seven patients out of 108 temporal explorations, but only rarely (6.5%) by temporo-parietal stimulations (12). From a practical standpoint, we show that acute vertigo is not specific to brainstem stroke, and this has wider implications for the triaging of patients with acute neurological presentations and symptoms. None of the patients with cortical stroke however presented with *isolated vertigo*; as such patients with acute isolated vertigo are more likely to have posterior fossa or inner ear pathologies. Of note, spatial disorientation was always accompanied by at least one other vestibular symptom.

Lopez et al. (6) performed a statistical analysis of the localization of the human vestibular cortex and found that the main regions activated by caloric and galvanic stimulation are located in the Sylvian fissure, insula, retro-insular cortex, fronto-parietal operculum, superior temporal gyrus, and cingulate cortex. Based on fMRI and cytoarchitectonic mapping, Eickhoff et al. (13) hypothesized that the core human vestibular cortex is an area they call OP 2, located deep within the Sylvian fissure at the junction of the posterior parietal operculum with the insular/retro-insular region. However, a unilateral lesion of this region may not influence vestibular information processing and symptom generation, as some other intact vestibular cortical areas may assume a compensatory role. Recently, Baier et al. (14) reported no vestibular symptoms in ten patients with posterior insular cortex stroke, in accordance with our data.

There is growing evidence supporting a lateralised vestibular cortex, with speculation that cortical strokes affecting the right (dominant) hemisphere (in right-handed individuals), are more likely to cause vestibular symptoms than left-hemispheric strokes. We observed a trend for this association, with the right hemisphere affected in four of five patients who reported spinning vertigo at the onset of the stroke.

We conclude that acute vertigo is an uncommon consequence of cortical stroke, but can occur particularly following right hemisphere stroke, adding to the argument that there is no single vestibular cortex, but instead that the processing of vestibular signals is mediated by a network, that is likely to be lateralised to the right hemisphere.

ACKNOWLEDGMENTS

We thank the patients for participating in the study.

AUTHOR CONTRIBUTIONS

Study concept and design: QA, DK. Data collection: YKC, YW, AFM, LAF, NK. Drafting the manuscript: YMC, YW, NK, ID, QA, DK. Data interpretation: all authors. Critical revision of the manuscript: all authors.

FUNDING

DK is supported by a grant from the Meniere's Society and by the National Institute for Health Research University College London Hospitals Biomedical Research Centre.

DATA AVAILABILITY

Data will be shared upon reasonable request from any qualified investigator, while maintaining anonymisation of the patients.

COMPLIANCE WITH ETHICAL STANDARDS

Disclosure

None

Ethics approval and participant consent

REFERENCES

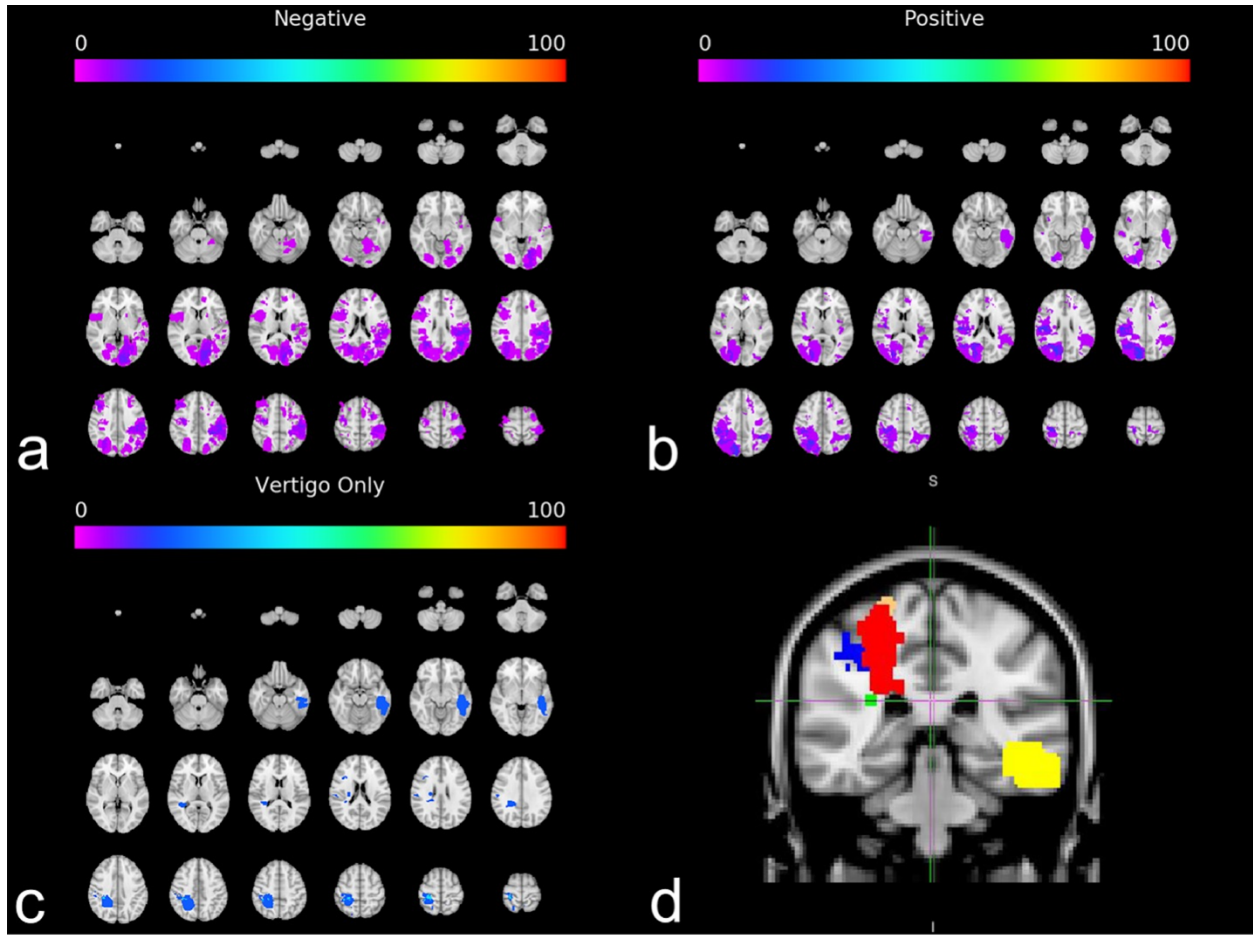
1. Bisdorff, M., von Brevern, T., Lempert, D.E., Newman-Toker D (2009) Classification of vestibular symptoms: towards an international classification of vestibular disorders *J Vestib Res*, 19:1-13.
2. Banerjee G, Stone SP, Werring DJ (2018) Posterior circulation ischaemic stroke. *BMJ* 361:k1185.
3. Kerber KA, Brown DL, Lisabeth LD, Smith MA, Morgenstern LB (2006) Stroke among patients with dizziness, vertigo, and imbalance in the emergency department: A population-based study', *Stroke* 37:2484–2487.
4. Dieterich M, Brandt T (2015) Why acute unilateral vestibular cortex lesions mostly manifest without vertigo. *Neurology* 84:1680-4.
5. von Brevern M, Süßmilch S, Zeise D (2014) Acute vertigo due to hemispheric stroke: a case report and comprehensive review of the literature. *J Neurol Sci* 339:153-6.
6. Lopez C, Blanke O, Mast FW (2012) The human vestibular cortex revealed by coordinate-based activation likelihood estimation meta-analysis. *Neuroscience* 212: 159–179.
7. Anagnostou E, Spengos K, Vassilopoulou S, Paraskevas GP, Zis V, Vassilopoulos D (2010) Incidence of rotational vertigo in supratentorial stroke: a prospective analysis of 112 consecutive patients. *J Neurol Sci* 290:33-6.
8. Eguchi S, Hirose G, Miaki M (2019) Vestibular symptoms in acute hemispheric strokes. *J Neurol* 266:1852-1858.
9. Newman-Toker DE, Edlow JA (2015) TiTrATE: A Novel, Evidence-Based Approach to Diagnosing Acute Dizziness and Vertigo. *Neurologic Clinics* 33: 577–599.
10. Dieterich M, Brandt T (2008) Functional brain imaging of peripheral and central vestibular disorders. *Brain* 131:2538–2552.
11. Arshad Q (2017) Dynamic interhemispheric competition and vestibulo-cortical control in humans; A theoretical proposition. *Neuroscience* 353:26-41.
12. Penfield W, Jasper H (1954) *Epilepsy and the functional anatomy of the human brain*. Little Brown, Boston.
13. Eickhoff SB, Weiss PH, Amunts K, Fink GR, Zilles K (2006), Identifying human parieto-insular vestibular cortex using fMRI and cytoarchitectonic mapping. *Hum. Brain Mapp* 27: 611-621.

14. Baier B, Conrad J, Zu Eulenburg P, Best C, Müller-Forell W, Birklein F, Dieterich M (2013)
Insular strokes cause no vestibular deficits. Stroke 44:2604-6.

Table 1: Demographic, lesion location and prevalence of dizziness symptoms in 53 patients with confirmed acute cortical strokes.

Median Age yrs (range)	73 (22-98)			
Male/Female	31/22			
Lesion location (hemisphere)	Right	Left	Both	Total
	21 (40%)	27 (51%)	5 (9%)	53
Dizziness symptoms				
Vertigo	3	1	1	5
Tilt	3	2	0	5
Lost/disoriented	5	6	1	12
Lightheaded	3	3	1	7
Faint	3	2	1	6
Unsteady	7	5	3	15
Loss of balance and fall	5	3	1	9

Figure 1 Lesion overlay map showing the locations of acute cortical infarcts in 53 patients on 2mm MNI brain atlas. Of these, (a) 32 patients did not report any symptoms of dizziness, (b) 21 patients were positive for symptoms of acute dizziness and (c) five patients (out of the 21 patients who had acute dizziness) reported rotational vertigo. The colour scale represents the percentage of subjects that had a lesion in the represented area on the map. All three groups had lesions widespread across the cortex, with no clear correlation between vertigo symptoms and involvement of the vestibular cortex. (d) Composite of lesion distribution of the five patients with vertigo. Each patient is represented by a different colour. Four out of five patients had predominantly right-sided lesions.



ene_14964_f1.tif