



5-20-2021

## Operative Management of Symptomatic, Metachronous Carotid Body Tumors Involving the Skull Base and Its Neurological Sequelae


Roberto G. Aru  
*University of Kentucky, robbiearu@uky.edu*

Rony K. Aouad  
*University of Kentucky, rony.aouad@uky.edu*

Justin F. Fraser  
*University of Kentucky, jfr235@uky.edu*

Amanda M. Romesberg  
*University of Kentucky, amanda.romesberg@uky.edu*

Kevin W. Hatton  
*University of Kentucky, kwhatt2@uky.edu*  
Follow this and additional works at: [https://uknowledge.uky.edu/otolaryngology\\_facpub](https://uknowledge.uky.edu/otolaryngology_facpub)

 Part of the [Anesthesiology Commons](#), [Otolaryngology Commons](#), [Radiology Commons](#), and the [Surgery Commons](#).  
*See next page for additional authors*

[Right click to open a feedback form in a new tab to let us know how this document benefits you.](#)

### Repository Citation

Aru, Roberto G.; Aouad, Rony K.; Fraser, Justin F.; Romesberg, Amanda M.; Hatton, Kevin W.; and Tyagi, Sam C., "Operative Management of Symptomatic, Metachronous Carotid Body Tumors Involving the Skull Base and Its Neurological Sequelae" (2021). *Otolaryngology--Head & Neck Surgery Faculty Publications*. 17.

[https://uknowledge.uky.edu/otolaryngology\\_facpub/17](https://uknowledge.uky.edu/otolaryngology_facpub/17)

This Article is brought to you for free and open access by the Otolaryngology--Head & Neck Surgery at UKnowledge. It has been accepted for inclusion in Otolaryngology--Head & Neck Surgery Faculty Publications by an authorized administrator of UKnowledge. For more information, please contact [UKnowledge@lsv.uky.edu](mailto:UKnowledge@lsv.uky.edu).

---

## Operative Management of Symptomatic, Metachronous Carotid Body Tumors Involving the Skull Base and Its Neurological Sequelae

Digital Object Identifier (DOI)

<https://doi.org/10.1016/j.jvscit.2021.04.018>

### Notes/Citation Information

Published in *Journal of Vascular Surgery Cases and Innovative Techniques*, v. 7, issue 3.

© 2021 The Author(s)

This is an open access article under the CC BY-NC-ND license (<https://creativecommons.org/licenses/by-nc-nd/4.0/>).

### Authors

Roberto G. Aru, Rony K. Aouad, Justin F. Fraser, Amanda M. Romesberg, Kevin W. Hatton, and Sam C. Tyagi

# Operative management of symptomatic, metachronous carotid body tumors involving the skull base and its neurological sequelae

Roberto G. Aru, MD,<sup>a</sup> Rony K. Aouad, MD,<sup>b</sup> Justin F. Fraser, MD,<sup>c</sup> Amanda M. Romesberg, DO,<sup>d</sup> Kevin W. Hatton, MD,<sup>e</sup> and Sam C. Tyagi, MD,<sup>a</sup> Lexington, Ky

## ABSTRACT

A 44-year-old morbidly obese woman with a history of right carotid body tumor (CBT) resection presented with a symptomatic, nonfunctional, left Shamblin-III CBT. Abutment of the skull base precluded distal internal carotid artery control for arterial reconstruction, favoring parent vessel sacrifice after an asymptomatic provocative test. She underwent CBT resection with anticipated sacrifice of cranial nerves X and XII and the common carotid artery and its branches, developing baroreceptor failure syndrome and sequelae of cranial nerve sacrifice. When facing a symptomatic, metachronous CBT abutting the skull base, upfront operative intervention with adjuvant radiation for residual tumor optimizes curative resection. (*J Vasc Surg Cases Innov Tech* 2021;7:378-81.)

**Keywords:** Carotid body tumor; Metachronous carotid body tumor; Cranial nerves deficit; Baroreceptor failure syndrome; Multidisciplinary care

## CASE REPORT

A morbidly obese 44-year-old woman presented with painful swelling in her left upper neck. She denied recent trauma, tobacco abuse, or family history of paragangliomas. She underwent excision of a right Shamblin-III carotid body tumor (CBT) with greater saphenous vein interposition graft at 17 years old. She was lost to follow-up and did not have surveillance duplex imaging, succinate dehydrogenase levels, or genetic evaluation. On physical examination, she had a tender left neck mass; cranial nerves (CNs) were intact, including CN X via flexible fiberoptic laryngoscopy. The lesion was nonfunctional with a normal serum normetanephrine level. Imaging (Fig 1) demonstrated a 6.2 cm, left, Shamblin-III CBT abutting the skull base. The patient declined radiation therapy because of claustrophobia and elected surgery despite the risks. A multidisciplinary discussion among Vascular Surgery, Otolaryngology, and Neurosurgery established that balloon test occlusion would determine the need for internal carotid artery (ICA)-external carotid artery (ECA) bypass, with anticipation of parent vessel sacrifice if

successful because distal ICA control was prohibitive for arterial reconstruction. After successful balloon test occlusion (Fig 2), the ICA and ECA branches were embolized with Amplatzer plugs (St. Jude Medical, St. Paul, Minn) and Target 360 soft and ultra coils (Stryker, Kalamazoo, Mich), respectively. The patient was placed on aspirin 81 mg monotherapy, and after 3 weeks, she remained asymptomatic without cerebrovascular events. She then underwent a transcervical CBT resection with anticipated sacrifice of CNs X and XII, the left internal jugular vein, and the common carotid artery and its branches (Fig 3). Estimated blood loss was 1 L. Pathology confirmed the diagnosis of a CBT. Intraoperatively, she developed baroreceptor failure syndrome (BFS) with hypertensive crisis evidenced by systolic blood pressure up to 220 mm Hg. She required intravenous antihypertensive and heart rate control medications over the next week, while she was transitioned to oral equivalents with a gradual wean to carvedilol. Further complications included acute respiratory failure due to aspiration requiring reintubation, dysphonia due to unilateral vocal cord paralysis managed with vocal cord augmentation that restored her voice, and dysphagia requiring gastrostomy-tube placement. On postoperative day 41, she was discharged home with continued oral treatment for BFS. She has been recovering slowly but remains gastrostomy-tube dependent, and she is still undecided regarding adjuvant radiation therapy and genetic consultation despite recommendations.

The patient provided written informed consent for patient information and images to be published.

## DISCUSSION

CBTs are the most common head and neck paragangliomas.<sup>1</sup> This rare pathology arises from the periadventitia of the carotid bifurcation. The carotid body maintains homeostasis of carbon dioxide, oxygen, and pH, whereas carotid baroreceptors in the carotid sinus regulate blood

From the Division of Vascular and Endovascular Surgery, Department of Surgery,<sup>a</sup> Department of Otolaryngology – Head and Neck Surgery,<sup>b</sup> Departments of Neurological Surgery, Neurology, Radiology, and Neuroscience,<sup>c</sup> Department of Radiology,<sup>d</sup> and the Division of Critical Care Medicine, Department of Anesthesiology,<sup>e</sup> University of Kentucky.

Author conflict of interest: none.

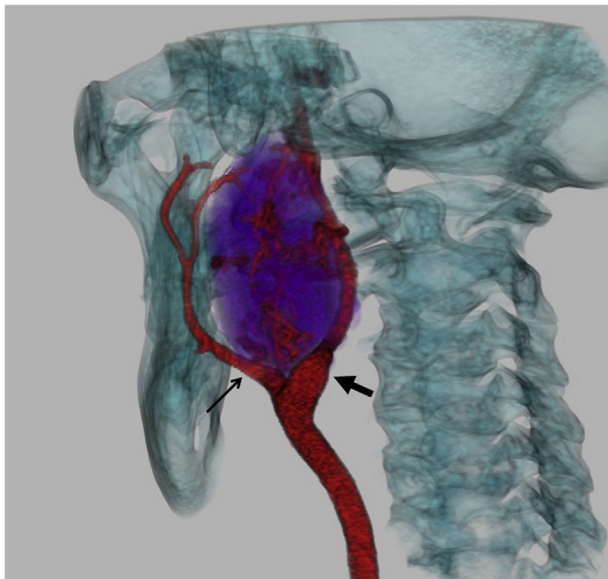
Correspondence: Roberto G. Aru, MD, Department of Surgery, University of Kentucky, 800 Rose St, MN 275, Lexington, KY 40536 (e-mail: [robbiearu@gmail.com](mailto:robbiearu@gmail.com)).

The editors and reviewers of this article have no relevant financial relationships to disclose per the Journal policy that requires reviewers to decline review of any manuscript for which they may have a conflict of interest.

2468-4287

© 2021 The Author(s). Published by Elsevier Inc. on behalf of Society for Vascular Surgery. This is an open access article under the CC BY-NC-ND license (<http://creativecommons.org/licenses/by-nc-nd/4.0/>).

<https://doi.org/10.1016/j.jvscit.2021.04.018>



**Fig 1.** 3D segmentation of a computed tomography angiography of the neck in left posterior oblique projection demonstrates a large vascular mass (purple) abutting the skull base and splaying the internal carotid artery (ICA) (thick arrow) and external carotid artery (ECA) (thin arrow). The splayed configuration of the ICA and ECA resembles a lyre.

pressure.<sup>2</sup> Symptomatic CBTs mandate operative resection that may be associated with significant morbidity. Bilateral synchronous CBTs occur in 7% to 11% of CBTs that can require staged bilateral resection, predisposing to BFS.<sup>2,3</sup> Our patient had a symptomatic metachronous, benign, Shamblin-III CBT abutting the skull base. She declined radiation therapy because of claustrophobia and elected for surgical intervention despite the risks, especially related to nerve sacrifice. She underwent preoperative embolization with subsequent extensive resection and carotid ligation without reconstruction, resulting in anticipated, permanent, and unilateral vagus and hypoglossal nerve deficits as well as transient hypertensive crisis due to BFS. We approach CBTs with a multidisciplinary approach in order to optimize outcomes as described by Mohebbi et al.<sup>4</sup> Herein, we discuss our complications in this complex case as well as preoperative decision-making.

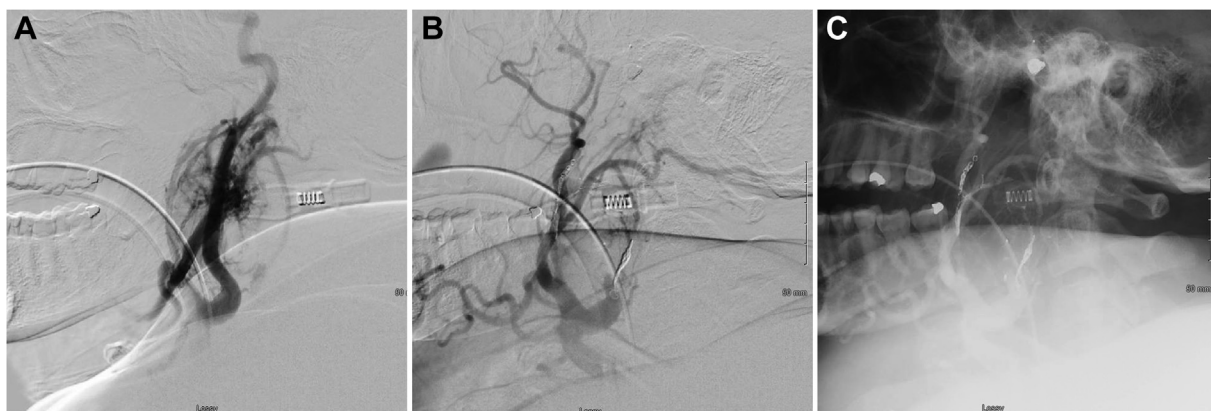
Cranial nerve injury (CNI) is a common complication after surgical resection of CBTs, resulting in significant morbidity in up to 40% of patients.<sup>5-7</sup> Patients most commonly experience deficits of the vagus (6%), hypoglossal (6%), and accessory (3%) nerves as well as the sympathetic chain (3%).<sup>1</sup> Clinical implications include hoarseness, dysphagia, dysgeusia, unilateral neck weakness, and Horner's syndrome. The Shamblin classification classically stratifies the degree of tumor encasement of the carotid arteries in order to predict the need for carotid reconstruction; a higher Shamblin classification is

associated with greater risk of CNI.<sup>8</sup> Other risk factors include bilateral resection, number of lymph nodes removed, distance to base of the skull, tumor volume, and estimated blood loss.<sup>2,8,9</sup> In our patient, her Shamblin-III CBT abutting the skull base encased the vagus and hypoglossal nerves, prohibiting preservation despite initial identification and preservation during surgery. Regarding dysphagia and dysphonia after vagus nerve sacrifice, young patients recover well with minimal dysfunction after vocal cord augmentation and therapy by the speech and swallow team. Furthermore, unilateral hypoglossal nerve paralysis has minimal effect on speech and swallowing as the contralateral nerve is enough for this function, despite the expected hemitongue atrophy.

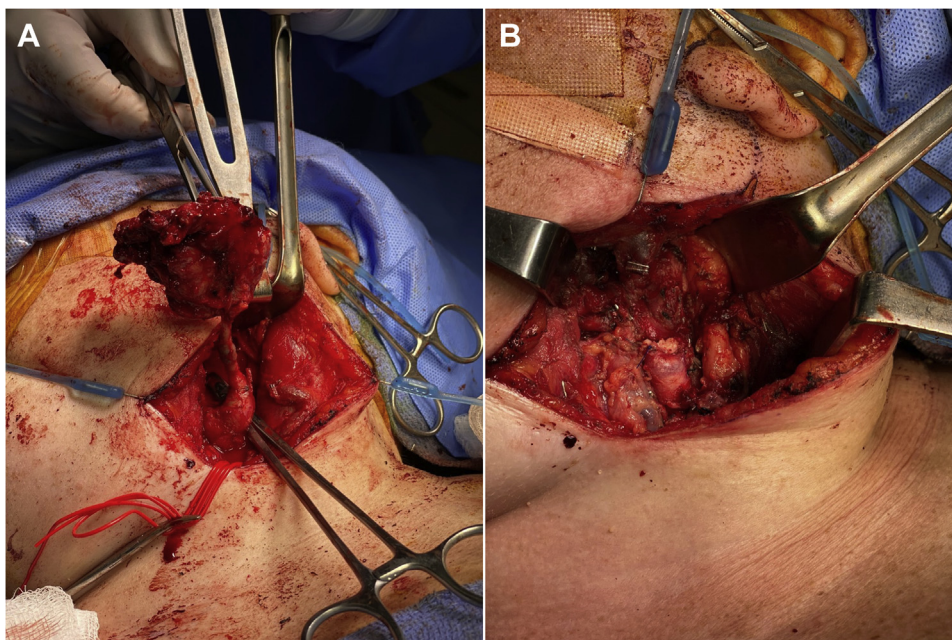
BFS is a well-documented sequela of bilateral CBT resection due to unopposed sympathetic brainstem signals from bilateral baroreceptor denervation.<sup>10,11</sup> Headache, anxiety, hypertension, and tachycardia classically characterize this morbidity,<sup>2,8,10-12</sup> and its spectrum ranges from hypertensive crisis to volatile hypertension and orthostatic tachycardia.<sup>3</sup> Hypertensive crisis develops acutely after bilateral resection with significant risk of a cerebrovascular event; volatile hypertension and orthostatic tachycardia are exceedingly more common presentations of BFS with a more gradual onset and more mild and permanent symptoms. A staged approach to resection of synchronous, bilateral tumors minimizes the incidence of this pathology, ranging from 0% to 16%.<sup>2,12</sup> Management typically includes clonidine and beta-blockers, counteracting the uninhibited sympathetic outflow.<sup>3,10</sup> In our case, an antihypertensive infusion acutely controlled the perioperative hypertensive crisis with gradual postoperative transition to oral antihypertensive and beta-blockade.

Management of metachronous, Shamblin-III CBTs abutting the skull base is an individualized decision as no standardized treatment algorithm exists. Treatment modalities include definitive radiation (XRT), neoadjuvant XRT with resection, and resection with adjuvant XRT for symptomatic CBTs, while observation is appropriate in asymptomatic lesions.<sup>10</sup> We discussed XRT given the significant anticipated morbidity with resection. XRT solely halts growth, but data on symptom control are lacking. Furthermore, there is a risk of secondary malignancies such as sarcomas. Continued symptoms after XRT mandates salvage surgical resection that may be more complex, and residual tumor after XRT is not appropriate for additional irradiation. Given the patient's claustrophobia in the setting of a large and symptomatic lesion, we felt that resection with adjuvant XRT for anticipated, residual tumor was the best treatment modality. This rationale guided our multidisciplinary decision for surgical resection in a young patient with a symptomatic CBT.

Tumor involvement of the ICA at the jugular foramen complicates CBT resection as it precludes ICA



**Fig 2.** **A**, Digital subtraction angiography (DSA) imaging with lateral view of the carotid system and carotid body tumor (CBT) preembolization of the internal (ICA) and external carotid arteries (ECA). **B**, Subtracted DSA imaging with lateral view post embolization of the ICA and ECA. **C**, Nonsubtracted DSA imaging with lateral view post embolization of the ICA and ECA.



**Fig 3.** Operative field during **(A)** and after **(B)** resection of left carotid body tumor (CBT).

reconstruction. Its incidence is rare in the setting of bilateral CBTs; two case series ( $n = 306$ ) describe this pathology only twice ( $<0.01\%$ ).<sup>1,13</sup> A described preoperative evaluation of neurovascular insufficiency involves manual compression of the common carotid artery for 30 minutes.<sup>7</sup> In our patient, a multidisciplinary approach assessed adequate cerebrovascular perfusion with ICA balloon occlusion via a published and standard technique.<sup>14</sup> Imaging confirmed patency of the contralateral autologous interposition graft. The patient underwent uncomplicated ICA and ECA coil embolization with subsequent carotid ligation without reconstruction. In

addition, preoperative embolization in CBTs is an adjunct to decrease intraoperative blood loss and CNI, although its efficacy is controversial.<sup>15,16</sup>

## CONCLUSIONS

Bilateral CBTs are a complex and rare pathology with high risk of operative morbidity. A symptomatic, metachronous, Shamblin-III CBT abutting the skull base in a young patient is a rare clinical scenario. Operative intervention requires thorough preoperative planning and a multidisciplinary approach, and surgical complications must be thoroughly discussed preoperatively.

## REFERENCES

1. Valero C, Ganly I, Shah JP. Head and neck paragangliomas: 30-year experience. *Head Neck* 2020;42:2486-95.
2. Bobadilla-Rosado LO, Garcia-Alva R, Anaya-Ayala JE, Peralta-Vazquez C, Hernandez-Sotelo K, Luna L, et al. Surgical management of bilateral carotid body tumors. *Ann Vasc Surg* 2019;57:187-93.
3. Cur I, Katz S. Baroreceptor failure syndrome after bilateral carotid body tumor surgery. *Ann Vasc Surg* 2010;24:1138.e1-e3.
4. Mohebbi J, Osborn HA, Schwartz SI, Ergul EA, Deschler DG, LaMuraglia GM. Multi-specialty surgical management of carotid body tumors in the modern era. *J Vasc Surg* 2021;73:2036-40.
5. Kruger AJ, Walker PJ, Foster WJ, Jenkins JS, Boyne NS, Jenkins J. Important observations made managing carotid body tumors during a 25-year experience. *J Vasc Surg* 2010;52:1518-23.
6. Lim JY, Kim J, Kim SH, Lee S, Lim YC, Kim JW, et al. Surgical treatment of carotid body paragangliomas: outcomes and complications according to the Shamblin classification. *Clin Exp Otorhinolaryngol* 2010;3:91-5.
7. Westerband A, Hunter GC, Cintora I, Coulthard SW, Hinni ML, Gentile AT, et al. Current trends in the detection and management of carotid body tumors. *J Vasc Surg* 1998;28:84-92.
8. Jiang X, Fang G, Guo D, Xu X, Chen B, Jiang J, et al. Surgical management of carotid body tumor and risk factors of postoperative cranial nerve injury. *World J Surg* 2020;44:4254-60.
9. Kim GY, Lawrence PF, Moridzadeh RS, Zimmerman K, Munoz A, Luna-Ortiz K, et al. New predictors of complications in carotid body tumor resection. *J Vasc Surg* 2017;65:1673-9.
10. Chali MGZ, Srinivasan VM, Hanna E, DeMonte F. Overt and subclinical baroreflex dysfunction after bilateral carotid body tumor resection: pathophysiology, diagnosis, and implications for management. *World Neurosurg* 2017;101:559-67.
11. Sugarbaker EV, Chretien PB, Jacobs JB. Bilateral familial carotid body tumors: report of a patient with an occult contralateral tumor and postoperative hypertension. *Ann Surg* 1971;174:242-7.
12. DeToma G, Nicolanti V, Plocco M, Cavallaro G, Letizia C, Piccirillo G, et al. Baroflex failure syndrome after bilateral excision of carotid body tumors: an underestimated problem. *J Vasc Surg* 2000;31:806-10.
13. Hallett JW, Nora JD, Hollier LH, Cherry KJ, Pairolero PC. Trends in the neurovascular complications of surgical management of carotid body and cervical paragangliomas: a fifty-year experience with 153 tumors. *J Vasc Surg* 1988;7:284-91.
14. Harrigan M, Deveikis JP. Provocative testing. In: Harrigan M, Deveikis JP, editors. *Handbook of Cerebrovascular Disease and Neurointerventional Technique*. 1st ed. Heidelberg: Springer; 2009. p. 179-204.
15. Power AH, Bower TC, Kasperbauer J, Link MJ, Oderich G, Cloft H, et al. Impact of preoperative embolization on outcomes of carotid body tumor resections. *J Vasc Surg* 2012;56:979-89.
16. Abu-Ghanem S, Yehuda M, Carmel NN, Abergel A, Fliss DM. Impact of preoperative embolization on the outcomes of carotid body tumor surgery: a meta-analysis and review of the literature. *Head Neck* 2016;38:E2386-94.

Submitted Feb 9, 2021; accepted Apr 26, 2021.