

SOCIETY FOR VASCULAR SURGERY® DOCUMENTS

Endovascular repair of traumatic thoracic aortic injury: Clinical practice guidelines of the Society for Vascular Surgery

W. Anthony Lee, MD,^a Jon S. Matsumura, MD,^b R. Scott Mitchell, MD,^c Mark A. Farber, MD,^d Roy K. Greenberg, MD,^e Ali Azizzadeh, MD,^f Mohammad Hassan Murad, MD, MPH,^g and Ronald M. Fairman, MD,^h *Boca Raton, Fla; Madison, Wis; Palo Alto, Calif; Chapel Hill, NC; Cleveland, Ohio; Houston, Tex; Rochester, Minn; and Philadelphia, Pa*

The Society for Vascular Surgery® pursued development of clinical practice guidelines for the management of traumatic thoracic aortic injuries with thoracic endovascular aortic repair. In formulating clinical practice guidelines, the Society selected a panel of experts and conducted a systematic review and meta-analysis of the literature. They used the Grading of Recommendations Assessment, Development and Evaluation methods (GRADE) to develop and present their recommendations. The systematic review included 7768 patients from 139 studies. The mortality rate was significantly lower in patients who underwent endovascular repair, followed by open repair, and nonoperative management (9%, 19%, and 46%, respectively, $P < .01$). Based on the overall very low quality of evidence, the committee suggests that endovascular repair of thoracic aortic transection is associated with better survival and decreased risk of spinal cord ischemia, renal injury, graft, and systemic infections compared with open repair or nonoperative management (Grade 2, Level C). The committee was also surveyed on a variety of issues that were not specifically addressed by the meta-analysis. On these select matters, the majority opinions of the committee suggest urgent repair following stabilization of other injuries, observation of minimal aortic defects, selective (vs routine) revascularization in cases of left subclavian artery coverage, and that spinal drainage is not routinely required in these cases. (*J Vasc Surg* 2011;53:187-92.)

Blunt traumatic thoracic aortic injury is associated with a high mortality rate, and has been implicated as the second most common cause of death in trauma patients, behind

From the Christine E. Lynn Heart and Vascular Institute, Boca Raton;^a Division of Vascular Surgery, University of Wisconsin, Madison;^b Department of Cardiothoracic Surgery, Stanford University, Palo Alto;^c Division of Vascular Surgery, University of North Carolina, Chapel Hill;^d Department of Vascular Surgery, Cleveland Clinic Foundation, Cleveland;^e Division of Vascular Surgery, University of Texas Houston Medical School, Houston;^f Division of Preventive, Occupational and Aerospace Medicine, Mayo Clinic, Rochester;^g and Division of Vascular Surgery, University of Pennsylvania, Philadelphia.^h Competition of interest: Dr Lee received research support and consultation fees from Cook, Medtronic, and Bolton Medical. Dr Matsumura has grants for research and training from Abbott, Cook, Covidien, Endologix, and W. L. Gore. Dr Mitchell has no conflict of interest disclosures. Dr Farber received consultant fees from W. L. Gore, Medtronic, Cook, Aptus Endosystems, and Bolton Medical. Dr Greenberg received research support from Cook and W. L. Gore. He has IP/License agreements with Cook. Dr Azizzadeh received consultation fees from Medtronic and W. L. Gore. Dr Murad has no conflict of interest disclosures. Dr Fairman received research support from Abbott, Medtronic, Cook, Aptus, and Boston Scientific.

Presented at the 2010 Vascular Annual Meeting of the Society for Vascular Surgery, June 10-13, 2010, Boston, Mass.

Reprint requests: W. Anthony Lee, MD, Director of Endovascular Program, Christine E. Lynn Heart and Vascular Institute, 670 Glades Road, Suite No 300 Boca Raton, FL 33431 (e-mail: walee@sapbc.net).

Independent peer-review and oversight has been provided by members of the SVS Document Oversight Committee (K. Wayne Johnston, MD (chair), Enrico Ascher, MD, Jack L. Cronenwett, MD, R. Clement Darling, MD, Vivian Gahtan, MD, Peter Glociczki, MD, Thomas F. Lindsay, MD, Gregorio A. Sicard, MD).

0741-5214/\$36.00

Copyright © 2011 by the Society for Vascular Surgery.

doi:10.1016/j.jvs.2010.08.027

only to intracranial hemorrhage.^{1,2} It has been estimated that less than 25% of patients with such an injury live to be evaluated in a hospital,³ and of those who do, up to 50% will die within 24 hours.⁴ Given the location of injury in 50% to 70% of cases,⁴ conventional surgical repair typically involves a high posterolateral thoracotomy with or without cardiopulmonary bypass and significant blood loss, which can negatively impact the pulmonary, cardiac, and neurologic status of the patient. Historically, open repair of traumatic aortic injuries has been associated with a 28% mortality rate⁵ and a 16% paraplegia rate.⁶ There has been a risk of delayed rupture in the unrepaired thoracic transection that has been estimated to be 2% to 5%.⁷

Thoracic endovascular aortic repair (TEVAR) is a rapidly evolving therapy in the treatment of a variety of thoracic aortic pathologies. TEVAR involves placing an endovascular stent graft into the thoracic aorta from a remote peripheral location under imaging guidance. TEVAR offers the potential for a durable aortic repair while avoiding the morbidity of a thoracotomy, aortic cross clamping, and cardiopulmonary bypass. Nevertheless, stroke, spinal cord ischemia, and other complications that are associated with open repair can also occur with TEVAR.

Although there is no device currently commercially available with an on-label indication for repair of traumatic thoracic aortic transections, these are increasingly being treated off-label using endovascular devices. At the time of this manuscript, there were at least two ongoing investigator device exemption (IDE) pivotal clinical trials in-

Table I. GRADE (Grading of Recommendations Assessment, Development, and Evaluation) system

<i>Strength of recommendation</i>	<i>Terminology</i>
Grade 1 (strong)	“We <u>recommend</u> . . .”
Grade 2 (weak)	“We <u>suggest</u> . . .”

<i>Quality of evidence</i>	<i>Source of evidence</i>
Level A (high quality)	Well conducted randomized trials.
Level B (moderate quality)	Less rigorous or inconsistent randomized trials.
Level C (low or very low quality)	Observational studies, case series, and unsystematic observations or expert opinion.

investigating the safety and efficacy of endovascular repair of traumatic thoracic aortic injuries. Despite the focal nature of these aortic injuries, which may appear to favor endograft repair, there remains a number of unresolved issues: (1) poor conformation to the arch, (2) frequent need to cover the left subclavian artery (LSA), (3) uncertain natural history of the repair given the younger age of trauma victims and the morphologic changes of the aorta that come with age, (4) optimal follow-up strategy that may span several decades and the risks of cumulative radiation exposure, (5) timing of repair, and (6) the need for intraoperative anticoagulation in the setting of polytrauma.

The Society for Vascular Surgery® (SVS) identified several key issues that require the development of clinical practice guidelines to aid surgeons, referring physicians, and patients in the process of decision making. Endovascular repair of traumatic thoracic aortic injuries was one of these areas. In developing these guidelines, the Society utilized similar processes and formats to their recently published guidelines.⁸ First, the Society selected a committee of experts in the field who possess knowledge of the clinical aspects as well as patients' values and preferences in this regard. Second, they commissioned the Knowledge and Encounter Research Unit, Mayo Clinic, Rochester, a third party with expertise in evidence-based medicine, knowledge synthesis, and guideline development to conduct a comprehensive systematic review of the literature and identify the best available evidence. The Society acknowledged the value of systematic reviews and meta-analyses since, compared with individual studies, they provide evidence that is more robust and more likely to be applicable to a wider range of patients. Third, the Society utilized the Grading of Recommendations Assessment, Development and Evaluation (GRADE) methods to develop and present their recommendations. The GRADE method provides superior clarity and separates the quality of evidence from the strength of recommendations. It also allows for the inclusion of patients' values and preferences in recommendations⁸ (Table I).

In this article, the committee presents the following recommendation with the aim of clarifying the role of TEVAR in the treatment of traumatic blunt aortic injuries. While there was diversity of individual opinions, the article

reflects the consensus of the committee. The recommendation is followed by the supporting evidence, a values statement, and relevant technical remarks. Detailed description of the data analysis is in the accompanying article.⁹

RECOMMENDATION BASED ON THE META-ANALYSIS

Prospective randomized trials directly comparing open vs endovascular repair of traumatic thoracic aortic injury are unavailable. Despite probable clinical equipoise, such a clinical trial will unlikely be conducted in a timely and successful manner. Therefore, based on the systematic review of the available literature presented in an article by Murad et al,⁹ the committee suggests that endovascular repair of traumatic thoracic aortic injuries be performed preferentially over open surgical repair or nonoperative management. This recommendation is based on very low quality evidence (Grade 2, Level C).

EVIDENCE

The systematic review commissioned by the Society included 7768 patients (77% males). The mean ages of patients treated nonoperatively and with endovascular or open repair were 39, 39, and 36 years, respectively. The mortality rate was significantly lower in patients who underwent endovascular repair, followed by open repair and nonoperative management (9%, 19%, and 46%, respectively, $P < .01$). The ISS correlated with mortality after open ($P = .01$) but not endovascular repair ($P = .68$). No significant difference in event rate across the three groups was noted for any stroke. The risk of spinal cord ischemia (SCI) and end stage renal disease (ESRD) was higher in open repair compared with endovascular repair and nonoperative management (SCI: 9% open vs 3% endovascular and 3% nonoperative, $P = .01$; ESRD: 8% open vs 5% endovascular and 3% nonoperative, $P = .01$). Compared with endovascular repair, open repair was associated with increased risk of graft infection and systemic infections, most commonly pneumonia. With a median follow-up of 2 years, there was a trend toward increased risk of a secondary procedure in endovascular compared with open repair ($P = .07$).

VALUES

In developing the recommendation that endovascular repair should be performed preferentially over open surgical repair or nonoperative management, the committee placed a significantly higher value on preventing catastrophic complications of thoracic aortic repair (death, stroke, and spinal cord ischemia) and a lower value on potential adverse events such as endoleak, need for reintervention, and device failures. The committee also placed less value on possible late-term outcomes that remain unknown at this time. Furthermore, the committee acknowledges the off-label use of a medical device in the context of endovascular repair of traumatic thoracic aortic injury, although there are ongoing studies investigating the safety and efficacy in this application; however, as we believe that pre-

Table II. Summary of guidelines for thoracic endovascular aortic repair (TEVAR) in traumatic thoracic aortic injuries

<i>Guideline</i>	<i>Consensus</i>	<i>Grade of recommendation</i> 1—strong 2—weak	<i>Quality of evidence</i> A—high B—moderate C—low or very low
Choice of treatment	We suggest that endovascular repair be performed preferentially over open surgical repair or nonoperative management.	2	C
Timing of repair	We suggest urgent (<24 hours) repair, and at the latest prior to hospital discharge.	2	C
Management of minimal aortic injury	We suggest expectant management with serial imaging for type I injuries.	2	C
Type of repair in the young patient	We suggest endovascular repair regardless of age if anatomically suitable.	2	C
Management of left subclavian artery	We suggest selective revascularization of the left subclavian artery.	2	C
Systemic heparinization	We suggest routine heparinization but at a lower dose than in elective TEVAR.	2	C
Spinal drainage	We do not suggest routine spinal drainage.	2	C
Choice of anesthesia	We suggest general anesthesia.	2	C
Femoral access technique	We suggest open femoral exposure.	2	C

venting death is paramount in this setting, the committee recommends endovascular repair.

CONSENSUS OF OPINION ON SELECT ISSUES

Endovascular repair of traumatic thoracic aortic injuries poses several unresolved or controversial issues whose supporting evidence lacks sufficient clarity in the literature due to cohort heterogeneity, size, and length of follow-up. Nevertheless, the committee sought to arrive at some consensus on a select number of these issues to offer guidance in actual clinical practice. To this end, a series of questions were used to survey the opinions of each committee member. Published evidence is provided in support of the majority and minority opinions when available. Using the GRADE system, all of the following opinions should be regarded as Grade 2, Level C statements (Table II).

Issue 1: Timing of TEVAR in a stable patient. The committee suggests urgent (<24 hours) repair barring other serious concomitant nonaortic injuries, or repair immediately after other injuries have been treated, but at the latest prior to hospital discharge.^{10,11} This is consistent with the available evidence in which mortality was 46% in those managed nonoperatively.⁹ While most did not favor discharge without repair, depending on the severity of the injury (see below), minority opinion was expressed that expectant management was appropriate with follow-up imaging.

Issue 2: Management of “minimal aortic injury” (periadventitial defect or hematoma). Intimal or periadventitial defects or hematomas are not infrequently seen on computed tomography (CT) scan. A classification scheme for grading the severity of aortic injury has been proposed: type I (intimal tear), type II (intramural hematoma), type III (pseudoaneurysm), and type IV (rupture)¹² (Fig). The committee suggests expectant management with serial imaging for type I injuries, while types II to IV should be repaired. This is based on early evidence that most type I

injuries heal spontaneously.¹² Decision to intervene and its timing should be guided by progression of the initial radiographic abnormality and/or symptoms.

Issue 3: Choice of repair in the young—TEVAR vs open. There was near unanimity of opinion that anatomic suitability is important for TEVAR but age should not be a factor in deciding the type of repair. The risks of death and spinal cord ischemia are significantly lower in all age groups after endovascular repair compared with open surgery,¹³⁻¹⁵ and these early benefits outweigh the concerns of potential late complications. However, in surgically fit patients with poor anatomy for endovascular repair, conventional open repair should be considered.

Issue 4: Suitability and the unmet needs of current FDA-approved thoracic endografts. With the availability of three commercially available devices, there was considerable divergence of opinion about the “best” device for use in traumatic thoracic aortic injury. There was a consensus, however, that arch conformation represented the single greatest unmet need given the curvature of the thoracic aorta at the location of the injury. Inability to conform to this curvature can result in malapposition of the endograft, which can lead to endoleak and endograft collapse.¹⁶ The aortic diameters are relatively smaller in the younger subset of trauma patients. Currently, available thoracic endograft sizes mostly reflect the larger aortic diameters that would be typically encountered in an older cohort with degenerative aneurysms. Excessive oversizing may result in attachment site endoleak, device infolding, endograft collapse, and even death from acute aortic occlusion.¹⁶ Endograft collapse represents a failure of the therapy and a marker of unsuitable anatomy, and open surgical conversion should be considered. No consensus could be reached regarding optimal oversizing for these cases, and opinions were equally divided among minimal to no oversizing, 5% to 10% oversizing, and standard oversizing per manufacturer’s recommendations. Historically, abdominal endograft compo-

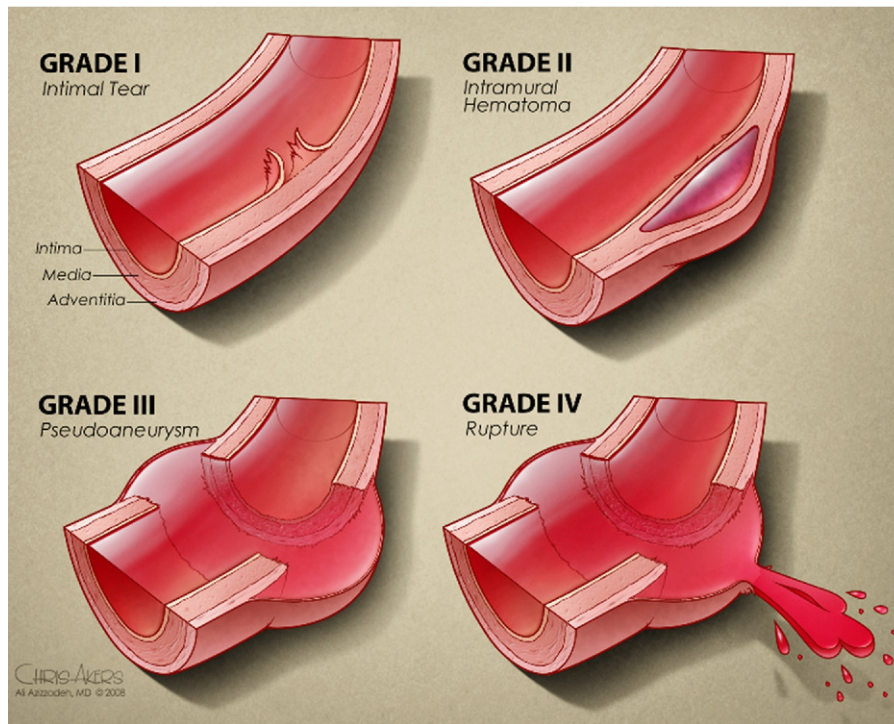


Fig. Classifications of traumatic aortic injury.¹²

nents such as proximal extension cuffs have been used when thoracic devices were either unavailable or anatomically unsuitable.^{17,18} Due to the shorter delivery systems, often these devices could not reach the site of injury from the femoral approach, which necessitated either use of a longer makeshift delivery system or access through a more proximal site. The lengths of extension cuffs are typically short, and this required multiple overlapping pieces. Such an intercalating construction allowed slightly improved conformation to the arch but at the same time introduced multiple junctions, which were potential sources of type III endoleaks.

A number of next generation devices are presently undergoing clinical trials that may address some of the unmet needs of this therapy. Cook (Bloomington, Ind) has recently introduced the Pro-Form delivery system that is intended to improve arch conformability, and in the near future the TX2 LP (low-profile), which will decrease the profile of the delivery catheter and broaden the range of available diameters. Medtronic (Santa Rosa, Calif) will introduce the Valiant thoracic endograft with the Captivia delivery system, which should enhance the stability and reliability of the deployment mechanism. W. L. Gore (Flagstaff, Ariz) is currently conducting clinical trials of their c (conformable)-TAG device, with which preliminary experience outside the United States appears to show improved arch conformability and greater tolerance to device oversizing.

Issue 5: LSA management during zone 2 coverage. There was near unanimity of opinion for selective revascu-

larization (either before or after TEVAR) depending on the status of the vertebral anatomy, with a minority opinion favoring routine revascularization.¹⁹ In the current meta-analysis,⁹ the LSA was covered in 30% of cases. Preservation of antegrade perfusion on the side of the dominant vertebral artery can specifically decrease the risk of posterior circulation strokes.²⁰ However, the urgency of the repair and the condition of the victim may preclude preoperative assessment. If the LSA is covered, intraoperative angiography of the right vertebral artery would allow the most expeditious assessment of the adequacy of the posterior circulation. If the right vertebral artery is atretic or hypoplastic with or without an intact Circle of Willis, the decision to revascularize the left subclavian artery must be individualized taking into account the availability of surgical expertise, condition of the patient, and other injuries.¹⁹

Issue 6: Systemic heparinization. The safety of systemic heparinization during endovascular repair in a multiply injured patient with a closed head injury or abdominal solid organ injury is a controversial issue. The majority of committee members indicated that they routinely use systemic heparin but at a lower dose than in elective TEVAR. A minority opinion was expressed that heparin may not be necessary as most of these cases can be performed relatively rapidly, and the risk of a thrombotic event is likely small.²¹ In the final analysis, the decision must be individualized based on the balance of the perceived risks of bleeding in a particular organ system vs the thromboembolic complications.

Issue 7: Spinal drainage. Spinal drainage has been the mainstay of management for spinal cord ischemia during TEVAR. The issue of prophylactic spinal drainage is controversial even for treatment of degenerative thoracic aneurysms and, to be sure, no data exist for traumatic injuries. SCI is a low-incidence event (3%) after TEVAR for traumatic injuries.⁹ Based on this and the proximal location of the injury, limited coverage of the thoracic aorta and the risk of epidural hematoma in a coagulopathic patient, there was unanimity of opinion that spinal drainage is not routinely indicated, and it should only be placed for symptoms of spinal cord ischemia.

Issue 8: Choice of anesthesia—general vs regional vs local. There was a strong consensus favoring general anesthesia. While it is possible to perform TEVAR under local anesthesia (minority opinion), unreliable cooperation of an agitated trauma patient and presence of concomitant injuries that may require additional surgery make this option less favorable.

Issue 9: Femoral access technique—open vs percutaneous. Nearly all of the committee members favored open femoral exposure in these cases to minimize potentially avoidable complications related to percutaneous closure of large bore access sites. On the other hand, “percutaneous TEVAR” using suture-mediated closure devices can be performed safely with low rates of early and late limb or life threatening events²² and there was a minority opinion, which favored this approach. In the emergent setting, percutaneous access can also refer to the actual insertion of the endovascular device without initial surgical exposure of the femoral artery. The artery is repaired after the endograft is deployed by surgical exposure, and removal of the delivery system under direct vision. This technique may allow a more rapid endograft delivery and repair in a hemodynamically unstable patient.

Issue 10: Optimal follow-up strategy. Given the concerns of cumulative radiation, iodinated contrast exposure, and late endograft collapse, the optimal strategy for long-term follow-up of these patients post-TEVAR remains in evolution. Opinions varied widely within the committee as to the frequency and types of imaging that should be utilized. In the absence of any abnormalities on imaging (ie, stable endograft position, no endoleak) in the first 12 to 36 months, some have suggested decreasing the frequency to 2 to 5 years, while others have expressed that, lacking any evidence to the contrary, follow-up for traumatic thoracic aortic injuries should be no different than those treated with TEVAR for other pathologies. There was, however, some consensus suggesting that a combination of a multi-view chest x-ray and a magnetic resonance angiography (MRA) may be preferable over conventional contrast computed tomographic angiography (CTA) for long-term imaging, with due consideration of the metallic composition of the endograft.

CONCLUSION

Although the quality of evidence is very low, TEVAR for traumatic thoracic aortic injury is associated with im-

proved outcomes compared with open repair, especially about its lower mortality and incidence of spinal cord ischemia. However, this finding should be tempered by the current lack of suitable devices that can accommodate the unique anatomy of these patients, which has occasionally resulted in severe procedure-related complications, and the unknown natural history of the endovascular repair and the optimal follow-up strategy.

AUTHOR CONTRIBUTIONS

Conception and design: WL

Analysis and interpretation: WL, JM, SM, MF, RG, AA, MM, RF

Data collection: WL, MM

Writing the article: WL

Critical revision of the article: WL

Final approval of the article: WL, JM, SM, MF, RG, AA, MM, RF

Statistical analysis: MM

Obtained funding: Not applicable

Overall responsibility: WL

REFERENCES

1. Clancy TV, Gary Maxwell J, Covington DL, Brinker CC, Blackman D. A statewide analysis of level I and II trauma centers for patients with major injuries. *J Trauma* 2001;51:346-51.
2. Richens D, Field M, Neale M, Oakley C. The mechanism of injury in blunt traumatic rupture of the aorta. *Eur J Cardiothorac Surg* 2002;21:288-93.
3. Fabian TC, Richardson JD, Croce MA, Smith JS Jr, Rodman G Jr, Kearney PA, et al. Prospective study of blunt aortic injury: multicenter trial of the American Association for the Surgery of Trauma. *J Trauma* 1997;42:374-80.
4. Jamieson WR, Janusz MT, Gudas VM, Burr LH, Fradet GJ, Henderson C. Traumatic rupture of the thoracic aorta: third decade of experience. *Am J Surg* 2002;183:571-5.
5. Cowley RA, Turney SZ, Hankins JR, Rodriguez A, Attar S, Shankar BS. Rupture of thoracic aorta caused by blunt trauma. A 15-year experience. *J Thorac Cardiovasc Surg* 1990;100:652-60.
6. Ott MC, Stewart TC, Lawlor DK, Gray DK, Forbes TL. Management of blunt thoracic aortic injuries: endovascular stents versus open repair. *J Trauma* 2004;56:565-70.
7. Tehrani HY, Peterson BG, Katariya K, Morasch MD, Stevens R, DiLuozzo G, et al. Endovascular repair of thoracic aortic tears. *Ann Thorac Surg* 2006;82:873-7.
8. Murad MH, Swiglo BA, Sidawy AN, Ascher E, Montori VM. Methodology for clinical practice guidelines for the management of arteriovenous access. *J Vasc Surg* 2008;48:26S-30S.
9. Murad MH, Rizvi AZ, Malgor R, Carey J, Alkatib AA, Erwin PJ, et al. Comparative effectiveness of the treatments for aortic transection: a systematic review and meta-analysis. *J Vasc Surg*
10. Demetriades D, Velmahos GC, Scalea TM, Jurkovich GJ, Karmy-Jones R, Teixeira PG, et al. Blunt traumatic thoracic aortic injuries: early or delayed repair—results of an American Association for the Surgery of Trauma prospective study. *J Trauma* 2009;66:967-73.
11. Pate JW, Gavant ML, Weiman DS, Fabian TC. Traumatic rupture of the aortic isthmus: program of selective management. *World J Surg* 1999;23:59-63.
12. Azizzadeh A, Keyhani K, Miller CC III, Coogan SM, Safi HJ, Estrera AL. Blunt traumatic aortic injury: initial experience with endovascular repair. *J Vasc Surg* 2009;49:1403-8.
13. Xenos ES, Abedi NN, Davenport DL, Minion DJ, Hamdallah O, Sorial EE, et al. Meta-analysis of endovascular vs open repair for traumatic descending thoracic aortic rupture. *J Vasc Surg* 2008;48:1343-51.

14. Tang GL, Tehrani HY, Usman A, Katariya K, Otero C, Perez E, et al. Reduced mortality, paraplegia, and stroke with stent graft repair of blunt aortic transections: a modern meta-analysis. *J Vasc Surg* 2008;47:671-5.
15. Neschis DG, Scalea TM, Flinn WR, Griffith BP. Blunt aortic injury. *N Engl J Med* 2008;359:1708-16.
16. Raupach J, Ferko A, Lojik M, Krajina A, Harrer J, Dominik J. Endovascular treatment of acute and chronic thoracic aortic injury. *Cardiovasc Intervent Radiol* 2007;30:1117-23.
17. Wellons ED, Milner R, Solis M, Levitt A, Rosenthal D. Stent-graft repair of traumatic thoracic aortic disruptions. *J Vasc Surg* 2004;40:1095-100.
18. McPhee JT, Asham EH, Rohrer MJ, Singh MJ, Wong G, Vorhies RW, et al. The midterm results of stent graft treatment of thoracic aortic injuries. *J Surg Res* 2007;138:181-8.
19. Matsumura JS, Lee WA, Mitchell RS, Farber MA, Murad MH, Lumsden AB, et al; Society for Vascular Surgery. The Society for Vascular Surgery Practice Guidelines: management of the left subclavian artery with thoracic endovascular aortic repair. *J Vasc Surg* 2009;50:1155-8.
20. Feezor RJ, Martin TD, Hess PJ, Klodell CT, Beaver TM, Huber TS, et al. Risk factors for perioperative stroke during thoracic endovascular aortic repairs (TEVAR). *J Endovasc Ther* 2007;14:568-73.
21. Peterson BG, Matsumura JS, Morasch MD, West MA, Eskandari MK. Percutaneous endovascular repair of blunt thoracic aortic transection. *J Trauma* 2005;59:1062-5.
22. Lee WA, Brown MP, Nelson PR, Huber TS, Seeger JM. Midterm outcomes of femoral arteries after percutaneous endovascular aortic repair using the Preclose technique. *J Vasc Surg* 2008;47:919-23.

Submitted Aug 2, 2010; accepted Aug 10, 2010.