



Since January 2020 Elsevier has created a COVID-19 resource centre with free information in English and Mandarin on the novel coronavirus COVID-19. The COVID-19 resource centre is hosted on Elsevier Connect, the company's public news and information website.

Elsevier hereby grants permission to make all its COVID-19-related research that is available on the COVID-19 resource centre - including this research content - immediately available in PubMed Central and other publicly funded repositories, such as the WHO COVID database with rights for unrestricted research re-use and analyses in any form or by any means with acknowledgement of the original source. These permissions are granted for free by Elsevier for as long as the COVID-19 resource centre remains active.

# COVID-19 Encephalitis with SARS-CoV-2 Detected in Cerebrospinal Fluid Presenting as a Stroke Mimic

Diarmuid Glavin, MBBS,<sup>a,1</sup> Denise Kelly, MBChB,<sup>a,1</sup>  
Greta Karen Wood, MBBS, MRes,<sup>b</sup> Beth MS McCausland, MBBS,<sup>c,d</sup>  
Mark Alexander Ellul, MB BChir,<sup>b,e,f</sup> Aravinthan Varatharaj, BMBCh, MA (Oxon),<sup>c,d</sup>  
Ian Galea, MD, PhD,<sup>c,d</sup> Rhys Huw Thomas, MBChB, PhD,<sup>g,h</sup>  
Benedict Daniel Michael, MBChB, PhD,<sup>b,e,f,2</sup> and  
Brian Gallen, MB BCh<sup>a,2</sup>, CoroNerve Study Management Group<sup>3</sup>

We report the case of a 35-year-old male with COVID-19 encephalitis presenting as a stroke mimic with sudden-onset expressive and receptive dysphasia, mild confusion and right arm incoordination. The patient received thrombolysis for a suspected ischaemic stroke, but later became febrile and SARS-CoV-2 was detected in cerebrospinal fluid. Electroencephalography demonstrated excess in slow waves, but neuroimaging was reported as normal. Respiratory symptoms were absent throughout and nasopharyngeal swab was negative for SARS-CoV-2. At the most recent follow-up, the patient had made a full neurological recovery. Clinicians should therefore consider testing for SARS-CoV-2 in CSF in patients who present with acute focal neurology, confusion and fever during the pandemic, even when there is no evidence of respiratory infection.

**Key Words:** Encephalitis—COVID-19—SARS-Cov-2—Stroke mimic

© 2021 Elsevier Inc. All rights reserved.

## Introduction

The neurological complications associated with COVID-19 remain under investigation, with cerebrovascular disease at the forefront of debate.<sup>1</sup> This case demonstrates the complexities faced characterising neurological pathology during the SARS-CoV-2 pandemic, with real-world clinical implications.

## Case

A 35-year-old male presented with sudden-onset expressive and receptive dysphasia, mild confusion and right arm incoordination (National Institutes of Health Stroke Scale: 5). The patient had a medical history of migraines only, no regular medication and was a current smoker. Initial CT brain (Fig. 1A) showed no significant

From the <sup>a</sup>Department of Stroke Medicine, South West Acute Hospital, Enniskillen, Northern Ireland, UK; <sup>b</sup>Department of Clinical Infection Microbiology and Immunology, Institute of Infection, Veterinary, and Ecological Science, Liverpool, UK; <sup>c</sup>Clinical Neurosciences, Clinical and Experimental Sciences, Faculty of Medicine, University of Southampton, UK; <sup>d</sup>University Hospital Southampton NHS Foundation Trust, Southampton, UK; <sup>e</sup>Department of Neurology, The Walton Centre NHS Foundation Trust, Liverpool, UK; <sup>f</sup>The NIHR Health Protection Research Unit for Emerging and Zoonotic Infection, Liverpool, UK; <sup>g</sup>Translational and Clinical Research Institute, Newcastle University, Newcastle, UK; and <sup>h</sup>Department of Neurology, Royal Victoria Infirmary, Newcastle, UK.

Received February 15, 2021; revision received May 20, 2021; accepted May 23, 2021.

Grant support: This work did not have grant support. Author funding sources are listed under Declaration of Interest.

Corresponding author at: South West Acute Hospital, 124 Irvinestown Rd, Enniskillen, BT74 6DN, UK. E-mail: [brian.gallen@westerntrust.hscni.net](mailto:brian.gallen@westerntrust.hscni.net).

<sup>1</sup>Joint First Author

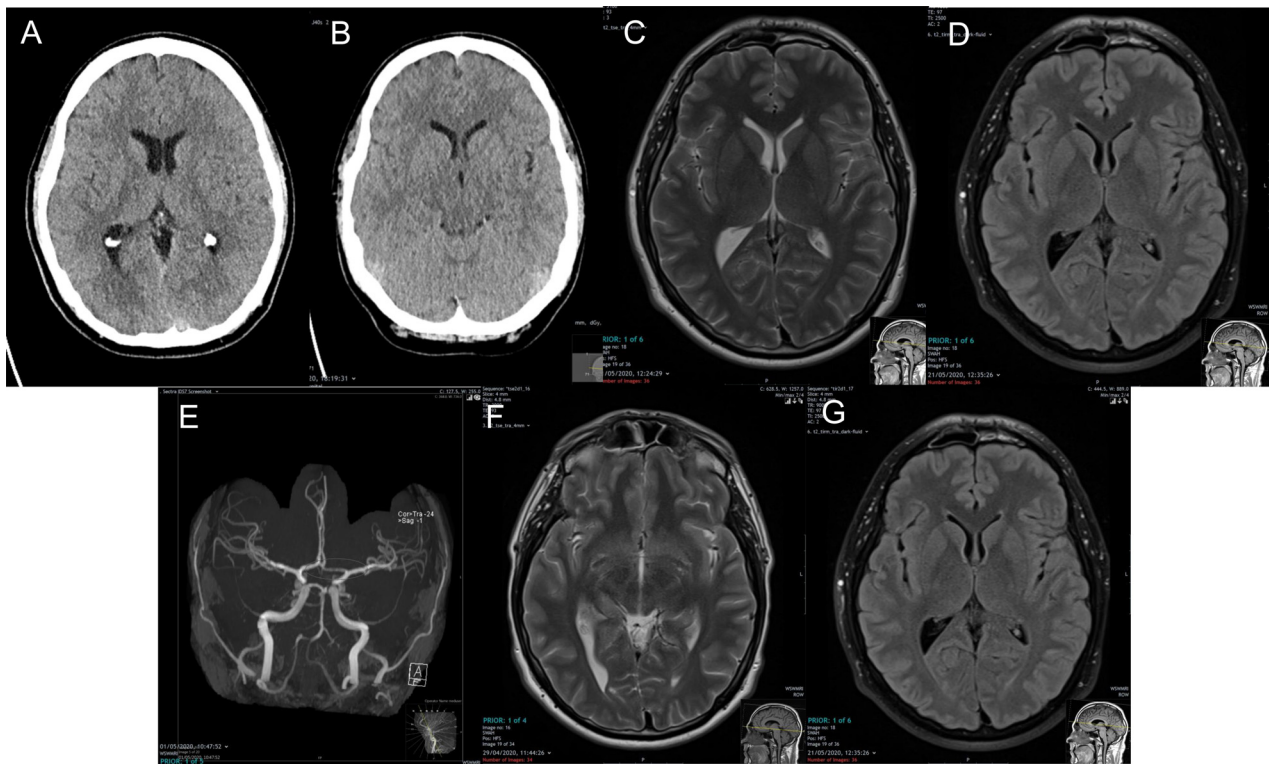
<sup>2</sup>Joint Senior Author

<sup>3</sup>Named in acknowledgements

1052-3057/\$ - see front matter

© 2021 Elsevier Inc. All rights reserved.

<https://doi.org/10.1016/j.jstrokecerebrovasdis.2021.105915>



**Fig. 1.** A) Day 1 CT Brain – Normal; B) Day 2 CT Brain– Normal, standard 24-hour post thrombolysis imaging; Day 3 MRI Head T2 (C) and FLAIR (D) – Normal; E) Day 5 MRA Head - normal with congenitally hypoplastic left A1 segment anterior cerebral artery- marked on image (incidental finding) (TOF image); F) Day 25 MRI Head T2 (F) and FLAIR (G) –Normal.

intracranial abnormalities and the patient received thrombolysis for a suspected ischaemic stroke. Symptoms resolved over 2 hours and post-thrombolysis CT (day 2, Fig. 1B) was reported as normal. Respiratory symptoms were absent, and admission nasopharyngeal swab was negative for SARS-CoV-2.

On day 3, the patient had right arm weakness and later developed expressive and receptive dysphasia, amnesia, headache and vomiting, followed by pyrexia 39.7°C. GCS remained 15/15 without evidence of meningism. MRI brain (day 3, Fig. 1C,D) was normal.

Lumbar puncture (day 4) had an opening pressure 24cm/H<sub>2</sub>O with clear CSF, white cell count  $134 \times 10^6/L$  (99% lymphocytes), red cell count  $20 \times 10^6/L$ , protein 0.52g/L and CSF:serum glucose ratio 3.7:5.1mmol/L (0.73). CSF culture was negative and polymerase chain reaction (PCR) negative for *Neisseria meningitides*, *Streptococcus pneumoniae* and several viruses including HSV, varicella zoster virus, enterovirus and parechovirus. However, PCR of the CSF was positive for SARS-CoV-2 RNA, with identification of both the E gene (CT value 35.8) and S gene (CT value 35.7) (Altona RealStar SARS-CoV-2 RT-PCR Kit, Roche Flow system). MR angiogram brain (day 5, Fig. 1E) showed incidental congenitally hypoplastic left A1 segment of anterior cerebral artery. Pyrexia and amnesia persisted, but by day 8, the patient was deemed to have made a full recovery and discharged.

Follow-up MRI brain (day 25, Fig. 1F,G) was normal, and electroencephalography (day 34) demonstrated generalized slowing suggestive of encephalopathy, which was not otherwise explained. At outpatient follow-up (day 55), there were no ongoing neurological symptoms. Serum antibody testing did not detect anti-SARS-CoV-2 antibodies.

## Discussion

The differentiation of strokes and stroke mimics is a particular challenge in COVID-19 patients. Limited stroke risk factors, new seizures, acute or subacute encephalopathy and reduced GCS could suggest a stroke mimic.<sup>1</sup>

Whilst several reports have speculated upon the diagnosis of encephalitis in COVID-19 patients,<sup>2-4</sup> detection of SARS-CoV-2 in CSF remains rare.<sup>5-7</sup> Two main plausible routes of entry for SARS-CoV-2 to the central nervous system (CNS) are via the angiotensin-converting enzyme 2 receptors located on epithelial cells of the blood-cerebrospinal fluid barrier and via retrograde axonal transport of peripheral neural pathways such as via the olfactory mucosa in the nasal cavity.<sup>8</sup>

Evidence of CSF pleocytosis with white cell count  $>100 \times 10^6/L$  is suggestive of CNS infection and is clear evidence of CSF inflammation.<sup>9</sup> Numerous other CNS and systemic infections were excluded on culture and

PCR. Non-infectious causes were excluded with brain imaging (CT, MRI and MRA brain). There are several potential reasons for negative nasopharyngeal PCR tests including reduced viral load, transient viral dissemination or collection and storage errors. Research has shown a median false negative rate of COVID-19 nasopharyngeal RT-PCR of 38% on the day of symptom onset and maximum COVID-19 replication in the throat seen 5 days after symptom onset.<sup>10-11</sup>

Clinicians should therefore consider testing for SARS-CoV-2 in CSF in patients who present with acute focal neurology, confusion and fever during the pandemic, even when there is no evidence of respiratory infection.

### Declaration

The patient gave consent for publication of his case in the medical literature.

### Funding

IG and AV are supported by NIHR and MRC. BDM is supported to conduct COVID-19 neuroscience research by the UKRI/MRC (MR/V03605X/1); for additional neurological inflammation research due to viral infection BDM is also supported by grants from the MRC/UKRI (MR/V007181//1), MRC (MR/T028750/1) and Wellcome (ISSF201902/3). The funding sources had no role in the writing of this report or decision to submit the article for publication.

### Declaration of Competing Interest

None

### Acknowledgements

We would like to acknowledge the Regional Virus Laboratory, Royal Victoria Hospital, Belfast for the diagnostics performed.

CoroNerve Study Group: Rachel Kneen, Sarah Pett, Naomi Thomas, Laura Benjamin, Tom Solomon, Nicholas Davies, Hadi Manji, Ava Easton, Michael Zandi, Jonathan Coles, Craig Smith, David Menon, Tim Nicholson, Beth Tenorio, Victoria Grimby, Mustafa Sultan, Beth McCausland, Amy Ross Russell, Sarah Crisp, Peter Swann.

### References

1. Ellul M, Benjamin L, Singh B, et al. Neurological Associations of COVID-19. *Lancet Neurol* 2020;19(9):767-783.
2. Duong L, Xu P, Lu A. Meningoencephalitis without Respiratory Failure in a Young Female Patient with COVID-19 Infection in Downtown Los Angeles, April 2020. *Brain, Behav Immun* 2020;87:33.
3. Ye M, Ren Y, Lv T. Encephalitis as a Clinical Manifestation of COVID-19. *Brain, Behav Immun* 2020. doi.org/10.1016/j.bbi.2020.04.017.
4. Al Saiegh F, Ghosh R, Leibold A, et al. Status of SARS-CoV-2 in cerebrospinal fluid of patients with COVID-19 and stroke. *J Neurol Neurosurg Psychiatry* 2020;91:846-848.
5. Moriguchi T, Harii N, Goto J, et al. A first case of meningitis/encephalitis associated with SARS-Coronavirus-2. *Int J Infect Dis* 2020;94:55-58.
6. Wu Y, Xu X, Chen Z, et al. Nervous system involvement after infection with COVID-19 and other coronaviruses. *Brain, Behav Immun* 2020;87:18-22.
7. Huang YH, Jiang D, Huang JT. SARS-CoV-2 Detected in Cerebrospinal Fluid by PCR in a Case of COVID-19 Encephalitis. *Brain, Behav Immun* 2020;87:149.
8. Koyuncu OO, Hogue IB, Enquist LW. Virus infections in the nervous system. *Cell Host Microbe* 2013;13:379-393.
9. Østergaard Anne Ahrens, et al. Cerebrospinal fluid pleocytosis level as a diagnostic predictor? A cross-sectional study. *BMC Clin Pathol* 24 Aug. 2017;17:15. <https://doi.org/10.1186/s12907-017-0053-0>.
10. Tahamtan Alireza, Ardebili Abdollah. Real-time RT-PCR in COVID-19 detection: issues affecting the results. *Expert Rev Mol Diagn* 2020;20(5):453-454. <https://doi.org/10.1080/14737159.2020.1757437>.
11. Bahreini Fatemeh, et al. Reducing False Negative PCR Test for COVID-19. *Int J MCH AIDS* 2020;9(3):408-410. <https://doi.org/10.21106/ijma.421>.