



Aalborg Universitet

AALBORG UNIVERSITY  
DENMARK

## Maxillary Sinus Floor Augmentation with Autogenous Bone Graft Compared with a Composite Grafting Material or Bone Substitute Alone

*a Systematic Review and Meta-Analysis Assessing Volumetric Stability of the Grafting Material*

Starch-Jensen, Thomas; Deluiz, Daniel; Vitenson, Julie; Bruun, Niels Henrik; Tinoco, Eduardo Muniz Barretto

*Published in:*  
eJournal of Oral And Maxillofacial Research

*DOI (link to publication from Publisher):*  
[10.5037/jomr.2021.12101](https://doi.org/10.5037/jomr.2021.12101)

*Creative Commons License*  
CC BY-NC-ND 3.0

*Publication date:*  
2021

*Document Version*  
Publisher's PDF, also known as Version of record

[Link to publication from Aalborg University](#)

*Citation for published version (APA):*

Starch-Jensen, T., Deluiz, D., Vitenson, J., Bruun, N. H., & Tinoco, E. M. B. (2021). Maxillary Sinus Floor Augmentation with Autogenous Bone Graft Compared with a Composite Grafting Material or Bone Substitute Alone: a Systematic Review and Meta-Analysis Assessing Volumetric Stability of the Grafting Material. *eJournal of Oral And Maxillofacial Research*, 12(1), [e1]. <https://doi.org/10.5037/jomr.2021.12101>

### General rights

Copyright and moral rights for the publications made accessible in the public portal are retained by the authors and/or other copyright owners and it is a condition of accessing publications that users recognise and abide by the legal requirements associated with these rights.

- ? Users may download and print one copy of any publication from the public portal for the purpose of private study or research.
- ? You may not further distribute the material or use it for any profit-making activity or commercial gain
- ? You may freely distribute the URL identifying the publication in the public portal ?

# Maxillary Sinus Floor Augmentation with Autogenous Bone Graft Compared with a Composite Grafting Material or Bone Substitute Alone: a Systematic Review and Meta-Analysis Assessing Volumetric Stability of the Grafting Material

Thomas Starch-Jensen<sup>1</sup>, Daniel Deluiz<sup>2</sup>, Julie Vitenson<sup>1</sup>, Niels Henrik Bruun<sup>3</sup>, Eduardo Muniz Barretto Tinoco<sup>2</sup>

<sup>1</sup>Department of Oral and Maxillofacial Surgery, Aalborg University Hospital, Aalborg, Denmark.

<sup>2</sup>Department of Periodontology, Rio de Janeiro State University, Rio de Janeiro, Brazil.

<sup>3</sup>Unit of Clinical Biostatistics, Aalborg University Hospital, Aalborg, Denmark.

## Corresponding Author:

Thomas Starch-Jensen  
Department of Oral and Maxillofacial Surgery  
Aalborg University Hospital  
18-22 Hobrovej, DK-9000 Aalborg  
Denmark  
Phone: +45 97 66 27 98  
Fax: +45 97 66 28 25  
E-mail: [thomas.jensen@rn.dk](mailto:thomas.jensen@rn.dk)

## ABSTRACT

**Objectives:** Test the hypothesis of no difference in the volumetric stability of the grafting material following maxillary sinus floor augmentation with autogenous bone graft compared with composite grafting material or bone substitute alone applying the lateral window technique.

**Material and Methods:** MEDLINE (PubMed), Embase, Cochrane library and hand-search of relevant journals were conducted. Human studies published in English until the 9<sup>th</sup> of October 2020 were included. Outcome measures included three-dimensional volumetric changes of the grafting material and potential predictive parameters. Volumetric changes were evaluated by descriptive statistics and meta-analysis including 95% confidence interval.

**Results:** Electronic search and hand-searching resulted in 102 entries. Four randomized controlled trials with unclear risk of bias fulfilled the inclusion criteria. The volumetric stability of the grafting material was significantly improved by mixing autogenous bone graft with a non-resorbable xenograft compared with autogenous bone graft. Meta-analyses assessing absolute and relative volumetric changes demonstrated no significant differences between autogenous bone graft compared with allogeneic bone graft, synthetic biomaterials combined with autogenous bone graft or used alone. Association between volumetric changes of the grafting material and potential predictive parameters were not assessed in the included studies.

**Conclusions:** Volumetric reduction of the augmented area seems inevitable following maxillary sinus floor augmentation regardless of the grafting material. The volumetric stability of autogenous bone graft is improved with addition of xenograft compared with autogenous bone graft. However, conclusions drawn from this systematic review should be interpreted with caution since only four studies using three-dimensional radiographic measurements were included.

**Keywords:** alveolar ridge augmentation; dental implants; oral surgical procedures; review; sinus floor augmentation.

Accepted for publication: 23 March 2021

### To cite this article:

Starch-Jensen T, Deluiz D, Vitenson J, Bruun NH, Tinoco EMB.

Maxillary Sinus Floor Augmentation with Autogenous Bone Graft Compared with a Composite Grafting Material or Bone Substitute Alone: a Systematic Review and Meta-Analysis Assessing Volumetric Stability of the Grafting Material

J Oral Maxillofac Res 2021;12(1):e1

URL: <http://www.ejomr.org/JOMR/archives/2021/1/e1/v12n1e1.pdf>

doi: [10.5037/jomr.2021.12101](https://doi.org/10.5037/jomr.2021.12101)

## INTRODUCTION

Maxillary sinus floor augmentation (MSFA) applying the lateral window technique is a safe and predictable surgical procedure to increase the alveolar bone height of the posterior maxilla before or in conjunction with placement of dental implants, as reported in previous systematic reviews and meta-analyses [1-10]. Autogenous bone graft is generally considered as the preferred grafting material for MSFA due to its osteoinductive, osteogenic and osteoconductive characteristics [11]. However, the use of autogenous bone graft is associated with risk of donor site morbidity and unpredictable resorption of the augmented area, as documented in clinical and experimental studies [12-16]. Autogenous bone graft is therefore frequently combined or completely replaced with a bone substitute that possess low substitution rate to simplify the surgical procedure by diminishing the need for bone harvesting and maintaining the volume of the augmented area [1-10]. However, a recent systematic review concluded that certain volume loss of the augmented area always occurs during the early healing period following MSFA, regardless of the used grafting material [17].

Volumetric and dimensional stability of the augmented area represents an important factor for successful implant treatment outcome, although volume loss of the augmented area does not necessarily compromise delayed implant placement or long-term implant survival [17,18]. Two-dimensional radiographs are frequently used for radiographic assessment of vertical dimension changes of the augmented area following MSFA [19-21]. However, the augmented area within the maxillary sinus is an inhomogeneous and three-dimensional anisotropic structure [15]. Volumetric changes of the grafting material should therefore be assessed by three-dimensional methods to achieve an accurate determination of the augmented area [15]. Computer tomography (CT) or cone-beam computer tomography (CBCT) combined with software technology is considered a reliable method for accurate delineation of the augmented area as well as quantifying three-dimensional volumetric changes of the grafting material within the maxillary sinus [16,22,23]. However, implementation of a standardized three-dimensional method for assessment of volumetric changes of the grafting material using novel computed technology is still not well established and radiographic demarcation of the original border between the augmented area and the maxillary sinus floor becomes indistinct as

the graft becomes integrated, which compromises accurate estimation of the volumetric changes of the grafting material [15,24]. Furthermore, assessment of predictive factors that could potentially influence the degree of volumetric reduction of the grafting material following MSFA have solely been discussed in few studies [25,26]. The objective of the present systematic review is therefore to test the hypothesis of no difference in volumetric stability of the grafting material following maxillary sinus floor augmentation applying the lateral window technique with autogenous bone graft compared with a composite grafting material or bone substitute alone using three-dimensional radiographic measurements.

## MATERIAL AND METHODS

### Protocol and registration

Review was conducted in accordance with the Preferred Reporting Items for Systematic Reviews and Meta-Analyses (PRISMA) statement for reporting systematic reviews [27]. Methods of the analysis and inclusion criteria were specified in advance and documented in a protocol and registered in PROSPERO, an international prospective register of systematic reviews.

Registration number: CRD42020213960.

The protocol can be accessed at:

[https://www.crd.york.ac.uk/prospero/display\\_record.php?ID=CRD42020213960](https://www.crd.york.ac.uk/prospero/display_record.php?ID=CRD42020213960).

### Focus question

The focus question was developed according to the Patient, Intervention, Comparison and Outcome (PICO) framework as described in Table 1.

Focus question: Are there any differences in the volumetric stability of the grafting material following MSFA with the use of autogenous bone graft compared with a composite grafting material or bone substitute alone?

### Types of studies and publications

Randomized controlled trials in humans.

### Population

Partially or totally edentulous healthy adult patients with atrophy of the posterior part of the maxilla receiving MSFA applying the lateral window technique with autogenous bone graft compared with a composite grafting material or bone substitute alone.

**Table 1.** PICOS guidelines

<b>Patient and population (P)</b>	Healthy adult patients with atrophy of the posterior maxilla receiving maxillary sinus floor augmentation applying the lateral window technique.
<b>Intervention (I)</b>	Autogenous bone graft.
<b>Comparator or control group (C)</b>	Composite grafting material or bone substitute alone.
<b>Outcomes (O)</b>	Volumetric changes of the grafting material as evaluated by computer tomography or cone beam computer tomography. Correlation between volumetric changes of the grafting material and potential predictive parameters including gender, age, preoperative alveolar bone height, sinus cavity dimensions, size of the lateral window, amount of grafting material, simultaneous or delayed implant placement, tension of the sinus membrane, endosinus air flow pressure, barrier membrane coverage of the lateral window, and graft healing time interval.
<b>Study design (S)</b>	Randomized controlled trials.
<b>Focused question</b>	Are there any differences in the volumetric stability of the grafting material following maxillary sinus floor augmentation with the use of autogenous bone graft compared with a composite grafting material or bone substitute alone?

### Types of outcome measures

There are two types of outcome measures:

- Volumetric changes of the grafting material as evaluated by CT or CBCT.
- Correlation between volumetric changes of the grafting material and potential predictive parameters including gender, age, preoperative alveolar bone height, sinus cavity dimensions, size of the lateral window, amount of grafting material, simultaneous or delayed implant placement, tension of the sinus membrane, endosinus air flow pressure, barrier membrane coverage of the lateral window, and graft healing time interval.

### Information sources

The search strategy incorporated examinations of electronic databases, supplemented by a thorough hand-search page by page of relevant journals including “British Journal of Oral and Maxillofacial Surgery”, “Clinical Implant Dentistry and Related Research”, “Clinical Oral Implants Research”, “European Journal of Oral Implantology”, “Implant Dentistry”, “International Journal of Oral and Maxillofacial Implants”, “International Journal of Oral and Maxillofacial Surgery”, “International Journal of Periodontics and Restorative Dentistry”, “International Journal of Prosthodontics”, “Journal of Clinical Periodontology”, “Journal of Dental Research”, “Journal of Oral Implantology”, “Journal of Oral & Maxillofacial Research”, “Journal of Periodontology”, “Journal of Prosthetic Dentistry”, “Journal of Craniofacial Surgery”, “Journal of Cranio-Maxillo-Facial Surgery”, “Journal of Oral and Maxillofacial Surgery”, “Periodontology 2000”, “Oral and Maxillofacial Surgery” and

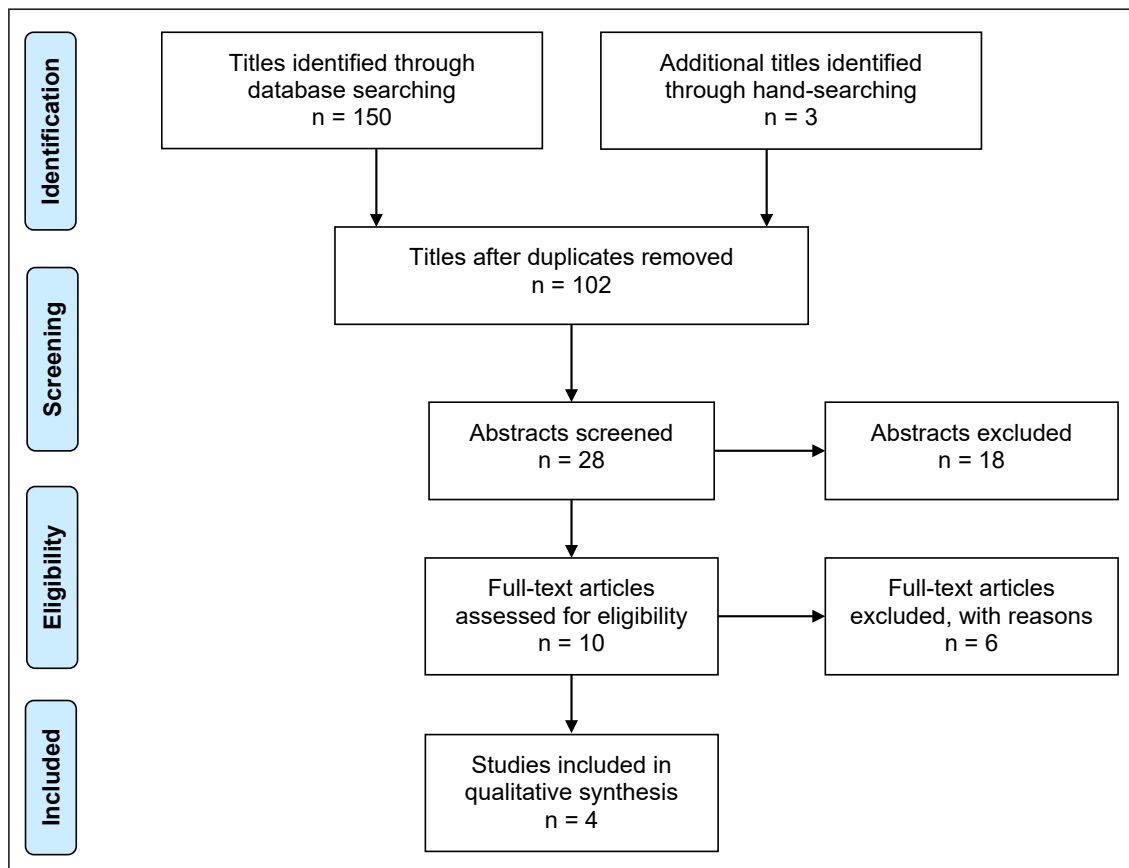
“Oral Surgery Oral Medicine Oral Pathology Oral Radiology”. The manual search also included the bibliographies of all articles selected for full-text screening as well as previously published reviews relevant for the present systematic review. Two reviewers (T.S-J. and J.V.) independently performed the search. In the event of disagreement between the reviewers, another reviewer was consulted (E.M.B.T.).

### Search

A MEDLINE (PubMed), Embase, and Cochrane Library search was conducted. Human studies published in English until the 9<sup>th</sup> of October 2020 were included. Grey literature, unpublished literature as well as other databases like Scopus, Google Scholar, or Research Gate were not included in the search strategy of the present systematic review. The search strategy was performed in collaboration with a librarian and utilized a combination of Medical subject heading (MeSH) and free text terms. A detailed description of the search strategy is outlined in [Appendices 1 to 3](#).

### Selection of studies

PRISMA flow diagram presents an overview of the selection process (Figure 1). Titles of identified reports were initially screened with duplicates removed. Abstracts were assessed when the title indicated that the study was relevant. Full-text analysis was obtained for those with apparent relevance or when the abstract was unavailable. References of papers identified and previously published systematic reviews were cross-checked for unidentified articles. Study selection was performed by two reviewers (T.S-J. and J.V.).



**Figure 1.** PRISMA (Preferred Reporting Items for Systematic Reviews and Meta-Analyses) flow diagram demonstrating the results of the systematic literature search.

In the event of disagreement between the reviewers, another reviewer was consulted (E.M.B.T.). The level of agreement between the authors was tested using Cohen's kappa coefficient ( $k$ ).

### Inclusion criteria

Studies assessing MSFA with particulated autogenous bone graft compared with a composite grafting material or bone substitute alone were included by addressing the previously described outcome measure. The review exclusively focused on randomized controlled trials presenting volumetric changes of the grafting material as evaluated by CT or CBCT. In addition, at least five patients involving five sinus augmentation procedures in each group should be included and the grafting material as well as number of MSFA procedures had to be clearly specified.

### Exclusion criteria

Following exclusion criteria were applied: MSFA with autogenous bone block graft, additional grafting procedures in conjunction with MSFA, unspecified length of observation period as well as studies

involving medically compromised patients or two-dimensional radiographic assessment. Moreover, letters, editorials, PhD theses, letters to the editor, case reports, abstracts, technical reports, conference proceedings, animal or *in vitro* studies and literature review papers were also excluded.

### Data extraction

Data were extracted by one reviewer (T.S-J.) according to a data-collection form ensuring systematic recording of the outcome measures. In addition, relevant characteristics of the study were recorded. Corresponding authors were contacted by e-mail in the absence of important information or ambiguities.

### Data items

Following items were collected and arranged in the following fields: author, year of publication, number of patients, number of MSFA procedures, type of grafting material, residual alveolar bone height, type of computer tomography, assessment method, length of observation period, volumetric changes and volumetric reduction.

## Assessment of methodological quality and risk-of-bias assessment

Quality assessment was undertaken by one review author (T.S-J.) as part of the data extraction process. Cochrane Collaboration's tool for assessing the risk of bias suggested in the Cochrane Handbook for Systematic Reviews of Interventions was used for included randomized controlled trials (version 5.1.0) [28]. Following items were evaluated:

- Random sequence generation;
- Allocation concealment;
- Patient blinding;
- Outcome blinding;
- Incomplete outcome data addressed;
- Selective reporting.

Publications were grouped into the following categories [29]:

- Low risk of bias (possible bias not seriously affecting results) if all criteria were met.
- High risk of bias (possible bias seriously weakening reliability of results) if one or more criteria were not met.
- Unclear risk of bias when too few details were available for classification as high or low risk.

## Statistical analysis

Data management and statistical analysis was performed with Microsoft Office Excel version 2013 (Microsoft Corporation; Washington, USA) and statistical software STATA release 16 (StataCorp LLC; Missouri, USA). In longitudinal split-mouth trials, correlation between split-mouths within the patient and the correlation within the split-mouth over time needs to be modelled in the analysis [30]. Hence, meta-analysis is based on reported full datasets. Differences in absolute ( $\text{mm}^3$ ) and relative (%) volumetric changes of the grafting material between autogenous bone graft and a composite grafting material or bone substitute alone were estimated using a mixed random intercept model including individual with separate treatment standard deviations and restricted maximum likelihood. Results will be outlined in forest plots and funnel plots. Parametric data are expressed as mean and standard deviation (M [SD]). Statistical significance level was defined at  $P = 0.05$ .

## Assessment of heterogeneity

The significance of any discrepancies in the estimates of the treatment effects of the different studies was assessed by means of Cochran's test for heterogeneity

and the  $I^2$  statistic, which describes the percentage of total variation across studies that is due to heterogeneity rather than chance. Heterogeneity by Cochran's test was considered statistically significant if  $P < 0.1$ . A rough guide to the interpretation of  $I^2$  given in the Cochrane Handbook for Systematic Reviews of Interventions is as follows [28]:

- 0 - 40% the heterogeneity might not be important;
- 30 - 60% may represent moderate heterogeneity;
- 50 - 90% may represent substantial heterogeneity;
- 75 - 100% may represent considerable heterogeneity.

## RESULTS

### Study selection

Article review and data extraction were performed according to the PRISMA flow diagram (Figure 1). The systematic electronic literature search resulted in 150 entries. In addition, three articles were identified through hand-searching [31-33]. Of these 153 articles, 51 were excluded because they had been retrieved in more than one search. A total of 28 abstracts were reviewed and full-text analysis included 10 articles. Finally, four studies were included in the present systematic review [34-37]. The level of agreement between the two authors (T.S-J. and J.V.) in selecting studies to be read in full was measured at  $k = 0.835$ , while level of agreement between the two authors (T.S-J. and J.V.) for eligibility assessment was measured at  $k = 1$ .

### Exclusion of studies

Reasons for excluding studies after full-text assessment were as follows: volumetric changes of the grafting material have been presented in previous publications [31,38], two-dimensional radiographic assessment methods were used [32], autogenous bone graft was not used as grafting material [33], less than five patients included [39], case series [40], and MSFA in conjunction with additional augmentation procedures [41].

### Study characteristics

The included studies of the present systematic review consisted of four randomized controlled trials with unclear risk of bias [34-37]. Partially and totally edentulous patients with vertical atrophy of the posterior part of the maxilla were enrolled in the included studies. Power calculation was performed in one study [37].

A split-mouth study design was used in two studies [34,36]. Residual bone height as well as inclusion and exclusion criteria were clearly specified in all the included studies [34-37]. Randomization was conducted using a randomization table [36], drawing lots [35,37], or no information was provided about the used randomization method [34]. The surgical procedure was performed by the same surgeon [35] or no information was provided about the accurate number of surgeons involved [34,36,37]. Autogenous bone graft was harvested from the ascending mandibular ramus [34-37] or the mandibular symphysis [37]. Autogenous bone graft was compared with synthetic biomaterial alone involving chronOS® (DePuy Synthes Inc.; Paoli, Pennsylvania, USA) or 1 : 1 mixture of chronOS® and autogenous bone graft [35] as well as BioGran® (3i Implant Innovations, Inc.; Palm Beach Gardens, Palm Beach, USA) or 1 : 1 mixture of Biogran® and autogenous bone [37]. Autogenous bone graft was compared with xenograft involving 80 : 20 GenOx® Inorgânico® (Baumer S.A; São Paulo, Brazil) and autogenous bone graft from the ascending mandibular ramus [34]. Autogenous bone graft was compared with fresh-frozen allogeneic bone from the femoral distal head (Musculoskeletal Tissue Bank of Marília Hospital [UNIOSS], Marília, São Paulo, Brazil) [36]. An unspecified resorbable collagen barrier membranes were used to cover the lateral window [36] or no information was provided about the use of a barrier membrane [34,35,37]. Delayed implant placement was conducted after 6 months [36] or at an unspecified time [35], while no information about immediate or delayed implant placement was provided in two studies [34,37]. The used implant system was not specified in any of the included studies [34-37]. Radiographic assessment of the volumetric changes was conducted using a standardized protocol involving CBCT (i-CAT® Cone Beam 3-D dental imaging system - Imaging Sciences International; Hatfield, Pensilvania, USA) [35-37] or CT-scan (Elscent CT-Twin - Phillips Medical Systems; Cleveland, Ohio, USA) [34]. Volumetric changes of the grafting material were estimated by computer software (Voxar 3D™ - Barco Inc.; Kortrijk, Belgium) [34], (OsiriX™ version 4.1.2 - Pixmeo; Geneva, Switzerland) [35,37], (Mimics® version 8.13 - Materialise HQ; Leuven, Belgium) [36]. The area sum technique involving volume calculation of sequential CT images within the delineated region-of-interest was used in one study [34]. The volume of the grafting material was calculated by multiplying the sum of the areas by the distance between the CT slices [35,37], while no information about the used technique was described [36]. Assessment of

the volumetric changes was conducted by blinded and calibrated observers [34,35,37], while no information about blinding, training or calibration of surgeons or the examiners assessing the clinical and radiographic outcome was provided in one study [36]. Numbers of drop-outs were reported in three studies [34,35,37].

## Outcome measures

Mean percentage of three-dimensional volumetric changes of the grafting material following MSFA are presented below including a short summary and the results are outlined in Table 2. None of the included studies assessed the correlation between volumetric changes of the grafting material and predictive parameters, why this outcome measure is not described.

## Volumetric changes of the grafting material

The volumetric reduction of the grafting material was 42.3% and 25.9% with autogenous bone graft or 8 : 2 ratio of GenOx® and autogenous bone graft after 180 days, respectively [34]. The difference was statistically significant ( $P < 0.05$ ) [34].

The volumetric reduction of the grafting material was 45.7 (18.6)%, 43.8 (18.4)%, and 38.3 (16.6)% with autogenous bone graft, 1 : 1 ratio of ChronOS® and autogenous bone graft or ChronOS® alone after six months, respectively [35]. There was no significant difference ( $P > 0.05$ ) [35].

The volumetric reduction of the grafting material was 23.9% and 31.4% with autogenous bone graft after six and twelve months, respectively [36]. Corresponding values for allogeneic fresh-frozen bone particles were 29.9% and 35.4%. There was no significant difference ( $P > 0.05$ ) [36].

The volumetric reduction of the grafting material was 45.7 (18.5)%, 37.9 (18.9)%, and 44 (16)% with autogenous bone graft, 1 : 1 ratio of Biogran® and autogenous bone graft or Biogran® alone after six months, respectively [37]. There was no significant difference ( $P > 0.05$ ) [37].

## Summary

Autogenous bone graft, allogeneic bone graft and synthetic biomaterials reveal considerable volumetric reduction of the grafting material during the early healing period, whereas a composite grafting material consisting of autogenous bone graft mixed with a xenograft demonstrated significantly improved preservation of the augmented area.

**Table 2.** Volumetric changes of grafting material following maxillary sinus floor augmentation

Author	Year of publication	Number of patients	MSFA	Materials and methods					Outcome measures							
				Type of grafting material	Residual bone height (mm)	Type of CT	Assessment method	Length of observation period (months)	Volumetric changes (cm <sup>3</sup> or mm <sup>3</sup> )			Volumetric reduction (%)				
Cosso et al. [34]	2014	10	10	8 : 2 GenOx <sup>®</sup> and autogenous bone	< 1 to 5 <	CT	Area sum technique using Voxar 3D <sup>TM</sup>	180 days	15 days (cm <sup>3</sup> )		180 days (cm <sup>3</sup> )		180 days			
				2.30 (SD 0.9)					1.7 (SD 0.6)		25.87					
				2.91 (SD 1)					1.7 (SD 0.9)		42.3 <sup>a</sup>					
Gorla et al. [35]	2015	22	11	ChronOS <sup>®</sup>	< 5	CBCT	Multiplying area sum by distance between CT slices using OsiriX <sup>TM</sup>	6	5 to 7 days (mm <sup>3</sup> )		6 to 8 months (mm <sup>3</sup> )		6 months			
				980.8 (SD 501.6)					563.2 (SD 335.9)		38.33 (SD 16.64)					
			9	1 : 1 ChronOS <sup>®</sup> and autogenous bone					1295.2 (SD 937.3)		848.7 (SD 801.1)		43.82 (SD 18.42)			
				Autogenous bone					1068.7 (SD 477.8)		528.3 (SD 221.3)		45.75 (SD 18.65)			
Xavier et al. [36]	2015	15	15	Fresh-frozen allograft	≤ 3	CBCT	Volume estimated using Mimics <sup>TM</sup> software	12	1 week (cm <sup>3</sup> )		6 months (cm <sup>3</sup> )		12 months (cm <sup>3</sup> )			
				2.46 (SD 0.79)					1.75 (SD 0.64)		1.59 (SD 0.56)		29.9		35.36	
			15	Autogenous bone					2.01 (SD 0.43)		1.53 (SD 0.49)		1.38 (SD 0.43)		23.9	
Pereira et al. [37]	2018	11	13	Biogran <sup>®</sup>	3 (SD 0.6)	CBCT	Multiplying area sum by distance between CT slices using OsiriX <sup>TM</sup>	6	15 days (mm <sup>3</sup> )		6 months (mm <sup>3</sup> )		6 months			
				909.7 (SD 472)					469.2 (SD 228.1)		44 (SD 16)					
		8	1 : 1 Biogran <sup>®</sup> and autogenous bone	1591.2 (SD 874)					1006.1 (SD 589.7)		37.9 (SD 18.9)					
			Autogenous bone	1071.2 (SD 477.8)					528.3 (SD 221.2)		45.7 (SD 18.5)					
10	12	Autogenous bone	1.2 (SD 0.4)													

<sup>a</sup>Student's t-test (P < 0.05).

CBCT = cone beam computed tomography; CT = computed tomography; MSFA = maxillary sinus floor augmentation; SD = standard deviation.



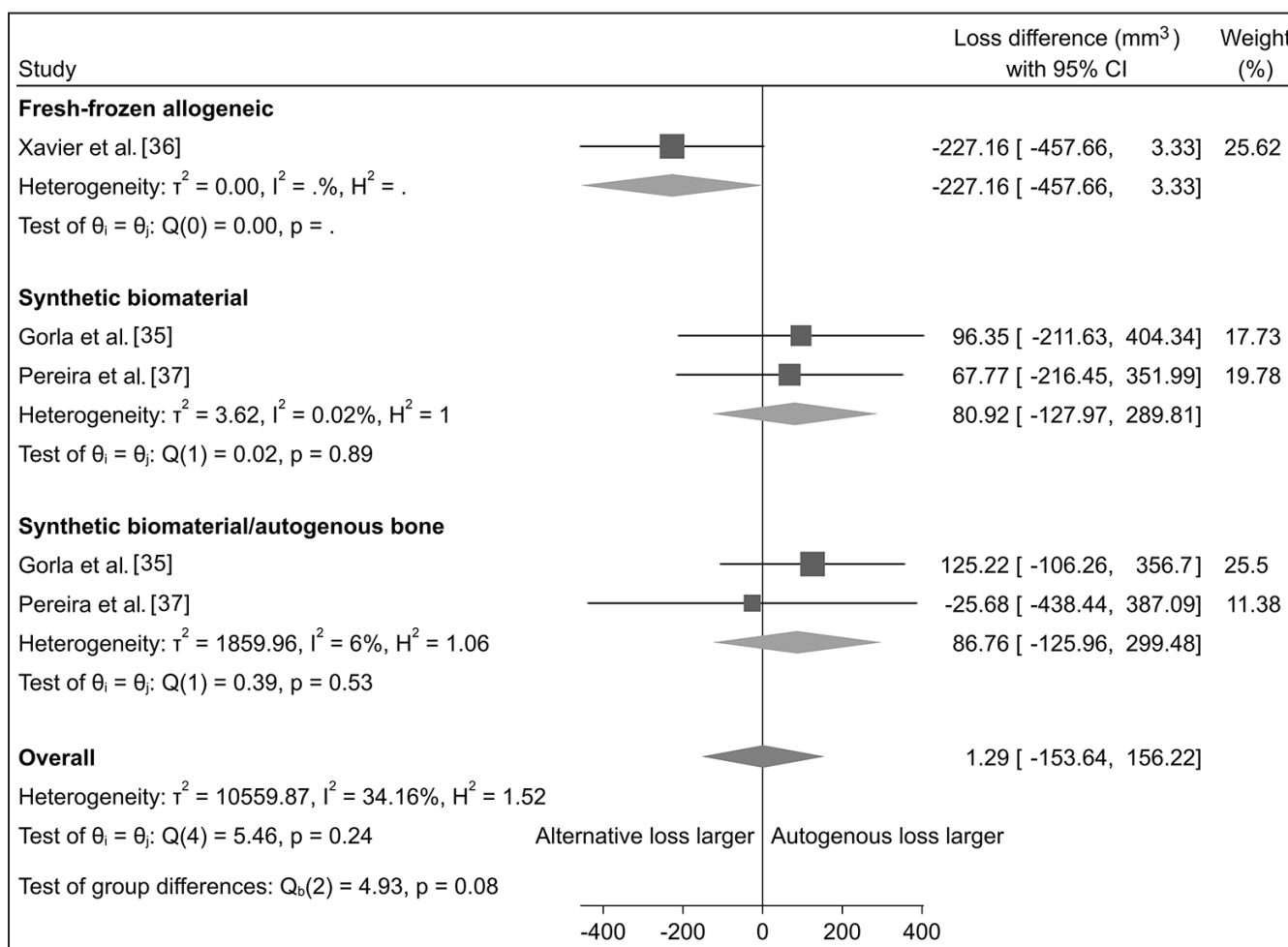
**Meta-analysis**

A split-mouth study design was used in two studies [34,36]. Thus, correlation between split-mouth within patients as well as over time needs to be integrated in the meta-analysis, when longitudinal split-mouth studies are included. Due to missing data, Cosso et al. [34] was excluded from the meta-analyses.

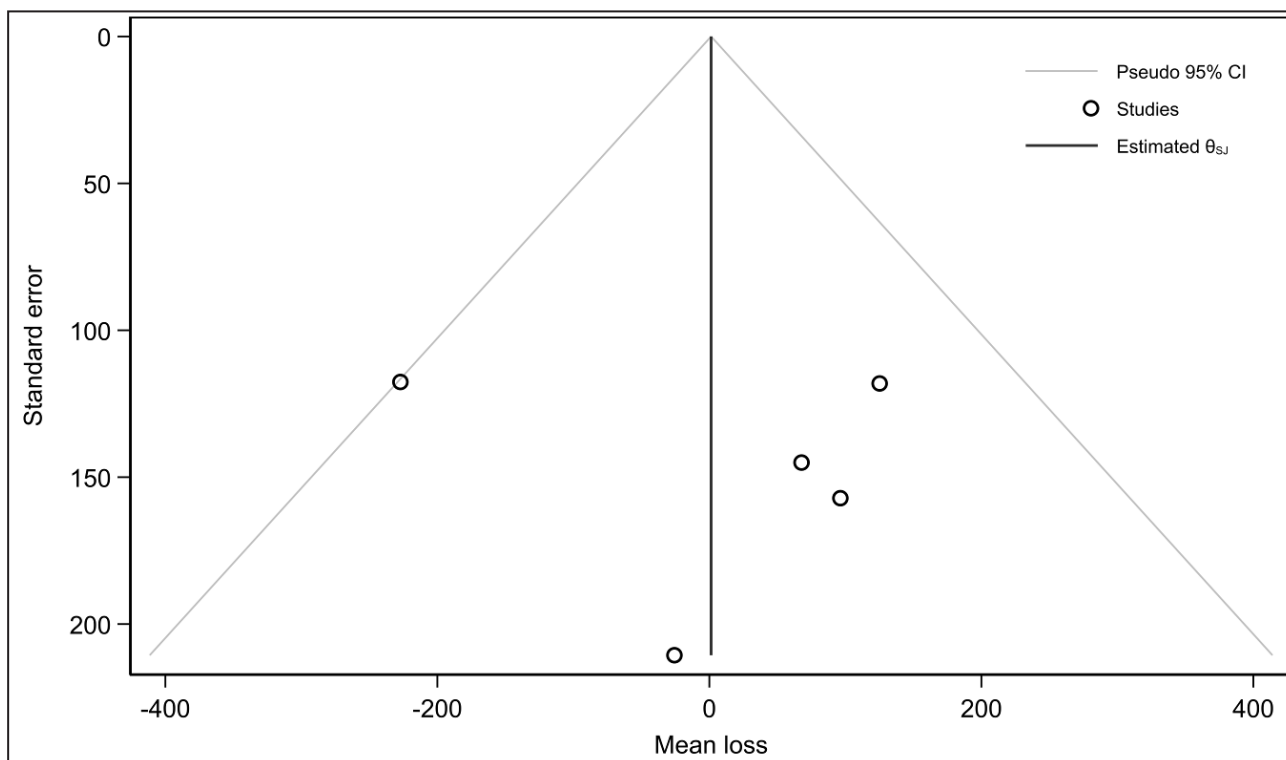
Differences in absolute (mm<sup>3</sup>) volumetric changes of the grafting material was estimated using a random-effects Sidik-Jonkman model. No statistically significant difference in heterogeneity among the included studies was found for synthetic biomaterials (I<sup>2</sup> = 0.02%, P = 0.89) or synthetic biomaterials mixed with autogenous bone graft (I<sup>2</sup> = 6%, P = 0.53), respectively [35,37]. Meta-analysis disclosed a 1.29 (mm<sup>3</sup>) (95% CI [confidence interval] = 153.64 to 156.22) larger volumetric reduction of the grafting material with autogenous bone graft compared with allogeneic bone, synthetic biomaterials or synthetic biomaterials mixed with autogenous bone graft indicating no statistically significant differences in the absolute volumetric reduction between

the used grafting materials (Figure 2). A funnel plot of the included studies is presented (Figure 3). Larger studies with higher power are placed towards the top (smaller standard errors), while lower powered studies are placed towards the bottom. Eggers test did not indicate small-study effects (P = 0.8982).

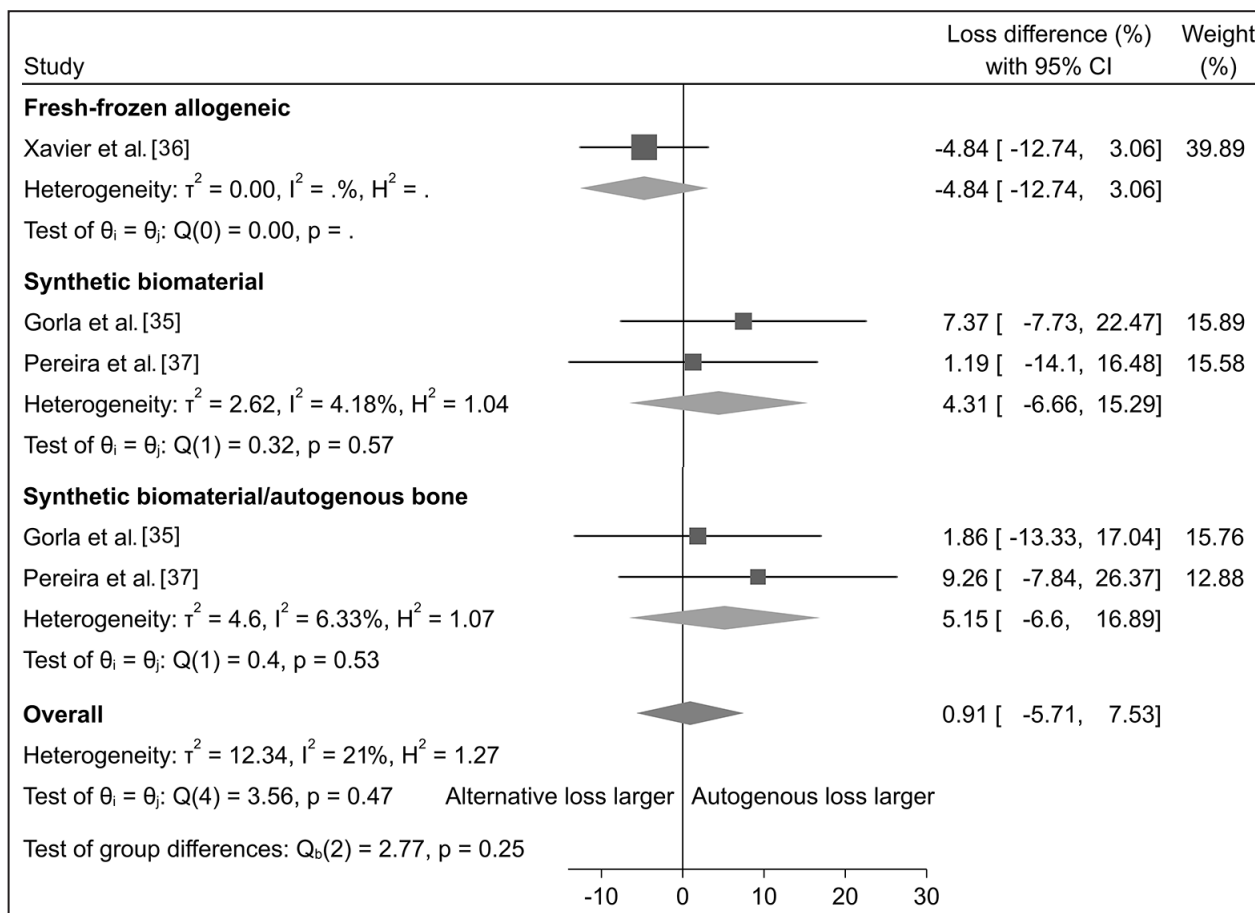
Differences in relative (%) volumetric changes of the grafting material was estimated using a random-effects Sidik-Jonkman model. No statistically significant difference in heterogeneity among the included studies was found for synthetic biomaterials (I<sup>2</sup> = 4.18%, P = 0.57) or synthetic biomaterials mixed with autogenous bone graft (I<sup>2</sup> = 6.3%, P = 0.53), respectively [35,37]. Meta-analysis disclosed a 0.9% (95% CI = -5.71 to 7.53) larger volumetric reduction of the grafting material with autogenous bone graft compared with allogeneic bone, synthetic biomaterials or synthetic biomaterials mixed with autogenous bone graft indicating no statistically significant differences in the relative volumetric reduction between the used grafting materials (Figure 4). A funnel plot of the included studies is presented (Figure 5). Eggers test did not indicate small-study effects (P = 0.0987).



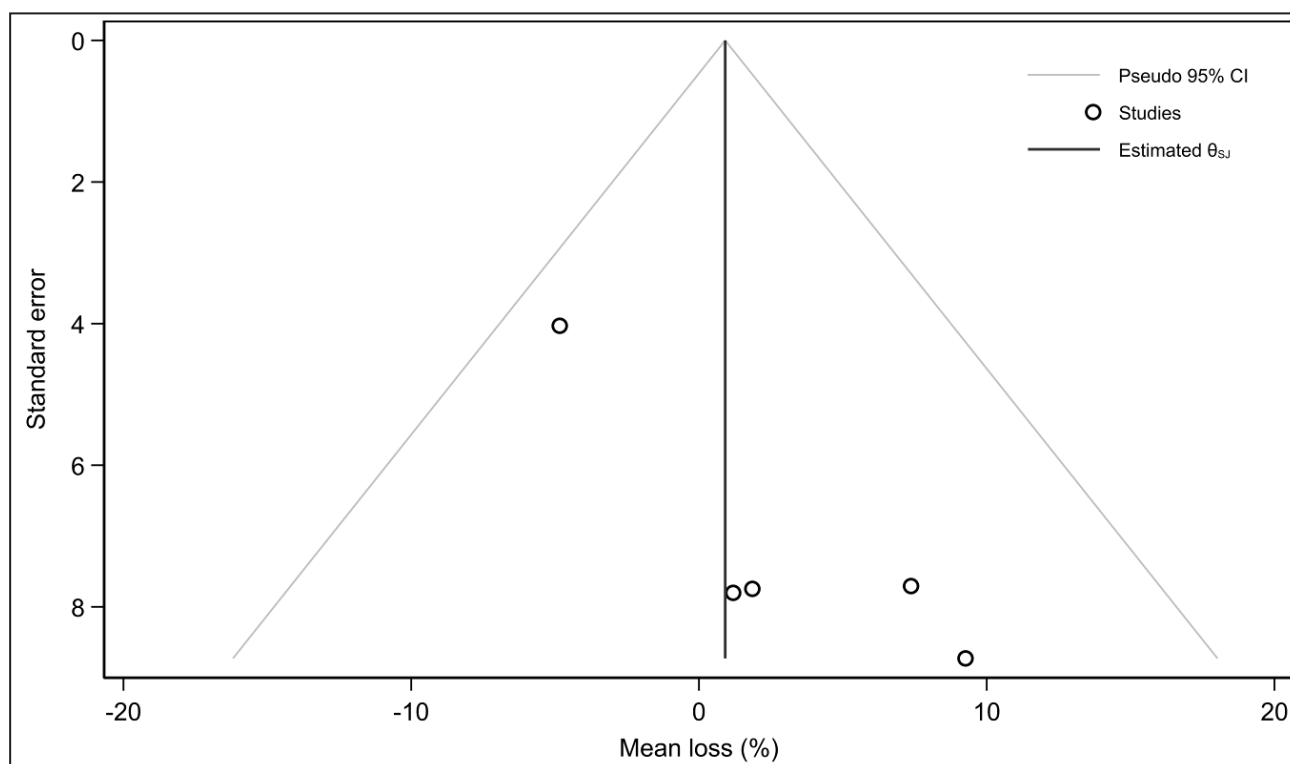
**Figure 2.** Random-effects meta-analysis using Sidik-Jonkman estimation method revealing no statistically significant differences in absolute (mm<sup>3</sup>) volumetric changes between the used grafting materials.



**Figure 3.** Funnel plot to visualized heterogenicity among the included studies for assessment of differences in absolute (mm<sup>3</sup>) volumetric changes. Larger studies with higher power are placed towards the top (smaller standard errors) and lower powered studies towards the bottom. An asymmetry in the funnel plot indicate bias. Eggers test did not indicate small-study effects (P-value = 0.8982).



**Figure 4.** Random-effects meta-analysis using Sidik-Jonkman estimation method revealing no statistically significant differences in relative (%) volumetric changes between the used grafting materials.



**Figure 5.** Funnel plot to visualized heterogeneity among the included studies for assessment of differences in relative (%) volumetric changes. Larger studies with higher power are placed towards the top (smaller standard errors) and lower powered studies towards the bottom. An asymmetry in the funnel plot indicate bias. Eggers test did not indicate small-study effects (P-value = 0.0987).

**Quality assessment**

The quality of the included studies is summarized in Table 3. All the included studies were characterized by unclear risk of bias [34-37].

**DISCUSSION**

The objective of the present systematic review and meta-analysis was to test the hypothesis of no difference in the volumetric stability of the grafting material following MSFA applying the lateral window technique with autogenous bone graft compared with a composite grafting material or bone substitute alone using three-dimensional radiographic measurements. Electronic search and hand-searching resulted

in 102 entries after duplicates have been removed. Four randomized controlled trials with unclear risk of bias fulfilled the inclusion criteria and were included in the final synthesis [34-37]. The volumetric stability of the grafting material following MSFA was significantly improved by mixing autogenous bone graft with a non-resorbable xenograft compared with autogenous bone graft [34]. Meta-analyses assessing absolute and relative volumetric changes of the grafting material revealed no significant differences between autogenous bone graft and allogeneic bone, synthetic biomaterials combined with autogenous bone graft or used alone. Consequently, the volumetric stability of the grafting material seems to be better preserved with a mixture of autogenous bone graft and a non-resorbable xenograft compared with alternate grafting materials.

**Table 3.** Quality assessment of included studies

Author	Random sequence generation	Allocation concealment	Patient blinding	Outcome blinding	Incomplete outcome data addressed	Selective reporting
Cosso et al. [34]	?	+	?	+	?	+
Gorla et al. [35]	+	+	?	+	?	+
Xavier et al. [36]	+	+	?	?	?	?
Pereira et al. [37]	+	+	?	+	?	+

+ = low risk of bias; ÷ = high risk of bias; ? = unclear risk of bias.

However, correlation between the volumetric stability of the grafting material and potential predictive parameters were not assessed in any of the included studies. Moreover, only four studies using three-dimensional radiographic measurements with an unclear risk of bias and various methodological confounding factors were included. Therefore, conclusions drawn from this systematic review should be interpreted with pronounced caution and further randomized controlled trials are needed before definitive conclusions can be provided.

Volumetric and dimensional stability of the grafting material represents an important factor for successful long-term implant treatment outcome following MSFA [24]. Autogenous bone graft, xenograft, allogeneic bone and synthetic biomaterials have previously been used as grafting material in conjunction with MSFA revealing different remodelling rates [33,42,43]. A previous systematic review concluded that volumetric reduction of the augmented area following MSFA is inevitable regardless of the used grafting material [17,18]. However, the degree of volumetric reduction seems to be influenced by patient characteristics, anatomical physiognomies of the maxillary sinus as well as chemical and physical properties of the grafting material [25,26]. Autogenous bone graft is generally accepted as the golden standard for alveolar ridge augmentation but pronounced volumetric reduction of the augmented area has been reported in several studies following MSFA [11,15,16,26,34-37]. Autogenous bone graft is therefore commonly combined with a bone substitute characterized by low substitution rate to diminish resorption and improve the long-term volumetric stability of the augmented area [3,4]. An experimental study in minipigs assessing MSFA with different compositions of autogenous bone graft and a xenograft disclosed that the augmented area was better preserved after addition of a xenograft and the volumetric reduction was significantly influenced by the ratio of xenograft and autogenous bone graft [15]. These conclusions seem to be in accordance with the results of the present systematic review indicating that the volumetric stability of the augmented area was significantly improved by combining autogenous bone graft with a non-resorbable xenograft [34], whereas mixtures of synthetic biomaterials and autogenous bone graft display no beneficial improvement in preservation of the augmented area compared with autogenous bone graft alone [35-37].

The volumetric stability of the grafting material following MSFA seems to be influenced by potential predictive parameters including anatomical characteristics of the maxillary sinus, presurgical

residual alveolar bone height, loss of multiple teeth in relation to the same sinus, ventilation of the maxillary sinus and age of the patient [25,26]. A previous study concluded that patient characteristics including presurgical alveolar bone height and age of the patient significantly influence the volumetric stability of the grafting material following MSFA with autogenous bone graft from the iliac crest [26]. Increased resorption of the grafting material was observed in younger patients and also when the presurgical higher alveolar bone was relatively high, as evaluated by three-dimensional CBCT measurements [26]. Furthermore, a recent study concluded that a wide sinus, large lateromedial angle, and loss of multiple teeth under the same sinus strongly predict increased resorption of the grafting material following MSFA with a xenograft, as evaluated by three-dimensional CBCT measurements [25]. It has been speculated that endosinus air flow and tension of the Schneiderian membrane could cause pressure on the augmented area and accelerate resorption of the grafting material [44]. Simultaneous placement of implants could therefore contribute to maintenance of the augmented area following MSFA and withstand resorption of the grafting material [45]. However, a previous study demonstrated no significant differences in volumetric resorption of the grafting material between delayed and simultaneous placement of implants following MSFA with a xenograft, as evaluated by three-dimensional CBCT measurements [46]. In the present systematic review, delayed implant placement was conducted in two studies [35,36], while timing of implant placement was not described in the other studies [34,37]. Consequently, patient characteristics, anatomical physiognomies of the maxillary sinus and features of the used grafting material seem to influence the volumetric stability of the augmented area following MSFA. However, none of the included studies of the present systematic review evaluated the association between volumetric changes of the grafting material and potential predictive parameters. A long-term retrospective study has demonstrated significant resorption of the augmented area during the first year following MSFA with autogenous bone graft from the iliac crest, after which the resorption slowed down and the height of the augmented area seemed to be stabilized [47]. The observation period of included studies of the present systematic review varied between six and 12 months [34-37]. Consequently, further randomized controlled trials with a longer observation period are needed before final conclusions can be provided about the volumetric stability of different grafting materials following MSFA.

A systematic review is a transparent and reproducible method to identify, select and critically evaluate published or unpublished literature to answer a well-defined research question. Systematic reviews are often combined with a meta-analysis, which is a statistical analysis that combines numerical data withdrawal from comparable studies. Systematic reviews and meta-analyses are generally considered to be the highest quality evidence. However, the strength of evidence from a systematic review and meta-analysis is related to the quality of the included studies. Four randomized controlled trials with a short-term observation period and unclear risk of bias were included in the present systematic review [34-37]. Consequently, the current level of evidence is inadequate to propose clinical recommendations according to the focus question of the present systematic review, though autogenous bone graft combined with a non-resorbable xenograft seems to improve the volumetric stability of the grafting material following MSFA.

## CONCLUSIONS

The present systematic review revealed that the volumetric stability of the grafting material following maxillary sinus floor augmentation was significantly improved with a mixture of autogenous bone graft and xenograft compared with autogenous bone graft. Meta-analysis assessing absolute and relative volumetric changes of the grafting material showed

no significant differences between autogenous bone graft compared with allogeneic bone and synthetic biomaterial used alone or combined with autogenous bone graft. The degree of volumetric changes of the grafting material following maxillary sinus floor augmentation seems to be influenced by patient characteristics, anatomical physiognomies of the maxillary sinus as well as chemical and physical properties of the grafting material. However, correlation between the volumetric stability of the grafting material and potential predictive parameters were not assessed in any of the included studies. Moreover, only four studies using three-dimensional radiographic measurements with an unclear risk of bias and various methodological confounding factors were included. Therefore, conclusions drawn from this systematic review should be interpreted with pronounced caution and further randomized controlled trials are needed before definitive conclusions can be provided.

## ACKNOWLEDGMENTS AND DISCLOSURE STATEMENTS

The authors declare that there are no financial or other conflicts of interest related to this publication. The authors would like to give a special thanks to Ms. Jette Frost Jepsen (Medical Library, Aalborg University Hospital, Aalborg, Denmark) for her assistance with the search strategy. There were no sources of funding for this systematic review.

## REFERENCES

1. Starch-Jensen T, Aludden H, Hallman M, Dahlin C, Christensen AE, Mordenfeld A. A systematic review and meta-analysis of long-term studies (five or more years) assessing maxillary sinus floor augmentation. *Int J Oral Maxillofac Surg.* 2018 Jan;47(1):103-116. [Medline: [28545806](#)] [doi: [10.1016/j.ijom.2017.05.001](#)]
2. Starch-Jensen T, Mordenfeld A, Becktor JP, Jensen SS. Maxillary Sinus Floor Augmentation With Synthetic Bone Substitutes Compared With Other Grafting Materials: A Systematic Review and Meta-analysis. *Implant Dent.* 2018 Jun;27(3):363-374. [Medline: [29771732](#)] [doi: [10.1097/ID.0000000000000768](#)]
3. Starch-Jensen T, Jensen JD. Maxillary Sinus Floor Augmentation: a Review of Selected Treatment Modalities. *J Oral Maxillofac Res.* 2017 Sep 30;8(3):e3. [Medline: [29142655](#)] [PMC free article: [5676313](#)] [doi: [10.5037/jomr.2017.8303](#)]
4. Jensen T, Schou S, Stavropoulos A, Terheyden H, Holmstrup P. Maxillary sinus floor augmentation with Bio-Oss or Bio-Oss mixed with autogenous bone as graft: a systematic review. *Clin Oral Implants Res.* 2012 Mar;23(3):263-73. [Medline: [21443592](#)] [doi: [10.1111/j.1600-0501.2011.02168.x](#)]
5. Raghoobar GM, Onclin P, Boven GC, Vissink A, Meijer HJA. Long-term effectiveness of maxillary sinus floor augmentation: A systematic review and meta-analysis. *J Clin Periodontol.* 2019 Jun;46 Suppl 21:307-318. [Medline: [30624789](#)] [doi: [10.1111/jcpe.13055](#)]
6. Antonoglou GN, Stavropoulos A, Samara MD, Ioannidis A, Benic GI, Papageorgiou SN, Sándor GK. Clinical Performance of Dental Implants Following Sinus Floor Augmentation: A Systematic Review and Meta-Analysis of Clinical Trials with at Least 3 Years of Follow-up. *Int J Oral Maxillofac Implants.* 2018 May/Jun;33(3):e45-e65. [Medline: [29763503](#)] [doi: [10.11607/jomi.6417](#)]
7. Yang J, Xia T, Wang H, Cheng Z, Shi B. Outcomes of maxillary sinus floor augmentation without grafts in atrophic maxilla: A systematic review and meta-analysis based on randomised controlled trials. *J Oral Rehabil.* 2019 Mar;46(3):282-290. [Medline: [30537184](#)] [doi: [10.1111/joor.12753](#)]

8. Esposito M, Grusovin MG, Rees J, Karasoulos D, Felice P, Alissa R, Worthington H, Coulthard P. Effectiveness of sinus lift procedures for dental implant rehabilitation: a Cochrane systematic review. *Eur J Oral Implantol*. 2010 Spring;3(1):7-26. [Medline: [20467595](#)]
9. Stumbras A, Krukis MM, Januzis G, Juodzbalys G. Regenerative bone potential after sinus floor elevation using various bone graft materials: a systematic review. *Quintessence Int*. 2019;50(7):548-558. [Medline: [31086858](#)] [doi: [10.3290/j.qi.a42482](#)]
10. Starch-Jensen T, Deluiz D, Bruun NH, Tinoco EMB. Maxillary Sinus Floor Augmentation with Autogenous Bone Graft Alone Compared with Alternate Grafting Materials: a Systematic Review and Meta-Analysis Focusing on Histomorphometric Outcome. *J Oral Maxillofac Res*. 2020 Nov 30;11(3):e2. [Medline: [33262881](#)] [PMC free article: [7644272](#)] [doi: [10.5037/jomr.2020.11302](#)]
11. Sakkas A, Wilde F, Heufelder M, Winter K, Schramm A. Autogenous bone grafts in oral implantology-is it still a “gold standard”? A consecutive review of 279 patients with 456 clinical procedures. *Int J Implant Dent*. 2017 Dec;3(1):23. [Medline: [28573552](#)] [PMC free article: [5453915](#)] [doi: [10.1186/s40729-017-0084-4](#)]
12. Clavero J, Lundgren S. Ramus or chin grafts for maxillary sinus inlay and local onlay augmentation: comparison of donor site morbidity and complications. *Clin Implant Dent Relat Res*. 2003;5(3):154-60. [Medline: [14575631](#)] [doi: [10.1111/j.1708-8208.2003.tb00197.x](#)]
13. Nkenke E, Neukam FW. Autogenous bone harvesting and grafting in advanced jaw resorption: morbidity, resorption and implant survival. *Eur J Oral Implantol*. 2014 Summer;7 Suppl 2:S203-17. [Medline: [24977256](#)]
14. Carlsen A, Gorst-Rasmussen A, Jensen T. Donor site morbidity associated with autogenous bone harvesting from the ascending mandibular ramus. *Implant Dent*. 2013 Oct;22(5):503-6. [Medline: [23792652](#)] [doi: [10.1097/ID.0b013e318296586c](#)]
15. Jensen T, Schou S, Svendsen PA, Forman JL, Gundersen HJ, Terheyden H, Holmstrup P. Volumetric changes of the graft after maxillary sinus floor augmentation with Bio-Oss and autogenous bone in different ratios: a radiographic study in minipigs. *Clin Oral Implants Res*. 2012 Aug;23(8):902-10. [Medline: [22044477](#)] [doi: [10.1111/j.1600-0501.2011.02245.x](#)]
16. Johansson B, Grepe A, Wannfors K, Hirsch JM. A clinical study of changes in the volume of bone grafts in the atrophic maxilla. *Dentomaxillofac Radiol*. 2001 May;30(3):157-61. [Medline: [11420628](#)] [doi: [10.1038/sj.dmf.4600601](#)]
17. Shanbhag S, Shanbhag V, Stavropoulos A. Volume changes of maxillary sinus augmentations over time: a systematic review. *Int J Oral Maxillofac Implants*. 2014 Jul-Aug;29(4):881-92. [Medline: [25032768](#)] [doi: [10.11607/jomi.3472](#)]
18. Kirmeier R, Payer M, Wehrsuetz M, Jakse N, Platzer S, Lorenzoni M. Evaluation of three-dimensional changes after sinus floor augmentation with different grafting materials. *Clin Oral Implants Res*. 2008 Apr;19(4):366-72. [Medline: [18324958](#)] [doi: [10.1111/j.1600-0501.2007.01487.x](#)]
19. Hallman M, Hedin M, Sennerby L, Lundgren S. A prospective 1-year clinical and radiographic study of implants placed after maxillary sinus floor augmentation with bovine hydroxyapatite and autogenous bone. *J Oral Maxillofac Surg*. 2002 Mar;60(3):277-84; discussion 285-6. [Medline: [11887139](#)] [doi: [10.1053/joms.2002.30576](#)]
20. Hatano N, Shimizu Y, Ooya K. A clinical long-term radiographic evaluation of graft height changes after maxillary sinus floor augmentation with a 2:1 autogenous bone/xenograft mixture and simultaneous placement of dental implants. *Clin Oral Implants Res*. 2004 Jun;15(3):339-45. [Medline: [15142097](#)] [doi: [10.1111/j.1600-0501.2004.00996.x](#)]
21. Kim YK, Yun PY, Kim SG, Kim BS, Ong JL. Evaluation of sinus bone resorption and marginal bone loss after sinus bone grafting and implant placement. *Oral Surg Oral Med Oral Pathol Oral Radiol Endod*. 2009 Feb;107(2):e21-8. [Medline: [19138634](#)] [doi: [10.1016/j.tripleo.2008.09.033](#)]
22. Kirmeier R, Arnetzl S, Robl T, Payer M, Lorenzoni M, Jakse N. Reproducibility of volumetric measurements on maxillary sinuses. *Int J Oral Maxillofac Surg*. 2011 Feb;40(2):195-9. [Medline: [21074367](#)] [doi: [10.1016/j.ijom.2010.10.008](#)]
23. Arasawa M, Oda Y, Kobayashi T, Uoshima K, Nishiyama H, Hoshina H, Saito C. Evaluation of bone volume changes after sinus floor augmentation with autogenous bone grafts. *Int J Oral Maxillofac Surg*. 2012 Jul;41(7):853-7. [Medline: [22551647](#)] [doi: [10.1016/j.ijom.2012.01.020](#)]
24. Kwon JJ, Hwang J, Kim YD, Shin SH, Cho BH, Lee JY. Automatic three-dimensional analysis of bone volume and quality change after maxillary sinus augmentation. *Clin Implant Dent Relat Res*. 2019 Dec;21(6):1148-1155. [Medline: [31651078](#)] [doi: [10.1111/cid.12853](#)]
25. Zhang L, Si M, Shi J, Yang G, Shi Y. Evaluation of three-dimensional contraction of the volume of grafts after staged augmentation of the sinus floor, and an analysis of influential factors. *Br J Oral Maxillofac Surg*. 2019 May;57(4):323-329. [Medline: [30940406](#)] [doi: [10.1016/j.bjoms.2019.03.006](#)]
26. Klijn RJ, van den Beucken JJ, Bronkhorst EM, Berge SJ, Meijer GJ, Jansen JA. Predictive value of ridge dimensions on autologous bone graft resorption in staged maxillary sinus augmentation surgery using Cone-Beam CT. *Clin Oral Implants Res*. 2012 Apr;23(4):409-15. [Medline: [22092724](#)] [doi: [10.1111/j.1600-0501.2011.02342.x](#)]
27. Welch V, Petticrew M, Tugwell P, Moher D, O'Neill J, Waters E, White H; PRISMA-Equity Bellagio group. PRISMA-Equity 2012 extension: reporting guidelines for systematic reviews with a focus on health equity. *PLoS Med*. 2012;9(10):e1001333. [Medline: [23222917](#)] [PMC free article: [3484052](#)] [doi: [10.1371/journal.pmed.1001333](#)]
28. Higgins JPT, Altman DG, Sterne JAC. Chapter 8: assessing risk of bias in included studies. In: Higgins JPT, Green S, editors. *Cochrane handbook for systematic reviews of interventions* version 5.1.0 (updated March 2011). The Cochrane Collaboration. 2011. [URL: <http://handbook.cochrane.org/>]

29. Higgins JP, Altman DG, Gøtzsche PC, Jüni P, Moher D, Oxman AD, Savovic J, Schulz KF, Weeks L, Sterne JA; Cochrane Bias Methods Group; Cochrane Statistical Methods Group. The Cochrane Collaboration's tool for assessing risk of bias in randomised trials. *BMJ*. 2011 Oct 18;343:d5928. [Medline: [22008217](#)] [PMC free article: [3196245](#)] [doi: [10.1136/bmj.d5928](#)]
30. Hujuel PP. Design and analysis issues in split mouth clinical trials. *Community Dent Oral Epidemiol*. 1998 Apr;26(2): 85-6. [Medline: [9645400](#)] [doi: [10.1111/j.1600-0528.1998.tb01932.x](#)]
31. Menezes JD, Pereira RDS, Bonardi JP, Griza GL, Okamoto R, Hochuli-Vieira E. Bioactive glass added to autogenous bone graft in maxillary sinus augmentation: a prospective histomorphometric, immunohistochemical, and bone graft resorption assessment. *J Appl Oral Sci*. 2018 Jun 11;26:e20170296. [Medline: [29898173](#)] [PMC free article: [6007965](#)] [doi: [10.1590/1678-7757-2017-0296](#)]
32. Zijdeveld SA, Zerbo IR, van den Bergh JP, Schulten EA, ten Bruggenkate CM. Maxillary sinus floor augmentation using a beta-tricalcium phosphate (Cerasorb) alone compared to autogenous bone grafts. *Int J Oral Maxillofac Implants*. 2005 May-Jun;20(3):432-40. [Medline: [15973955](#)]
33. Kim ES, Moon SY, Kim SG, Park HC, Oh JS. Three-dimensional volumetric analysis after sinus grafts. *Implant Dent*. 2013 Apr;22(2):170-4. [Medline: [23399787](#)] [doi: [10.1097/ID.0b013e31827f3576](#)]
34. Cosso MG, de Brito RB Jr, Piattelli A, Shibli JA, Zenóbio EG. Volumetric dimensional changes of autogenous bone and the mixture of hydroxyapatite and autogenous bone graft in humans maxillary sinus augmentation. A multislice tomographic study. *Clin Oral Implants Res*. 2014 Nov;25(11):1251-1256. [Medline: [24102867](#)] [doi: [10.1111/clr.12261](#)]
35. Gorla LF, Spin-Neto R, Boos FB, Pereira Rdos S, Garcia-Junior IR, Hochuli-Vieira E. Use of autogenous bone and beta-tricalcium phosphate in maxillary sinus lifting: a prospective, randomized, volumetric computed tomography study. *Int J Oral Maxillofac Surg*. 2015 Dec;44(12):1486-91. [Medline: [26232120](#)] [doi: [10.1016/j.ijom.2015.07.003](#)]
36. Xavier SP, Silva ER, Kahn A, Chaushu L, Chaushu G. Maxillary Sinus Grafting with Autograft Versus Fresh-Frozen Allograft: A Split-Mouth Evaluation of Bone Volume Dynamics. *Int J Oral Maxillofac Implants*. 2015 Sep-Oct;30(5):1137-42. [Medline: [26394351](#)] [doi: [10.11607/jomi.3924](#)]
37. Pereira RS, Menezes JD, Bonardi JP, Griza GL, Okamoto R, Hochuli-Vieira E. Comparative study of volumetric changes and trabecular microarchitecture in human maxillary sinus bone augmentation with bioactive glass and autogenous bone graft: a prospective and randomized assessment. *Int J Oral Maxillofac Surg*. 2018 May;47(5):665-671. [Medline: [29246424](#)] [doi: [10.1016/j.ijom.2017.11.016](#)]
38. Dos Santos Pereira R, Boos FB, Gorla LF, Garcia IR Jr, Okamoto R, Hochuli-Vieira E. Maxillary Sinus Elevation Surgery with ChronOS and Autogenous Bone Graft: Analysis of Histometric and Volumetric Changes. *Int J Periodontics Restorative Dent*. 2016 Nov/Dec;36(6):885-892. [Medline: [27740652](#)] [doi: [10.11607/prd.2404](#)]
39. Szabó G, Suba Z, Hrabák K, Barabás J, Németh Z. Autogenous bone versus beta-tricalcium phosphate graft alone for bilateral sinus elevations (2- and 3-dimensional computed tomographic, histologic, and histomorphometric evaluations): preliminary results. *Int J Oral Maxillofac Implants*. 2001 Sep-Oct;16(5):681-92. [Medline: [11669251](#)]
40. Dellavia C, Speroni S, Pellegrini G, Gatto A, Maiorana C. A new method to evaluate volumetric changes in sinus augmentation procedure. *Clin Implant Dent Relat Res*. 2014 Oct;16(5):684-90. [Medline: [23509966](#)] [doi: [10.1111/cid.12058](#)]
41. Szabó G, Huys L, Coulthard P, Maiorana C, Garagiola U, Barabás J, Németh Z, Hrabák K, Suba Z. A prospective multicenter randomized clinical trial of autogenous bone versus beta-tricalcium phosphate graft alone for bilateral sinus elevation: histologic and histomorphometric evaluation. *Int J Oral Maxillofac Implants*. 2005 May-Jun;20(3):371-81. [Medline: [15973948](#)]
42. Gultekin BA, Cansiz E, Borahan O, Mangano C, Kolerman R, Mijiritsky E, Yalcin S. Evaluation of Volumetric Changes of Augmented Maxillary Sinus With Different Bone Grafting Biomaterials. *J Craniofac Surg*. 2016 Mar;27(2):e144-8. [Medline: [26890457](#)] [doi: [10.1097/SCS.0000000000002393](#)]
43. Coopman R, Fennis J, Ghaemina H, Van de Vyvere G, Politis C, Hoppenreijts TJM. Volumetric osseous changes in the completely edentulous maxilla after sinus grafting and lateral bone augmentation: a systematic review. *Int J Oral Maxillofac Surg*. 2020 Nov;49(11):1470-1480. [Medline: [32241580](#)] [doi: [10.1016/j.ijom.2020.03.001](#)]
44. Asai S, Shimizu Y, Ooya K. Maxillary sinus augmentation model in rabbits: effect of occluded nasal ostium on new bone formation. *Clin Oral Implants Res*. 2002 Aug;13(4):405-9. [Medline: [12175378](#)] [doi: [10.1034/j.1600-0501.2002.130409.x](#)]
45. Cricchio G, Sennerby L, Lundgren S. Sinus bone formation and implant survival after sinus membrane elevation and implant placement: a 1- to 6-year follow-up study. *Clin Oral Implants Res*. 2011 Oct;22(10):1200-1212. [Medline: [21906186](#)] [doi: [10.1111/j.1600-0501.2010.02096.x](#)]
46. Mazzocco F, Lops D, Gobbato L, Lolato A, Romeo E, del Fabbro M. Three-dimensional volume change of grafted bone in the maxillary sinus. *Int J Oral Maxillofac Implants*. 2014 Jan-Feb;29(1):178-84. [Medline: [24451869](#)] [doi: [10.11607/jomi.3236](#)]
47. Schmitt C, Karasholi T, Lutz R, Wiltfang J, Neukam FW, Schlegel KA. Long-term changes in graft height after maxillary sinus augmentation, onlay bone grafting, and combination of both techniques: a long-term retrospective cohort study. *Clin Oral Implants Res*. 2014 Feb;25(2):e38-46. [Medline: [23075057](#)] [doi: [10.1111/clr.12045](#)]

**To cite this article:**

Starch-Jensen T, Deluiz D, Vitenson J, Bruun NH, Tinoco EMB.

Maxillary Sinus Floor Augmentation with Autogenous Bone Graft Compared with a Composite Grafting Material or Bone Substitute Alone: a Systematic Review and Meta-Analysis Assessing Volumetric Stability of the Grafting Material

J Oral Maxillofac Res 2021;12(1):e1

URL: <http://www.ejomr.org/JOMR/archives/2021/1/e1/v12n1e1.pdf>

doi: [10.5037/jomr.2021.12101](https://doi.org/10.5037/jomr.2021.12101)

**Copyright** © Starch-Jensen T, Deluiz D, Vitenson J, Bruun NH, Tinoco EMB. Published in the JOURNAL OF ORAL & MAXILLOFACIAL RESEARCH (<http://www.ejomr.org>), 31 March 2021.

This is an open-access article, first published in the JOURNAL OF ORAL & MAXILLOFACIAL RESEARCH, distributed under the terms of the [Creative Commons Attribution-Noncommercial-No Derivative Works 3.0 Unported License](https://creativecommons.org/licenses/by-nc-nd/3.0/), which permits unrestricted non-commercial use, distribution, and reproduction in any medium, provided the original work and is properly cited. The copyright, license information and link to the original publication on (<http://www.ejomr.org>) must be included.



Appendix 1. PubMed search until the 9<sup>th</sup> of October 2020

Search	Query	Results
#29	Search: (((((((("Sinus Floor Augmentation"[Mesh]) OR (sinus floor augmentation*[Text Word])) OR (sinus augmentation*[Text Word])) OR (sinus floor elevation*[Text Word])) OR (sinus elevation*[Text Word])) OR (sinus lift*[Text Word])) OR (sinus floor lift*[Text Word])) AND (((Autogenous bone*[Text Word]) OR (Autologous bone*[Text Word])) OR (bone graft*[Text Word]))) AND (((((Volumetric chang*[Text Word]) OR (Dimensional chang*[Text Word])) OR (Three-dimension*[Text Word])) OR (3d[Text Word])) OR (volume*[Text Word] AND chang*[Text Word])) OR (3-dimension*[Text Word]))) AND (((((((("Controlled Clinical Trial"[Publication Type]) OR "Controlled Clinical Trials as Topic"[Mesh])) OR (((random*[Text Word] OR controlled[Text Word] OR crossover[Text Word] OR cross-over[Text Word] OR blind*[Text Word] OR mask*[Text Word])) AND (trial[Text Word] OR trials[Text Word] OR study[Text Word] OR studies[Text Word] OR analys*[Text Word] OR analyz*[Text Word])) OR rct[Text Word]) OR (((singl*[Text Word] OR doubl*[Text Word] OR tripl*[Text Word])) AND (blind[Text Word] OR mask[Text Word]))) OR placebo[Text Word]) OR (retrospect*[Text Word] OR prospect*[Text Word])) Sort by: Publication Date	<a href="#">46</a>
#28	Search: (((((((("Controlled Clinical Trial"[Publication Type]) OR "Controlled Clinical Trials as Topic"[Mesh])) OR (((random*[Text Word] OR controlled[Text Word] OR crossover[Text Word] OR cross-over[Text Word] OR blind*[Text Word] OR mask*[Text Word])) AND (trial[Text Word] OR trials[Text Word] OR study[Text Word] OR studies[Text Word] OR analys*[Text Word] OR analyz*[Text Word])) OR rct[Text Word]) OR (((singl*[Text Word] OR doubl*[Text Word] OR tripl*[Text Word])) AND (blind[Text Word] OR mask[Text Word]))) OR placebo[Text Word]) OR (retrospect*[Text Word] OR prospect*[Text Word])) Sort by: Publication Date	<a href="#">3,481,939</a>
#27	Search: (((((((("Sinus Floor Augmentation"[Mesh]) OR (sinus floor augmentation*[Text Word])) OR (sinus augmentation*[Text Word])) OR (sinus floor elevation*[Text Word])) OR (sinus elevation*[Text Word])) OR (sinus lift*[Text Word])) OR (sinus floor lift*[Text Word])) AND (((Autogenous bone*[Text Word]) OR (Autologous bone*[Text Word])) OR (bone graft*[Text Word]))) AND (((((Volumetric chang*[Text Word]) OR (Dimensional chang*[Text Word])) OR (Three-dimension*[Text Word])) OR (3d[Text Word])) OR (volume*[Text Word] AND chang*[Text Word])) OR (3-dimension*[Text Word])) Sort by: Publication Date	<a href="#">112</a>
#26	Search: (((((Volumetric chang*[Text Word]) OR (Dimensional chang*[Text Word])) OR (Three-dimension*[Text Word])) OR (3d[Text Word])) OR (volume*[Text Word] AND chang*[Text Word])) OR (3-dimension*[Text Word]) Sort by: Publication Date	<a href="#">535,641</a>
#25	Search: 3-dimension*[Text Word] Sort by: Publication Date	<a href="#">24,006</a>
#21	Search: volume*[Text Word] AND chang*[Text Word] Sort by: Publication Date	<a href="#">170,090</a>
#18	Search: 3d[Text Word] Sort by: Publication Date	<a href="#">188,546</a>
#17	Search: Three-dimension*[Text Word] Sort by: Publication Date	<a href="#">252,801</a>
#16	Search: Dimensional chang*[Text Word] Sort by: Publication Date	<a href="#">1,977</a>
#14	Search: Volumetric chang*[Text Word] Sort by: Publication Date	<a href="#">1,442</a>
#13	Search: (((((((("Sinus Floor Augmentation"[Mesh]) OR (sinus floor augmentation*[Text Word])) OR (sinus augmentation*[Text Word])) OR (sinus floor elevation*[Text Word])) OR (sinus elevation*[Text Word])) OR (sinus lift*[Text Word])) OR (sinus floor lift*[Text Word])) AND (((Autogenous bone*[Text Word]) OR (Autologous bone*[Text Word])) OR (bone graft*[Text Word]))) Sort by: Publication Date	<a href="#">1,031</a>
#12	Search: ((Autogenous bone*[Text Word]) OR (Autologous bone*[Text Word])) OR (bone graft*[Text Word]) Sort by: Publication Date	<a href="#">35,551</a>
#11	Search: bone graft*[Text Word] Sort by: Publication Date	<a href="#">27,638</a>
#10	Search: Autologous bone*[Text Word] Sort by: Publication Date	<a href="#">9,091</a>
#9	Search: Autogenous bone*[Text Word] Sort by: Publication Date	<a href="#">3,592</a>
#8	Search: (((((((("Sinus Floor Augmentation"[Mesh]) OR (sinus floor augmentation*[Text Word])) OR (sinus augmentation*[Text Word])) OR (sinus floor elevation*[Text Word])) OR (sinus elevation*[Text Word])) OR (sinus lift*[Text Word])) OR (sinus floor lift*[Text Word])) Sort by: Publication Date	<a href="#">2,876</a>
#7	Search: sinus floor lift*[Text Word] Sort by: Publication Date	<a href="#">30</a>
#6	Search: sinus lift*[Text Word] Sort by: Publication Date	<a href="#">1,012</a>
#5	Search: sinus elevation*[Text Word] Sort by: Publication Date	<a href="#">394</a>
#4	Search: sinus floor elevation*[Text Word] Sort by: Publication Date	<a href="#">787</a>
#3	Search: sinus augmentation*[Text Word] Sort by: Publication Date	<a href="#">1,086</a>
#2	Search: sinus floor augmentation*[Text Word] Sort by: Publication Date	<a href="#">1,493</a>
#1	Search: "Sinus Floor Augmentation"[Mesh] Sort by: Most Recent	<a href="#">1,149</a>

Appendix 2. Embase search until the 9<sup>th</sup> of October 2020

No.	Query	Results
#31	#30 AND ('article'/it OR 'review'/it)	77
#30	#21 AND #29	79
#29	#22 OR #23 OR #24 OR #25 OR #26 OR #27 OR #28	10027081
#28	retrospect*:ti,ab,de OR prospect*:ti,ab,de	2608240
#27	'prospective study'/de	630145
#26	'retrospective study'/de	970702
#25	((single OR double OR triple) NEAR/2 (blind* OR mask*)):ti,ab,de) OR placebo:ti,ab,de	600023
#24	((random* OR controlled* OR crossover OR 'cross over' OR blind* OR mask*) NEAR/3 (trial* OR study OR studies OR analy*)):ti,ab,de) OR rct:ti,ab,de	8268457
#23	'randomized controlled trial'/exp	622868
#22	'controlled clinical trial'/exp	794629
#21	#15 AND #20	179
#20	#16 OR #17 OR #18 OR #19	492653
#19	volume* NEAR/4 chang*	44647
#18	'three-dimension*' OR 3d OR '3-dimension*'	449946
#17	'dimensional chang*'	2058
#16	'volumetric chang*'	2135
#15	#8 AND #14	1915
#14	#9 OR #10 OR #11 OR #12 OR #13	64275
#13	'bone graft'/exp	35223
#12	'bone graft*'	45598
#11	'autologous bone*'	14473
#10	'autogenous bone*'	3978
#9	'autogenous bone graft'/de	19
#8	#1 OR #2 OR #3 OR #4 OR #5 OR #6 OR #7	2859
#7	'sinus lift*'	1049
#6	'sinus floor lift*'	32
#5	'sinus elevation*'	388
#4	'sinus floor elevation*'	797
#3	'sinus augmentation*'	1071
#2	'sinus floor augmentation*'	1436
#1	'sinus floor augmentation'/de	1176

Appendix 3. Cochrane Library search until the 9<sup>th</sup> of October 2020

ID	Search	Hits
#1	MeSH descriptor: [Sinus Floor Augmentation] explode all trees	148
#2	(sinus floor augmentation):ti,ab,kw	297
#3	(sinus augmentation):ti,ab,kw	442
#4	(sinus floor elevation*):ti,ab,kw	193
#5	(sinus elevation*):ti,ab,kw	333
#6	(sinus floor lift*):ti,ab,kw	109
#7	(sinus lift*):ti,ab,kw	202
#8	{OR #1-#7}	705
#9	(autogenous bone):ti,ab,kw	602
#10	(autologous bone):ti,ab,kw	3339
#11	(bone NEXT graft*):ti,ab,kw	1968
#12	{OR #9-#11}	5078
#13	#8 and #12	245
#14	(volume* NEAR/4 chang*):ti,ab,kw	4248
#15	(dimensional chang*):ti,ab,kw	2058
#16	("three-dimensional"):ti,ab,kw	4138
#17	("3-dimensional"):ti,ab,kw	1049
#18	(3d):ti,ab,kw	4957
#19	{OR #14-#18}	13219
#20	#13 and #19 in Trials	27