

## Diagnostic Efficacy of MRCP and Ultrasound on Obstructive Jaundice-A Prospective Study

Muhammad Usaid Baig\*

Bachelors in Medical Imaging Technology, Department of Allied Health Sciences, Superior College Lahore, University Campus, 17-KM Raiwaind Road, Kot Arain, Lahore, Pakistan

Ahmed Qayyum

Bachelors in Medical Imaging Technology, Department of Allied Health Sciences, Superior College Lahore, University Campus, 17-KM Raiwaind Road, Kot Arain, Lahore, Pakistan

Aiman Arshad

Bachelors of Medical Imaging Technology, Department of Allied Health Sciences, Superior College Lahore, University Campus, 17-KM Raiwaind Road, Kot Arain, Lahore, Pakistan

Abdul Basit

Bachelors of Medical Imaging Technology, Department of Allied Health Sciences, Superior College Lahore, University Campus, 17-KM Raiwaind Road, Kot Arain, Lahore, Pakistan

Muhammad Sarwar

Bachelors of Medical Imaging Technology, Department of Allied Health Sciences, Superior College Lahore, University Campus, 17-KM Raiwaind Road, Kot Arain, Lahore, Pakistan

Hafiz Muhammad Rizwan

Masters in Medical Imaging Technology, Lecturer, Department of Allied Health Sciences, Superior College Lahore, University Campus, 17-KM Raiwaind Road, Kot Arain, Lahore, Pakistan

Rana Muhammad Athar Azeem Shams

Masters in Medical Imaging Technology, Lecturer, Department of Allied Health Sciences, Superior College Lahore, University Campus, 17-KM Raiwaind Road, Kot Arain, Lahore, Pakistan

Rana Muhammad Bakhtawar Khan Sajawal

Masters in Mathematics, Lecturer, Department of Allied Health Sciences, Superior College Lahore, University Campus, 17-KM Raiwaind Road, Kot Arain, Lahore, Pakistan

Sybil Rose

Masters in Diagnostic Ultrasound, Lecturer, Department of Allied Health Sciences, Superior College Lahore, University Campus, 17-KM Raiwaind Road, Kot Arain, Lahore, Pakistan

Hafiz Zubair Yonus

Bachelors in Medical Imaging Technology, Lecturer, Department of Allied Health Sciences, Superior College Lahore, University Campus, 17-KM Raiwaind Road, Kot Arain, Lahore, Pakistan

Wasim Sajid

Masters in Diagnostic Ultrasound, Lecturer, Department of Allied Health Sciences, Superior College Lahore, University Campus, 17-KM Raiwaind Road, Kot Arain, Lahore, Pakistan

Zeeshan Khalid

Medical Imaging Doctor, Lecturer, Department of Allied Health Sciences, Superior College Lahore, University Campus, 17-KM Raiwaind Road, Kot Arain, Lahore, Pakistan

Amna Babar

Masters in Diagnostic Ultrasound, Lecturer, Department of Allied Health Sciences, Superior College Lahore, University Campus, 17-KM Raiwaind Road, Kot Arain, Lahore, Pakistan

*The research is financed by Asian Development Bank. No. 2006-A171(Sponsoring information)*

### Abstract

*Background:* Obstructive jaundice is a common pathological problem that occurs when there is an obstruction to

the passage of conjugated bilirubin from liver cells to intestine. Bile, a digestive fluid secreted and produce by the liver. Most common cause of obstructive jaundice is due to gallstones.

*Objective:* The aim of our study was to evaluate the diagnostic Efficacy of MRCP and Ultrasound on obstructive jaundice.

*Study design:* A cross-sectional prospective study was performed.

*Material & Method:* A cross-sectional prospective study was performed in 50 patients who came with the provisional diagnosis of obstructive jaundice were referred to ultrasound for primitive diagnosis and were then shifted to MRCP for a detailed diagnosis. The data was collected from the outpatient department facility of Pakistan Kidney and Liver Institute Hospital, Lahore. After informed consent, data was collected from MRI GE 1.5 Tesla, Ultrasound Canon Xanio.

*Results:* The results revealed that there are 50 patients of obstructive jaundice. 20 were females' patients and 30 were males' patients, with age raging from 20-40 years. There were 17 patients out of 50 in our study which ultrasound showed negative results that were positive on MRCP there were 28 patients that were positive on both ultrasound and MRCP. There were 3 patients that were positive on ultrasound but negative on MRCP and 2 patients that were negative on both modalities

*Conclusion:* Our study concluded that higher ratio of males then females in our sample size, RHC was positive in all the patients with dominant cause of jaundice was stone with in biliary channel. We found that MRCP has better efficiency comparative to ultrasound to detect jaundice and its etiology i.e., 90% true positive.

**Keywords:** Magnetic resonance cholangiopancreatography, Ultrasonography, Obstructive jaundice

**DOI:** 10.7176/JHMN/91-03

**Publication date:** July 31<sup>st</sup> 2021

## 1. Introduction

The biliary tree is a network of branching bile ducts that transport bile, a digestive fluid generated and secreted by the liver. Each hepatocyte produces bile, which is collected by many tiny tubular channels termed canaliculi at the cellular level<sup>[1]</sup>. The most common symptom of jaundice is a yellowish discoloration of the sclera. The free passage of bile from the liver to the gall bladder and ultimately to the small intestine is obstructed in obstructed jaundice. An increase in either the conjugated or unconjugated component can cause jaundice or a rise in total bilirubin. This is dependent on the degree to which normal bilirubin metabolism is disrupted<sup>[2]</sup>. Obstructive jaundice has been documented in a number of nations around the world, including Pakistan. The majority of benign causes were seen in people between the ages of 31 and 40, while malignant cases were more common in people between the ages of 51 and 70. There was a statistically significant difference in the age distribution of benign and malignant illness. The majority of patients, 56.66 percent, had malignant obstructive jaundice, whereas 43.33 percent had benign jaundice<sup>[3]</sup>. Cholestasis causes obstructive jaundice, which is a clinical sign. Cholestasis can be extrahepatic or intrahepatic, and it is frequently linked to biochemical abnormalities in liver function tests.<sup>[4]</sup> The most prevalent cause of distal common bile duct stricture is a peptic ulcer. Obstructive jaundice as a consequence of ulcerative duodenal stenosis can be difficult to distinguish from cancer, especially when an esophagogastroduodenoscopy test reveals no ulcer.<sup>[5]</sup> Gallbladder distension could occur if the thrombus was positioned below the common hepatic duct (CHD). In Ultrasonography (USG), tumor thrombi of the bile duct may be easily detected as low-, iso-, or high-echogenic masses. On a Color Doppler sonography, vascular signals could be observed at times (CDS). On MRI T1-weighted images, biliary tract tumor thrombi appear as hypointensity, hyperintensity on T2-weighted images, and contrast enhancement on dynamic MR images in the early stages. In all cases, MRCP revealed intrahepatic bile duct dilatation. MR scans clearly indicated biliary hemorrhage.<sup>[6]</sup> In our study we will compare the diagnostic efficacy of MRCP and Ultrasound so that medical practitioner will be clear that in which situation which will be the modality of choice in a patient with obstructive jaundice symptoms and how much a medical practitioner will rely on the results of MRCP and Ultrasound in some specific situations.

### 1.1 Material & Methods

A cross-sectional prospective study was performed in which 50 patients have feature of obstructive jaundice refer for ultrasonography and MRCP to get required results. All patients' data had been collected from outdoor, indoor and emergency department of Pakistan Kidney and Liver Institute Hospital, Lahore. After informed consent, data was collected from MRI GE 1.5 Tesla, Ultrasound Canon Xanio. 50 out of which 30 were male patients and 20 were females. Their age raging from 20-40 years. Study Duration of 4 months. Inclusion criteria include Patient with abdominal pain in right upper quadrant. Patient Age More then 12 year. Patients has Yellow skin and eyes, Easy bleeding and bruising, Lethargy, Dark color urine. Exclusion Criteria includes patient Age less than 12 year. Patients with Medical jaundice. The patient not fasting from 14 to 16 hours for MRCP procedure. The patient not fasting from 6 to 8 hours for ultrasound procedure and obese patients.

## 2. Results

Out of 50 patients suffering from obstructive jaundice. Our study clarifies that 30 of obstructive jaundice patients were male and 20 patients were females. The patient age group lies from 20 -40 years. All of patients includes in our study have RHC. There were 17 patients out of 50 in our study which ultrasound showed negative results that were positive on MRCP there were 28 patients that were positive on both ultrasound and MRCP. There were 3 patients that were positive on ultrasound but negative on MRCP and 2 patients that were negative on both modalities.

## 3. Discussion

Obstructive jaundice is a common surgical problem that occur when there is an obstruction to the passage of bile from liver cells to intestine. Our study evaluates by using MRCP and USG imaging technique. Out of 50 patients suffering from obstructive jaundice. Our study clarifies that 30 of obstructive jaundice patients were male and 20 patients were females. The patient age group lies from 20 -40 years. All of patients includes in our study have RHC. Our study suggested that 2 out of 20 females and 5 out of 30 males has obstructive jaundice due to anatomical variation. Moreover, 3 out of 20 females and no males has obstructive jaundice due to CBD dilatation. 2 female's patients out 20 and 3 males' patients out of 30 has obstructive jaundice due to cysts formation. 2 females' patient out of 20 and 3 males out of 30 has obstructive jaundice due to mass growth. 30 patients having biliary stones, where 13 were females and 19 were males. There were 17 patients out of 50 in our study which ultrasound showed negative results that were positive on MRCP there were 28 patients that were positive on both ultrasound and MRCP.

There were 3 patients that were positive on ultrasound but negative on MRCP and 2 patients that were negative on both modalities

P Sushmita Rao et al, in their study, "A comparative study of accuracy, and sensitivity, and specificity of MRCP and Ultrasound for diagnosis of hepatobiliary and pancreatic pathology" their study reveals the diagnostic efficacy of MRCP and Ultrasound. In their study obstructive jaundice was diagnosed in 52 patients. It was observed that most common type of lesion is benign i.e., 76.92%. There is total 13 patients of cholelithiasis. In this study, it was observed that majority i.e., 51.92% patients were males. it was observed that most common benign lesion account for 77.14%. Ultrasound was able to detect cholelithiasis account for 92.31%, but failed to detect distal CBD calculus. Where MRCP was able to diagnose Cholelithiasis, with choledocholithiasis cases correctly. Hence having a diagnostic accuracy of 100 % for cholelithiasis and choledocholithiasis. According to their study MRCP is very accurate in detecting the hepatobiliary pathology and MRCP is superior to the USG.<sup>[7]</sup> Amandeep Singh et al found that diagnostic accuracy and sensitivity of USG in diagnosing was 88% where as MRCP is able to detect 98% of benign and malignant pathology<sup>[8]</sup>. So we find out MRCP is more accurate then USG, correlating with other study.

## Conclusion:

Our study concluded that higher ratio of males then females in our sample size, RHC was positive in all the patients with dominant cause of jaundice was stone with in biliary channel. We found that MRCP has better efficiency comparative to ultrasound to detect jaundice and its etiology i.e., 90% true positive.

## References

1. Garg, S., et al., *Rare anatomic variations of the right hepatic biliary system*. Surg Radiol Anat, 2019. **41**(9): p. 1087-1092.
2. Vagholkar, K., *Obstructive Jaundice: Understanding the pathophysiology*. International Journal of Surgery and Medicine, 2020. **6**: p. 26-31.
3. Siddique, K., et al., *Evaluation of the aetiological spectrum of obstructive jaundice*. J Ayub Med Coll Abbottabad, 2008. **20**(4): p. 62-6.
4. Modha, K., *Clinical Approach to Patients With Obstructive Jaundice*. Tech Vasc Interv Radiol, 2015. **18**(4): p. 197-200.
5. Chen, L., et al., *Obstructive jaundice caused by ulcerative duodenal stenosis: A case report*. Niger J Clin Pract, 2020. **23**(4): p. 586-588.
6. Gabata, T., et al., *MR imaging of hepatocellular carcinomas with biliary tumor thrombi*. Abdom Imaging, 2007. **32**(4): p. 470-4.
7. Alcaraz, M.J., et al., *A comparative study of magnetic resonance cholangiography and direct cholangiography*. Rev Esp Enferm Dig, 2000. **92**(7): p. 427-38.
8. Singh, A., et al., *Diagnostic Accuracy of MRCP as Compared to Ultrasound/CT in Patients with Obstructive Jaundice*. J Clin Diagn Res, 2014. **8**(3): p. 103-7.

Table 1: Crosstabulation of MRCP and Ultrasound  
**MRCP \* Ultrasound Crosstabulation**

Count		Ultrasound		Total
		NEGATIVE	POSITIVE	
MRCP	NEGATIVE	2	3	5
	POSITIVE	17	28	45
Total		19	31	50

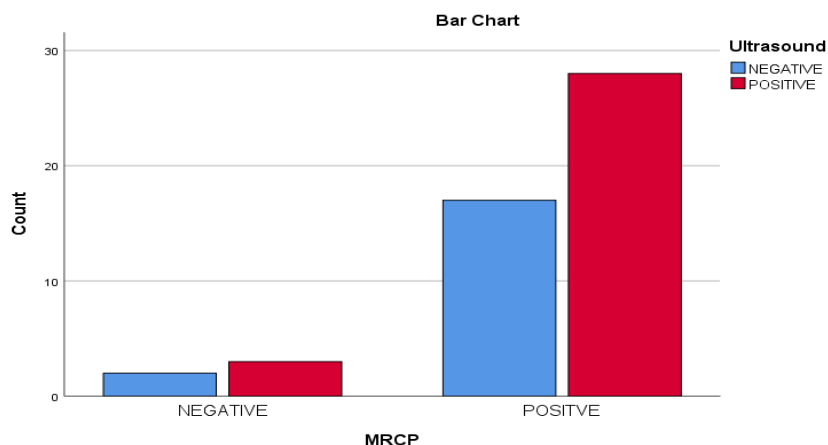


Figure 1: Shows there were 17 patients out of 50 in our study which ultrasound showed negative results that were positive on MRCP there were 28 patients that were positive on both ultrasound and MRCP. There were 3 patients that were positive on ultrasound but negative on MRCP and 2 patients that were negative on both modalities.