

Sonographic Evaluation of Causes of Right Hypochondriac Pain

Muhammad Nauman Saleem*

Bachelors in Medical Imaging Technology, Department of Allied Health Sciences, Superior College Lahore,
University Campus, 17-KM Raiwaind Road, Kot Arain, Lahore, Pakistan

Muqadas Abbas Chughtai

Bachelors in Medical Imaging Technology, Department of Allied Health Sciences, Superior College Lahore,
University Campus, 17-KM Raiwaind Road, Kot Arain, Lahore, Pakistan

Zobia Akram

Bachelors in Medical Imaging Technology, Department of Allied Health Sciences, Superior College Lahore,
University Campus, 17-KM Raiwaind Road, Kot Arain, Lahore, Pakistan

Fariha Riaz

Bachelors in Medical Imaging Technology, Department of Allied Health Sciences, Superior College Lahore,
University Campus, 17-KM Raiwaind Road, Kot Arain, Lahore, Pakistan

Hira Saeed

Bachelors in Medical Imaging Technology, Department of Allied Health Sciences, Superior College Lahore,
University Campus, 17-KM Raiwaind Road, Kot Arain, Lahore, Pakistan

Tayyaba Aslam

Masters in Medical Imaging Technology, Lecturer/Supervisor, Department of Allied Health Sciences, Superior
College Lahore, University Campus, 17-KM Raiwaind Road, Kot Arain, Lahore, Pakistan

Rana Muhammad Athar Azeem Shams

Masters in Medical Imaging Technology, Program Incharge, Department of Allied Health Sciences, Superior
College Lahore, University Campus, 17-KM Raiwaind Road, Kot Arain, Lahore, Pakistan

Adnan Ashraf

Bachelor in Medical Imaging Technology, Co-Supervisor/Technologist, Department of Radiology Chaudhary
Muhammad Akram Teaching and Research hospital, 17-KM Raiwaind Road, Kot Arain, Lahore, Pakistan

Rana Muhammad Bakhtawar Khan Sajawal

Masters in Mathematics, Lecturer/Biostatistician, Department of Allied Health Sciences, Superior College
Lahore, University Campus, 17-KM Raiwaind Road, Kot Arain, Lahore, Pakistan

The research is financed by Asian Development Bank. No. 2006-A171(Sponsoring information)

Abstract

Background: Right hypochondriac pain or right upper abdominal quadrant (RUQ) pain is the most common type of pain, reason of 7.9% patients presenting at the OPD and ET departments of hospitals. RUQ main has multiple recorded causes with different frequencies of presentation. Ultrasound is the essential imaging methodology of decision for introductory evaluation and fills in as a practical and dynamic methodology to give a conclusive finding. Various systems of organs are incorporated at standard RUQ US, and an assortment of ultrasonographically diagnosable infection cycles can be recognized, including states of hepatic, pancreatic, adrenal, renal, gastrointestinal, vascular, and thoracic, all of which may bring about RUQ torment and pain. Most common causes, however, incorporate acute hepatitis and issues with gall bladder such as cholelithiasis as reported in existing literature. The present study was thus conducted to evaluate the causes of right hypochondriac pain adopting ultrasound as the modality of choice. All the patients were scanned using SIMENS Grey scale/doppler ultrasound machine. Scanning was done in both transverse, longitudinal and any other plane deemed necessary to adequately visualize the right upper quadrant. Patients of either sex suffering from right hypochondrium pain were included in the study. They were referred from surgical OPD/ward of Chaudhary Muhammad Akram Teaching and Research Hospital. Duration of study was 4 months, during this period 154 patients were selected on the basis of age, gender and radiological findings, informed, verbal consent was taken and ultrasonographic reports were collected from radiologist office. It was found that out of 154 recorded cases, 93 were females and 61 males. Patients presented with a mixed frequencies of pain, highest being generalized abdominal pain. For the causes of RUQ pain, hepatic cyst was found to be the major cause present in

38.3% study participants followed by cholelithiasis (13.6%), hepatic hemangioma (10.4%), and right renal cyst (6.5%). Other findings included conditions like fatty liver (5.8%), gallbladder polyp (5.8%), right renal stones and hepatocellular carcinoma (3.9%). It was concluded that hepatic cysts and gall bladder stones are the major cause of RUQ pain in the present study sample. Although in some cases non-significant causes included hepatic calcification, focal nodular hyperplasia and lipomas are causes pain. As in our cases, US seems to be an important diagnostic modelity in both the diagnosis and follow-up of Right hypochondriac pain and it may provide a faster, easier method of diagnosis.

Keywords: Right Hypochondriac Region, Cholelithiasis, Acute Hepatitis, Ultrasound, Inflammation.

DOI: 10.7176/JHMN/91-06

Publication date: July 31st 2021

Introduction: Right hypochondriac region or the right upper abdominal quadrant (RUQ) is the expanse of abdomen that is situated immediately below the cartilages joining the sternum (breastbone) and the lower edges of ribs, including major organs of the body comprising prime part of liver, gall bladder, the biliary network, head of pancreas and the first part of small intestine⁽¹⁾. The liver occupies the upper part of the abdominal cavity just beneath the diaphragm. Gallbladder, underneath the right lobe of the liver, consists of the neck, body, and fundus and is in close proximity to other organs. Next, the head of pancreas is located in right upper quadrant, within the curvature of duodenum. Right upper quadrant abdominal pain, arising from the GIT tract or nearby organs, is the utmost recurrent and frequent cause of patients presenting in the hospital emergency and outpatient department, with studies calculating the incidence up to 7.9 percent of all the patient visits⁽²⁾. Even though, there are many recorded causes of hypochondriac pain, the most common causes on the right side accounts for diseases related to gall bladder, gastritis, hepatitis, urinary tract infections, pancreatitis and numerous such ailments⁽³⁾. Gallstone disease or cholelithiasis is amongst the most common reason of RUQ pain, with a worldwide prevalence of ten percent for the presence of disease in general population; nonetheless, most of the patients are initially asymptomatic (more than two percent) leading to delayed diagnosis and complications such as choledocholithiasis. Apart from gall bladder diseases, over two-third of patients with RUQ pain are found attributable to other causes.⁽⁴⁾ For this very reason, imaging studies are the best indicative tools for the diagnosis and linked confirmation of RUQ pain.

Ultrasonography is found to be the primary and emergent imaging modality of choice for the immediate assessment and diagnosis of RUQ pain, which does not provide a considerably wide range of differential possibilities⁽⁵⁾. The modality is reasonably priced and non-invasive where several disease entities involving a variety of organ systems, manifesting as RUQ pain can be reliably identified at initial levels, even when performed solely for evaluating gallbladder or biliary conditions⁽⁶⁾. As a part of standard RUQ ultrasound protocol, a steadfast assessment of liver, gall bladder, intra and extra hepatic channels and biliary ducts, pancreas and the right kidney are visualized at sagittal and transverse planes⁽⁷⁾. Moreover, additional or subsequent images at different planes and field of view are acquired depending on the patient's condition and for the sake of full RUQ assessment. While talking about the planes of US and organ being examined, a sub-costal and an inter-costal approach is adopted for real-time image of the liver, where conditions like abnormal liver parenchymal echogenicity such as fatty liver, acute hepatitis, hepatomegaly, nodularity and lesions, abnormalities of the ducts, hepatic abscess, and abnormalities of the intrahepatic vessels may be causing RUQ pain⁽⁸⁾.

For the US evaluation of gall bladder, supine or left lateral decubitus positions are incorporated in patients, acquiring detailed information of GB wall thickness, size, shape, presence or absence of gall stones and intra extra luminal abnormalities⁽⁹⁾. Sonographic confirmations of gallstones include, an echogenic focus, wall thickness >5 mm, sometimes with pericholecystic fluid¹⁰. Moreover, presence of Murphy Sign is vital when evaluating the GB, which is achieved by asking the patient to take in and hold a deep breath while palpating the right subcostal area. If pain occurs on inspiration, when the inflamed gallbladder encounters the examiner's hand, murphy sign is positive, which is known to be present in 94% of patients with cholelithiasis⁽¹⁰⁾. For the ultrasound evaluation of the pancreas, images are acquired in oblique transverse scanning plane and pancreatic shape, size, echogenicity along with appraisal of pancreatic ductal dilatation, parenchymal abnormalities (including mass lesions), and peri pancreatic collections or masses are evaluated.⁽¹¹⁾. In addition, assessment of patency of porto-splenic confluence and ailments of stomach and duodenum are also carried out while overlooking the pancreas⁽¹²⁾. Lastly, for the ultrasound of right kidney and adrenals, longitudinal scan plane at the mid-line of axilla is adopted to rule out renal causes for RUQ pain including obstructive, infectious, neoplastic, traumatic, and hemorrhagic conditions. Obstructive right nephron-ureterolithiasis, or stones, typically manifest as right abdominal flank pain, with hematuria at urinalysis and hydronephrosis at ultrasound images.

Individuals with gastric or duodenal inflammation may present with diffuse abdominal pain or isolated RUQ pain⁽¹³⁾. While, out of the diagnosis carried out, ultrasound is often underused in the diagnosis of gastro-intestinal conditions as its potential for detecting disease of the stomach and bowel is often underestimated owing to reduced self-reliance in sonographers, and concerns are identified for non-visualization due to bowel

gas or nonspecific nature of bowel wall thickening and rib shadowing artifact when visualized⁽¹⁴⁾. However, an inter-costal approach with large inspiration and breath hold maneuver by a patient can help in this context for a clearer visualization of thoraco-abdominal junction⁽¹⁵⁾

Furthermore, evaluation of the patient with acute RUQ pain requires a detailed considerate comprehension of the anatomy of that region as well as the physiology of proximal and remote organ systems⁽¹⁶⁾. Disorders of the organs in RUQ may cause symptoms like vague abdominal and flank pain radiating towards the back and the groin region, low-grade fever that may be caused due to an acute condition, vomiting and nausea because of the presence of gallstones and inflammation, problems with digestion in patients with conditions like fatty liver and frequent, painful urination. In numerous patients with hypochondriac pain, a cautious history and physical assessment is done to help and guide the workup in a suitable way. However, the manifestation of signs and symptoms of the numerous conditions causing RUQ pain, overlap exceedingly in different patients. For this reason, there is a huge number of diagnostic and indicative tests including computed tomography (CT), MRI, blood serum evaluations and laboratory tests. . However, CT and MRI are not the modalities of choice because of much time needed for diagnosis, expensive cost, exposure to radiation, and nephrotoxic contrast medium use. In this context, ultrasound is regarded the gold standard when looking for answers to these symptoms. According to studies, approximately seventy-five percent patients with RUQ pain opt for medical treatment and have confidence in ultrasonography as a safe and harmless modality, which can grant instant diagnostic solutions, straight forwarding the management processes⁽¹⁷⁾.

All these conditions are reported in previous literature frequent times, however, sonographic evaluation of patients with right hypochondriac pain as a combined topic of study is not actually found in preexisting writings. Moreover, the source location of the current research Pakistan is highly prevalent is conditions causing RUQ pain, where cholelithiasis is present in 4% males and 14.2% females, 10% of which are complicated to choledocholithiasis, a frequency of 14% approx. of non-alcoholic fatty liver disease is reported, and an overall incidence of 18% for kidney stone. Due to all these findings and high incidence of non-identified and misdiagnosed RUQ pain in patients, it is important to appraise ultrasound imaging with consideration given to appearances and presentations of these conditions. The current study thus aims to sonographically evaluate causes of right hypochondriac or right upper quadrant pain, along with the percentage and frequency analysis of recorded conditions in patients. The current investigation will contribute to literature extensively, especially in Pakistan where research on this topic is scarce and limited to a single type of condition causing right hypochondriac pain. Consequently, the study will assist in differentiation of causes of RUQ pain and provide information about progression of diseases.

1.1: Material and Method

Study design: Cross-sectional study.

Study area: Chaudhary Muhammad Akram Teaching and Research hospital

Duration of Study: The data was collected from November 15, 2020 to February 15, 2021.

Study subject: Patients having history of right hypochondrium pain and advised for ultrasonography for diagnosis.

Sample size: 154 patients with Right hypochondrial pain.

Sampling technique: Non-Probability Convenient Sampling Technique was used..

Sample collection:

- Inclusion criteria:
 - Patients (male and female) with right hypochondrial pain.
- Exclusion criteria:
 - Below 6 year
 - Ribs fracture
 - Uncooperative patients, mainly with severe tenderness and inflammation.
 - Patients with right hypochodric pain related to any other pathology which is not detectable on ultrasonography

Equipment: All the patients were scanned using SIMENS Grey scale/doppler ultrasound machine. Scanning was done in both transverse, longitudinal and any other plane deemed necessary to adequately visualize the right upper quadrant

Data collection: All patients of either sex suffering from right hypochondrium pain were included in the study. They were referred from surgical OPD/ward of Chaudhry Muhammad Akram Teaching and Research Hospital. During this period 154 patients were selected on the basis of age, gender and radiological findings, informed, verbal consent was taken and ultrasonographic reports were collected from radiologist office.

Data analysis: Data was tabulated and analyzed with the help of statistical package for the social sciences (SPSS) 25 and Microsoft excel (2016). Data was reported using cross sectional descriptive statistics.

ETHICAL CONSIDERATIONS

The rules and regulations set by the ethical committee of Superior College Lahore will be followed while conducting the research and the rights of the research participants will be respected.

Written informed consent (attached) will be taken from all the participants.

All information and data collection will be kept confidential.

Participants will remain anonymous throughout the study.

The subjects will be informed that there are no disadvantages or risks on the procedure of the study.

They will also be informed that they will be free to withdraw at any time during the process of the study. There will be none risks associated with this research.

We will do everything we can to protect your privacy. Your identity will not be revealed in any publication resulting from this study.

Your participation in this research study is voluntary. You may choose not to participate and you may withdraw your consent to participate any time. You will not be penalized in any way should you decide not you participate or to withdraw from this study.

DATA COLLECTION PROCEDURE

This is a cross sectional analytical study to evaluate the Sonographic causes of right hypochondric pain, correlating with its clinical manifestation. All patients will be informed about the nature, objective of the study, and written informed consent will be taken, and Institutional Ethics Committee approval will also be taken in advance. Patients with the clinical symptoms such as pain in right hypochondric region of body will be included in this study. All Sonographic examinations will be performed with a Simens Grey/Doppler scale machine. .

After taking inform written consent, data will be collected by the researcher with the help of data collection sheets.

Data will be collected according to variables of a questionnaire which are given as follows.

History/complaints/clinical diagnosis will be taken from participants.

Variables such as age, gender, and the scan will be asked from the individuals directly.

Result: In this cross-sectional analytical study through Convenient sampling technique, we have selected total 154 patients, the minimum age of the patients included in the study was about 13 and maximum age was around 76 with the common standard deviation to be around 16.06. Hepatic cyst was the highest, present in 38.3% patients followed by cholelithiasis (13.6%), hepatic hemangioma (10.4%), and right renal cyst (6.5%). Other recorded causes included fatty liver (5.8%), gallbladder polyp (5.8%), right renal stones (3.9), adenoma (3.9%), and hepatocellular carcinoma (3.9%). Other non-significant causes included hepatic calcification (1.9%), focal nodular hyperplasia and lipomas (1.3% respectively), and focal hepatic steatosis (0.6%).

Discussion: In the present study, the study sample consisted of 93 females and 61 male participants according to the results of data analysis of 154 patients in total, all presenting with mild, moderate or severe right hypochondriac pain and underwent sonographic evaluation, which as the imaging modality of choice. Out of the females, 30 had mild, 32 moderate and 31 had severe right upper quadrant pain, while in males this amount was 14, 27 and 20 for pain frequencies related to gender. The results here coincided with a study conducted by Basher in 2017 where most of the patients presented with mild and moderate pain accounting for 75%.³³ Moreover, types of pain, which are sensitivity to touch, sharp stabbing pain or general abdomen pain, were correlated with gender, where results indicated that both males and females mostly presented with general abdominal pain and stabbing or sharp main was the characteristics for more females than males. Other studies have recorded pain types by their locations as generalized right hypochondriac pain, non-specific generalized pain, unilateral loin pain and bilateral loin pain.²⁰ Due to the primary concern on the right hypochondriac region, the present study categorizes pain types as distinctive from other studies undertaken.

Coming to the causes of RUQ pain recorded on ultrasound, the present study attributed for a number of causes found where hepatic cyst was the highest, present in 38.3% patients followed by cholelithiasis (13.6%), hepatic hemangioma (10.4%), and right renal cyst (6.5%). Other recorded causes included fatty liver (5.8%), gallbladder polyp (5.8%), right renal stones (3.9), adenoma (3.9%), and hepatocellular carcinoma (3.9%). Other non-significant causes included hepatic calcification (1.9%), focal nodular hyperplasia and lipomas (1.3% respectively), and focal hepatic steatosis (0.6%). Unlike other studies found in literature, the present study recorded the highest existence of hepatic cyst to be the cause of RUQ pain. Coinciding with the present study results, Rungsinaporn and fellows in 2008 found that fatty liver was the most common positive finding, observed in 1,219 patients (35.9%). The second positive finding was of a liver mass present in 6.2% patients; of which 59.3% had hepatic cysts, 24.4% hemangioma, 7.7% undetermined nodule, 5.3% calcification, and 3.4% patients had malignant tumor. In the same study cholelithiasis, GB polyp, renal cyst and stone were amongst other primary causerie findings.¹⁸

In a study conducted by Elnair in 2016, the authors conducted a similar analysis and it was found that the pain caused in the right upper quadrant was mostly due gall bladder disease, where 52.9% was the frequency of

gall bladder stones, and 29.4% with acute cholecystitis. In the same study, examination of liver found that 15.7% caused by liver disease, out of which 0.45% was the frequency of fatty liver conditions, 0.09% liver cyst, 0.08% abscess, 0.09% cancer and 0.08% hepatitis. In case of renal stones, 58.6% was the frequency and 24.1% for hydronephrosis³⁵. Similarly, in another study consequently cholelithiasis was present in 42% of the study population and was the leading cause of RUQ pain³¹. Conversely, Abtehag and Azza have found nonalcoholic fatty liver disease and cholelithiasis amongst the leading causes of RUQ pain.²⁰

Conclusion

In study conclusion, the causes of right hypocondriac pain is significant entity in endemic areas, and this may present as cholelithiasis, hepatic hemangioma, and right renal cyst. Although in some cases non-significant causes included hepatic calcification, focal nodular hyperplasia and lipomas are causes pain. As in our cases, US seems to be an important diagnostic modelity in both the diagnosis and follow-up of Right hypocondriac pain and it may provide a faster, easier method of diagnosis. Management of the patient can be done on the patients presenting with symptoms of acute right upper quadrant pain.

Knowledge of strengths and obstacles or limitations of ultrasound withinside the assessment of RUQ is paramount in accurate diagnosis. A spectrum of RUQ pathology for which a RUQ ultrasound exam must moderately be taken into consideration because the preliminary imaging modality of preference could be reviewed.

References

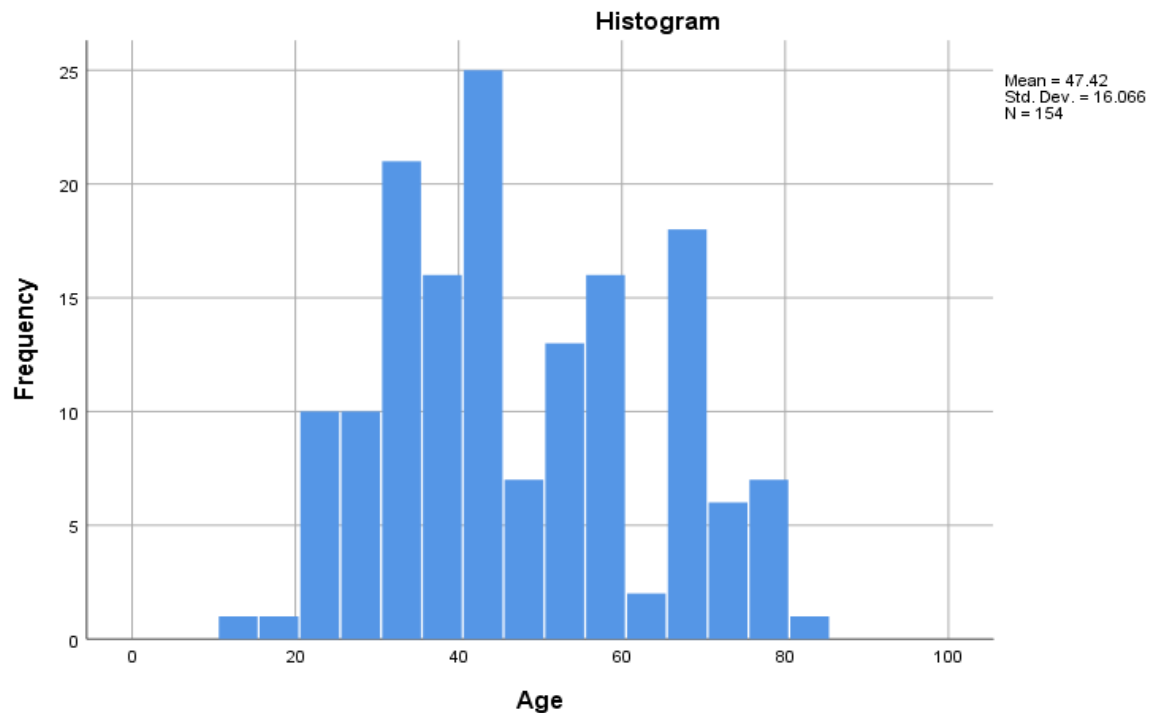
1. Joshi G, Crawford KA, Hanna TN, Herr KD, Dahiya N, Menias CO. US of Right Upper Quadrant Pain in the Emergency Department: Diagnosing beyond Gallbladder and Biliary Disease. *RadioGraphics*. 2018;38(3):766-93.
2. Revzin MV, Scoutt LM, Garner JG, Moore CL. Right Upper Quadrant Pain: Ultrasound First! *Journal of Ultrasound in Medicine*. 2017;36(10):1975-85.
3. H Alkhuzae A. SONOGRAPHIC EVALUATION OF RIGHT UPPER QUADRANT ABDOMINAL PAIN. *Basrah Journal of Surgery*. 2014;20(1):66-9.
4. Koteish A, Kalloo AN. Chronic or recurrent abdominal pain. *Textbook of Clinical Gastroenterology and Hepatology*. 2012:16.
5. Spence SC, Teichgraber D, Chandrasekhar C. Emergent Right Upper Quadrant Sonography. *Journal of Ultrasound in Medicine*. 2009;28(4):479-96.
6. Yarmish GM, Smith MP, Rosen MP, Baker ME, Blake MA, Cash BD, et al. ACR Appropriateness Criteria Right Upper Quadrant Pain. *Journal of the American College of Radiology*. 2014;11(3):316-22.
7. Stoker J, Randen Av, Laméris W, Boermeester MA. Imaging Patients with Acute Abdominal Pain. *Radiology*. 2009;253(1):31-46.
8. Chawla A, Bosco JI, Lim TC, Srinivasan S, Teh HS, Shenoy JN. Imaging of acute cholecystitis and cholecystitis-associated complications in the emergency setting. *Singapore Med J*. 2015;56(8):438-44.
9. Marasco G, Verardi FM, Eusebi LH, Guarino S, Romiti A, Vestito A, et al. Diagnostic imaging for acute abdominal pain in an Emergency Department in Italy. *Internal and Emergency Medicine*. 2019;14(7):1147-53.
10. Stoker J, van Randen A, Laméris W, Boermeester MA. Imaging patients with acute abdominal pain. *Radiology*. 2009;253(1):31-46.
11. Stark A, Donahue TR, Reber HA, Hines OJ. Pancreatic cyst disease: a review. *Jama*. 2016;315(17):1882-93.
12. Finstad TA, Tchelepi H, Ralls PW. Sonography of acute pancreatitis: prevalence of findings and pictorial essay. *Ultrasound quarterly*. 2005;21(2):95-104.
13. Avegno J, Carlisle M. Evaluating the Patient with Right Upper Quadrant Abdominal Pain. *Emergency Medicine Clinics of North America*. 2016;34(2):211-28.
14. Mendelson R. Imaging for chronic abdominal pain in adults. *Aust Prescr*. 2015;38(2):49-54.
15. Molinari F, Bankier AA, Eisenberg RL. Fat-containing lesions in adult thoracic imaging. *American Journal of Roentgenology*. 2011;197(5):W795-W813.
16. Tchelepi H, Ralls PW, Radin R, Grant E. Sonography of Diffuse Liver Disease. *Journal of Ultrasound in Medicine*. 2002;21(9):1023-32.
17. Alam A, Amanullah F, Baig-Ansari N, Lotia-Farrukh I, Khan FS. Prevalence and risk factors of kidney disease in urban Karachi: baseline findings from a community cohort study. *BMC Research Notes*. 2014;7(1):179.

RESULTS

In this cross-sectional analytical study through Convenient sampling technique, we have selected total 154 patients, the minimum age of the patients included in the study was about 13 and maximum age was around 76

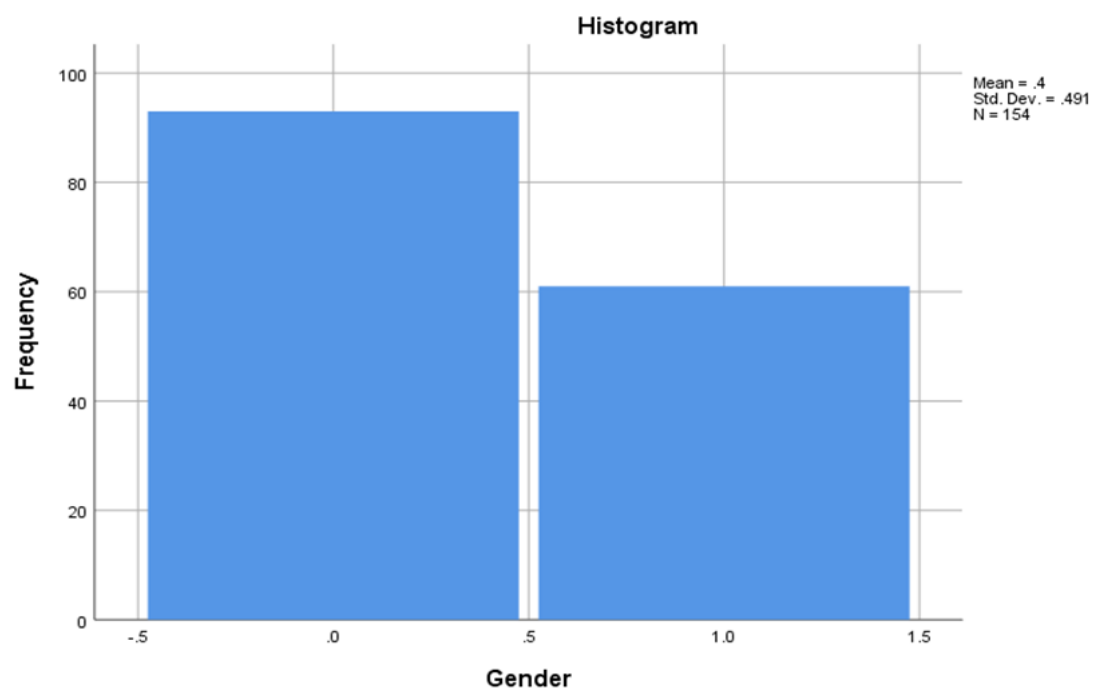
with the common standard deviation to be around 16.06. Hepatic cyst was the highest, present in 38.3% patients followed by cholelithiasis (13.6%), hepatic hemangioma (10.4%), and right renal cyst (6.5%). Other recorded causes included fatty liver (5.8%), gallbladder polyp (5.8%), right renal stones (3.9), adenoma (3.9%), and hepatocellular carcinoma (3.9%). Other non-significant causes included hepatic calcification (1.9%), focal nodular hyperplasia and lipomas (1.3% respectively), and focal hepatic steatosis (0.6%).

Age frequency bar chart



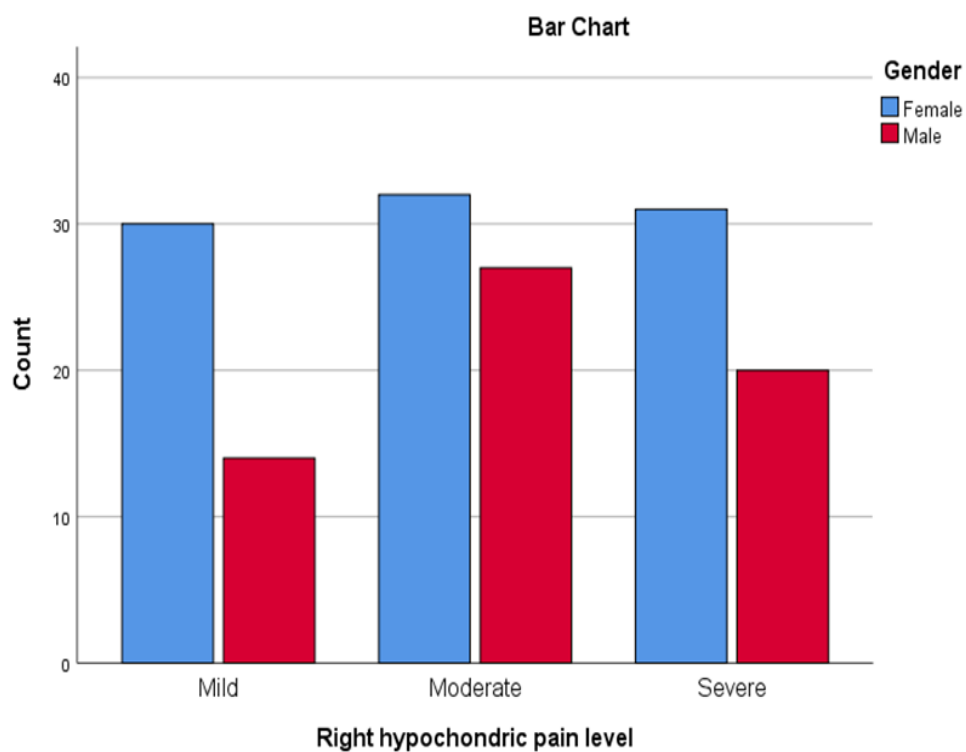
Gender

		Gender			
		Frequency	Percent	Valid Percent	Cumulative Percent
Valid	Female	93	60.4	60.4	60.4
	Male	61	39.6	39.6	100.0
	Total	154	100.0	100.0	



Right hypochondric pain level * Gender Crosstabulation

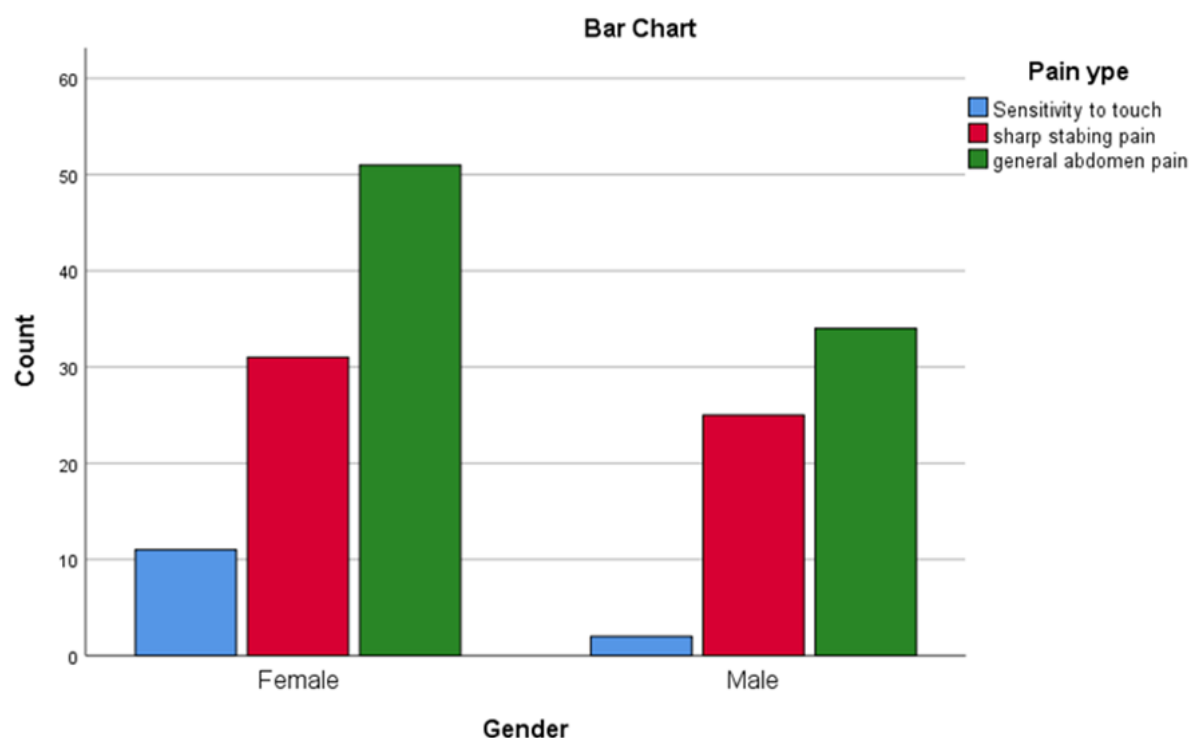
		Gender		
		Female	Male	Total
Right hypochondric pain level	Mild	30	14	44
	Moderate	32	27	59
	Severe	31	20	51
Total		93	61	154



Gender * Pain type

Crosstab

			Paint types			Total
			Sensitivity to touch	sharp stabbing pain	general abdomen pain	
Gender	Female	Count	11	31	51	93
		Expected Count	7.9	33.8	51.3	93.0
	Male	Count	2	25	34	61
		Expected Count	5.1	22.2	33.7	61.0
Total	Count		13	56	85	154
	Expected Count		13.0	56.0	85.0	154.0



Pathology related with RHQ pain

		Frequency	Percent	Valid Percent	Cumulative Percent
Valid	Gallbladder polyp	9	5.8	5.8	5.8
	Cholilithesis	21	13.6	13.6	19.5
	Hepatic cyst	59	38.3	38.3	57.8
	Right Renal cyst	10	6.5	6.5	64.3
	Right renal stone	6	3.9	3.9	68.2
	Adenoma	6	3.9	3.9	72.1
	Focal nodular hyperplasia	2	1.3	1.3	73.4
	Hepatic Hemangioma	16	10.4	10.4	83.8
	Myeloid	2	1.3	1.3	85.1
	Multiple biliary hamartomas	2	1.3	1.3	86.4
	Fatty liver	9	5.8	5.8	92.2
	Lipoma	2	1.3	1.3	93.5
	Hepatic calcification	3	1.9	1.9	95.5
	Focal hepatic steatosis	1	.6	.6	96.1
	Metastasis (Hepatocellular carcinoma)	6	3.9	3.9	100.0
	Total	154	100.0	100.0	