



# Rupture of a Mature Cystic Teratoma in a Young Girl Caused by a Car Accident: an Extremely Rare Case and Review of the Literature

Dimitrios Tsapralis<sup>1</sup>, Anastasia Prodromidou<sup>2</sup>, Georgios Vasiliadis<sup>1</sup>, Chrysovalantis Vergadis<sup>3</sup>, Nikolaos Machairas<sup>2</sup>, Athanasios Syllaios<sup>2</sup>, Evangelos Misiakos<sup>4</sup>, Dimitrios Schizas<sup>2</sup>

<sup>1</sup> Department of Surgery, General Hospital of Ierapetra, Ierapetra, Greece

<sup>2</sup> First Department of Surgery, National and Kapodistrian University of Athens, Laiko General Hospital, Athens, Greece

<sup>3</sup> Radiology Department, Laiko General Hospital, Athens, Greece

<sup>4</sup> Third Department of Surgery, National and Kapodistrian University of Athens, Attikon University Hospital, Athens, Greece

**Corresponding author:** Anastasia Prodromidou, First Department of Surgery, National and Kapodistrian University of Athens, Laiko General Hospital, Athens, Greece; E-mail: a.prodromidou@hotmail.com; Tel.: +30697275100

**Received:** 12 June 2020 ♦ **Accepted:** 8 Dec 2020 ♦ **Published:** 30 June 2021

**Citation:** Tsapralis D, Prodromidou A, Vasiliadis G, Vergadis C, Machairas N, Syllaios A, Misiakos E, Schizas D. Rupture of a mature cystic teratoma in a young girl caused by a car accident: an extremely rare case and review of the literature. *Folia Med (Plovdiv)* 2021;63(3):438-42. doi: 10.3897/folmed.63.e55388.

## Abstract

Mature cystic teratomas (MCT) of the ovary or dermoid cysts are commonly encountered benign ovarian lesions accounting for approximately 70% of benign tumors and originating from germ cells. A rare case of peritonitis in a 17-year-old female patient caused by traumatic rupture of an MCT of the right ovary is herein presented. A meticulous search of the literature has also been performed. Due to deterioration of patient's clinical condition, she was urgently led to surgery and intraoperative investigation of the peritoneal cavity revealed an inflamed ruptured ovarian cyst along with extensive peritoneal adhesions and purulent peritoneal fluid. A cyst resection was performed with preservation of the ovary followed by adhesiolysis and meticulous abdominal washing and the patient had an uneventful recovery.

Despite its rarity, traumatic rupture of ovarian cyst should be considered at evaluation of trauma patients with special attention to cases with a discovered or known presence of ovarian cyst.

## Keywords

blunt trauma, dermoid cyst, mature cystic teratoma, peritonitis, traumatic rupture

## INTRODUCTION

Mature cystic teratomas (MCT) of the ovary or dermoid cysts are commonly encountered benign ovarian lesions which originate from germ cells.<sup>1</sup> Their prevalence ranges from 10% to 15% among women with ovarian tumors while they account for approximately 70% of benign tumors in women

of reproductive age.<sup>1,2</sup> MCTs remain generally asymptomatic and are incidentally diagnosed during routine ultrasonographic gynecological examination. On the other hand, in the case of MCTs causing symptoms, they are either chronic related to obstruction of the surrounding organs or acute related to torsion, rupture or infection.<sup>3</sup> We herein present a rare case of peritonitis in a 17-year-old patient caused by traumatic rupture of a MCT of the right ovary.

## CASE REPORT

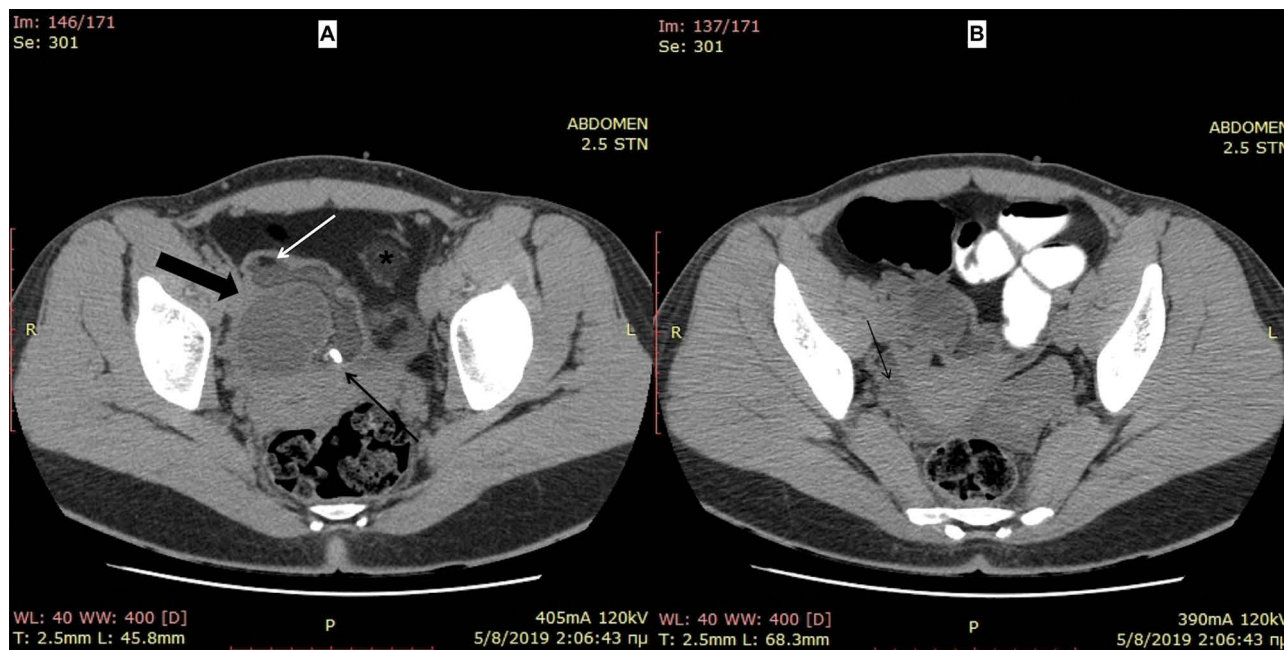
A 17-year-old female patient was transferred to the emergency department (ED) after being involved in a car accident. The patient was stable with blood pressure of 110/75 mmHg, 78 beats per minute and oxygen saturation of 98%. She complained of mild epigastric pain. On physical examination, diffuse peritoneal irritation on abdominal palpation was recognized. Patient's hemoglobin was 12 g/dl. Upon further investigation, ultrasonography showed a cystic lesion of the right ovary. Computer tomography (CT) excluded presence of free air or fluid in the peritoneal cavity or signs indicative of visceral injury, but it confirmed the presence of an approximately 5-cm cystic lesion in the right ovary with features rendering it suspicious for teratoma (Fig. 1). The patient was admitted to the clinic and despite amelioration of her clinical condition with remission of the abdominal pain, she spiked temperatures of up to 38°C. She was administered broad-spectrum i.v. antibiotics and was discharged 4 days later in good clinical condition while her blood values were all within normal limit.

Ten days later she was at the ED complaining of vague abdominal pain and persistent fever accompanied with rigors. She was febrile, tachycardic and tachypneic with diffuse abdominal tenderness mainly localized in hypogastrium and right lower quadrant. No signs of peritoneal irritation were present. Her laboratory examination revealed leukocytosis (WBC count of 12.453/mm<sup>3</sup>) with elevated levels of C-reactive protein of 25 mg/dl. She was submitted to another CT scan with oral and i.v. contrast, which demonstrated

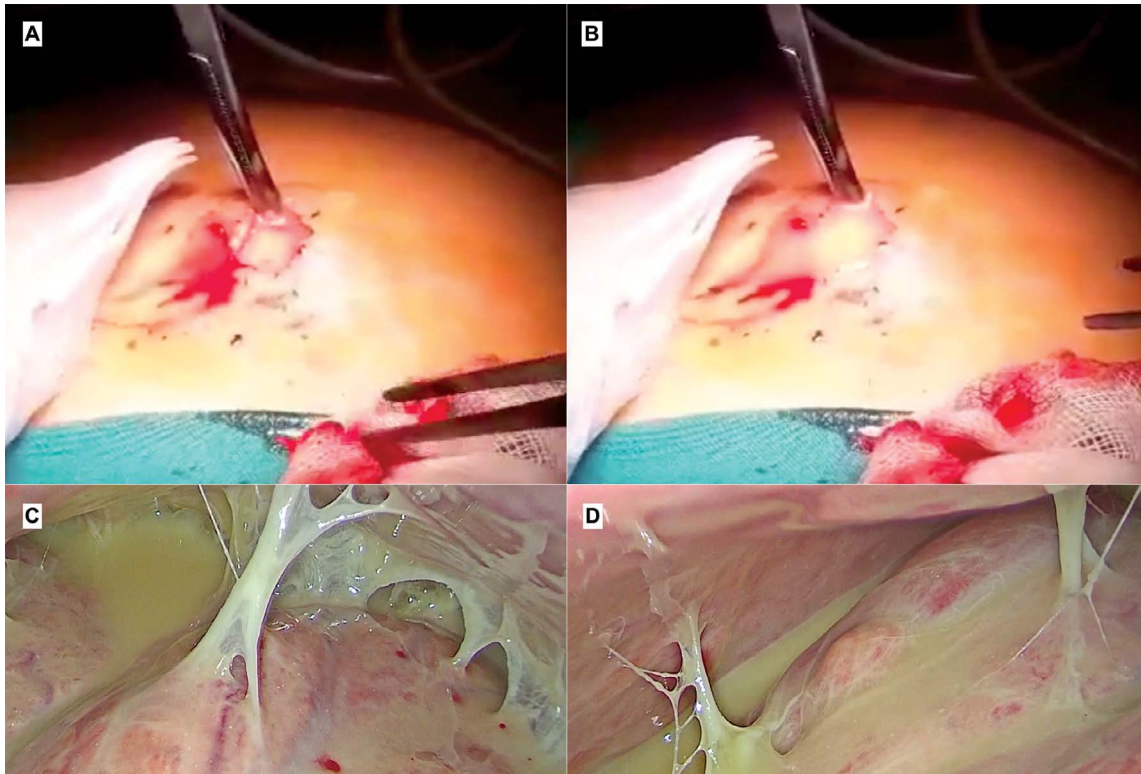
again the right cystic ovarian lesion. Due to her deteriorating condition, an exploratory laparoscopy was performed the following 2 days of conservative treatment with i.v. antibiotics, fluids and analgesics. Upon establishment of pneumoperitoneum with Hasson technique through the umbilicus, pus poured out of the abdomen (Figs 2A, 2B). Upon insertion of the laparoscope into the peritoneal cavity, a significant amount of pus and extensive adhesions between bowel loops, were recognized (Figs 2C, 2D). Due to limited visualization and poor exposure with laparoscopy, the procedure was converted to laparotomy via a Pfannenstiel incision. The peritoneal cavity was thoroughly investigated and a ruptured cyst of the right ovary was recognized (Fig. 3). Cyst resection was performed with preservation of the ovary followed by adhesiolysis and meticulous abdominal washing with at least 10 litres of warm saline solution. Postoperatively, the patient remained afebrile, had an uneventful postoperative course and was discharged on the third postoperative day. Histology of the excised cystic lesion revealed presence of MCT containing teeth, hair and bone tissue components. Six months postoperatively, the patient is in a good condition without any complications.

## DISCUSSION

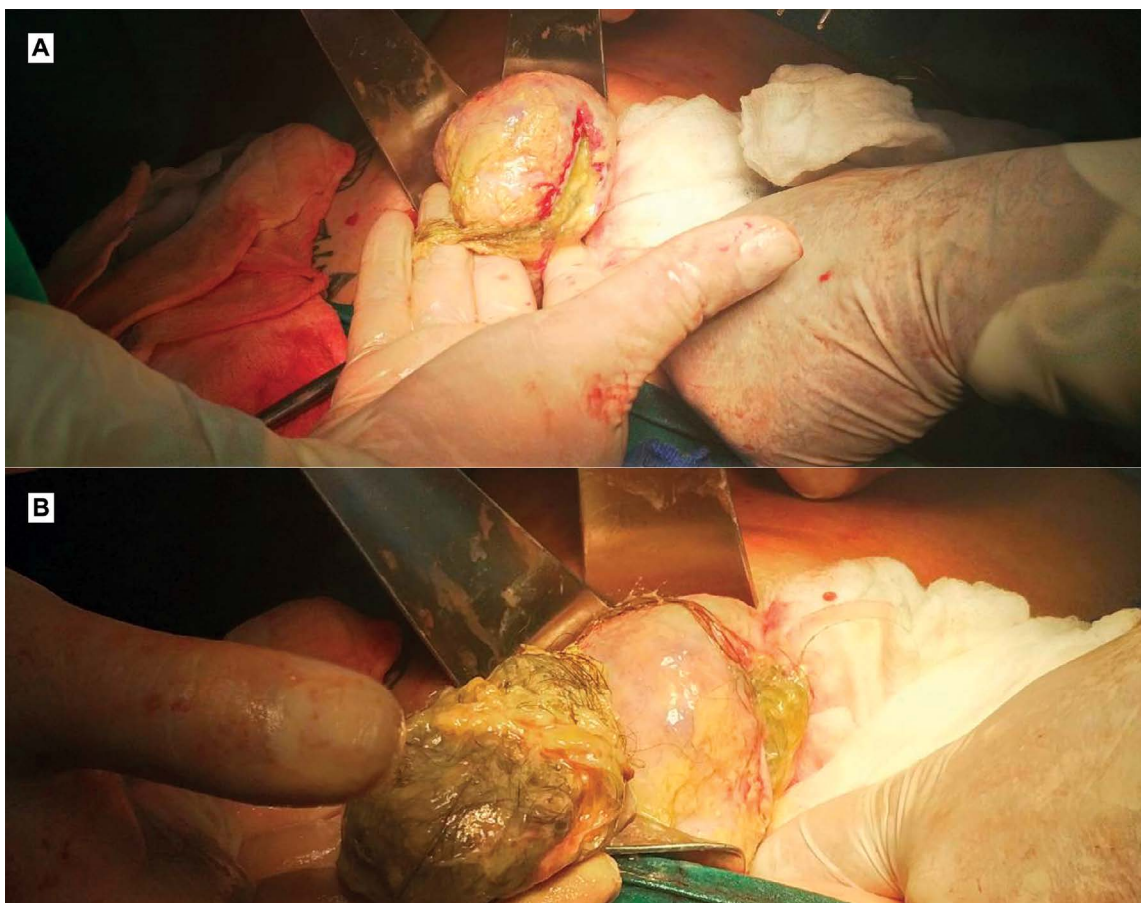The present case represents an uncommon complication of peritonitis due to traumatic rupture of an MCT in a young girl caused by a car accident. This is to our knowledge the third case in the literature reporting similar trau-



**Figure 1.** Axial abdominal CT images depicts: A) Large complex cyst (black bold arrow) occupying the right parametrium. It contains fat (white arrow) and fluid (yellow) densities and dentiform calcification (black arrow). An oval shaped fat density structure (asterisk) lying to the adjacent mesentery probably corresponds to fatty fluid infiltration; B) Presence of small amount of fluid in the pouch of Douglas (black arrow).



**Figure 2.** Intraoperative image during laparoscopy: A and B) Pus poured out of the abdomen at insertion to the abdomen through Hasson technique; C and D) Recognition of pus and extensive adhesions between bowel loops at insertion of the laparoscope.



**Figure 3.** Intraoperative image during laparotomy: a ruptured cyst of the right ovary containing hair.



matic rupture of MCT after blunt abdominal trauma. More specifically, Levine et al. reported a case of a 26 year-old woman with a ruptured dermoid cyst following motor vehicle accident.<sup>4</sup> The patient was initially reported to have a small rupture due to the vehicle deceleration which gradually evolved to acute abdomen with an increase in patient's abdominal pressure when she went to the toilet.<sup>4</sup> Another case of MCT rupture secondary to a car accident was presented by Kimbrell et al.<sup>5</sup> The aforementioned patient was an 18 year old female which presented with acute abdomen following a blunt trauma and underwent an exploratory laparotomy that revealed about 1.3 L of fluid in the abdominal cavity due to rupture of an MCT of about 15 cm in diameter.<sup>5</sup>

The internal organs of the female reproductive system are theoretically protected against blunt trauma by the presence of pelvic bones and the surrounding muscles. In that setting, a retrospective review of 220 blunt traumas from a single institution showed an incidence of approximately 7% of gynecologic injuries among them.<sup>6</sup> The majority of the 15 patients who were diagnosed with gynecological injury had hemorrhage secondary to a potential rupture of corpus luteum.<sup>4,6</sup>

A sudden rupture of an MCT caused by trauma, torsion or delivery usually leads to acute peritonitis with significantly pronounced symptoms related to potential hemodynamic instability due to shock or massive bleeding.<sup>7</sup> Despite the fact that our patient initially presented with symptoms of peritoneal irritation after a blunt abdominal trauma (car accident) potentially responsible for the rupture of the pre-existing undiagnosed ovarian cystic lesion, she remained hemodynamically stable. Consequently, the non-specific radiological findings along with the significant improvement in patients' clinical course did not indicate an emergent surgical management of the patient. Nonetheless, deterioration of patient's clinical condition when readmitted led us to the operation theatre despite the absence of imaging signs. Rupture of a teratoma can be directly recognized as a discontinuity of the cystic wall at US, MR or CT or indirectly by the presence of free intraperitoneal fluid and concomitant reduction of the liquid component and the round shape of the lesion.<sup>8</sup> Furthermore, omental involvement and peritoneal inflammatory implants can be depicted in cases of chronic granulomatous peritonitis.<sup>8</sup> Those findings can be misunderstood as carcinomatous or tuberculous.<sup>9</sup> In our patient, none of the aforementioned radiological findings were reported but the intraoperative investigation of the peritoneal cavity revealed an inflamed ruptured ovarian cyst along with extensive peritoneal

adhesions and purulent peritoneal fluid. Despite its rarity, traumatic rupture of ovarian cyst should be considered when evaluating trauma patients with discovered or known history of ovarian cyst.

## Acknowledgements

The authors have no support to report.

## Competing interests

The authors have declared that no competing interests exist.

## Funding

The authors have no funding to report.

## REFERENCES

1. Wang WC, Lai YC. Evidence of metachronous development of ovarian teratomas: a case report of bilateral mature cystic teratomas of the ovaries and systematic literature review. *J Ovarian Res* 2017; 10:17.
2. Sinha A, Ewies AA. Ovarian mature cystic teratoma: challenges of surgical management. *Obstet Gynecol Int* 2016; 2016:2390178.
3. Khanna S, Srivastava V, Saroj S, et al. An unusual presentation of ovarian teratoma: a case report. *Case Rep Emerg Med* 2012; 2012:845198.
4. Levine RL, Pepe PE, Blackstone W, et al. Occult traumatic avulsion of an ovarian dermoid cyst. *Am J Emerg Med* 1992; 10:344–6.
5. Kimbrell BJ, Emami C, Petrone P, et al. Ruptured ovarian cystic teratoma secondary to blunt abdominal trauma: a very unusual case. *J Trauma* 2007; 63:E27–9.
6. Stone NN, Ances IG, Brotman S. Gynecologic injury in the nongravid female during blunt abdominal trauma. *J Trauma* 1984; 24:626–7.
7. Tejima K, Enomoto R, Arano T, et al. A case of chemical peritonitis and pleuritis caused by spontaneous rupture of a benign cystic ovarian teratoma that improved without surgical intervention. *Clin J Gastroenterol* 2013; 6:274–80.
8. Park SB, Kim JK, Kim KR, et al. Imaging findings of complications and unusual manifestations of ovarian teratomas. *Radiographics* 2008; 28:969–83.
9. Srisajjakul S, Prapaisilp P, Bangchokdee S. Imaging features of unusual lesions and complications associated with ovarian mature cystic teratoma. *Clin Imaging* 2019; 57:115–23.

# Разрыв зрелой кистозной тератомы у молодой девушки в результате автомобильной аварии: чрезвычайно редкий случай и обзор литературы

Димитриос Тсапралис<sup>1</sup>, Анастасия Продромиду<sup>2</sup>, Георгиос Василиадис<sup>1</sup>, Крисовалантис Вергадис<sup>3</sup>, Николаос Макаирас<sup>2</sup>, Атанасиос Силайос<sup>2</sup>, Евангелос Мисиакос<sup>4</sup>, Димитриос Скизас<sup>2</sup>

<sup>1</sup> Отделение хирургии, Многопрофильная больница Иерапетры, Иерапетра, Греция

<sup>2</sup> Первое хирургическое отделение, Национальный университет им. Каподистрии – Афины, Многопрофильная больница „Лайко“, Афины, Греция

<sup>3</sup> Отделение радиологии, Многопрофильная больница „Лайко“, Афины, Греция

<sup>4</sup> Третье хирургическое отделение, Национальный университет им. Каподистрии – Афины, Многопрофильная больница „Атикон“, Афины, Греция

**Адрес для корреспонденции:** Анастасия Продромиду, Первое хирургическое отделение, Национальный университет им. Каподистрии – Афины, Многопрофильная больница „Лайко“, Афины, Греция; E-mail: a.prodromidou@hotmail.com; Тел.: +30697275100

---

**Дата получения:** 12 июня 2020 ♦ **Дата приемки:** 8 декабря 2020 ♦ **Дата публикации:** 30 июня 2021

---

**Образец цитирования:** Tsapralis D, Prodromidou A, Vasiliadis G, Vergadis C, Machairas N, Syllaios A, Misiakos E, Schizas D. Rupture of a mature cystic teratoma in a young girl caused by a car accident: an extremely rare case and review of the literature. Folia Med (Plovdiv) 2021;63(3):438-42. doi: 10.3897/folmed.63.e55388.

---

## Резюме

Зрелые кистозные тератомы (ЗКТ) яичников или дермоидные кисты являются распространёнными доброкачественными поражениями яичников, составляющими примерно 70% доброкачественных опухолей и возникающими из половых клеток (гамет). Здесь представлен редкий случай перитонита у 17-летней пациентки, вызванного травматическим разрывом ЗКТ правого яичника. Также было проведено детальное изучение литературы. В связи с ухудшением клинического состояния пациентки она была доставлена экстренно в хирургическое отделение, при интраоперационном обследовании брюшной полости выявлена воспаленная разорванная киста яичника с обширными спайками брюшины и гнойной перитонеальной жидкостью. Киста была резецирована с сохранением яичника с последующим гемиолизом и тщательным абдоминальным лаважем, после чего пациентка выздоровела.

Несмотря на редкие случаи, травматический разрыв кисты яичника следует учитывать при оценке травматических пациентов, и особое внимание следует уделять случаям с известным наличием кисты яичника.

---

## Ключевые слова

травма тупым предметом, дермоидная киста, зрелая кистозная тератома, перитонит, травматический разрыв

---