



THE AGA KHAN UNIVERSITY

eCommons@AKU

Department of Pathology and Laboratory Medicine

Medical College, Pakistan

October 1995

# Primary Amyloidosis of Gut presenting with Dysphagia

Zaigham Abbas  
*Baqai University Hospital*

Shahab Abid  
*Baqai University Hospital*

Naim -ur- Rehman  
*Aga Khan University*

Shahid Pervez  
*Aga Khan University, [shahid.pervez@aku.edu](mailto:shahid.pervez@aku.edu)*

Follow this and additional works at: [http://ecommons.aku.edu/pakistan\\_fhs\\_mc\\_pathol\\_microbiol](http://ecommons.aku.edu/pakistan_fhs_mc_pathol_microbiol)

 Part of the [Oncology Commons](#), and the [Pathology Commons](#)

## Recommended Citation

Abbas, Z., Abid, S., Rehman, N. -, Pervez, S. (1995). Primary Amyloidosis of Gut presenting with Dysphagia. *Journal of Pakistan Medical Association*, 45(10), 274-275.

**Available at:** [http://ecommons.aku.edu/pakistan\\_fhs\\_mc\\_pathol\\_microbiol/310](http://ecommons.aku.edu/pakistan_fhs_mc_pathol_microbiol/310)

# Primary Amyloidosis of Gut Presenting with Dysphagia

Pages with reference to book, From 274 To 275

Zaigham Abbas, Shahab Abid ( Dept. of Medicine, Baqai University Hospital, Karachi. )

Naim-ur-Rehman ( Dept. of Medicine, Aga Khan University Hospital, Karachi. )

Shahid Pervez ( Dept. of Pathology, Aga Khan University Hospital, Karachi. )

## Introduction

The gut may be involved in the primary (AL) amyloidosis<sup>1</sup>. It is associated with dysmotility and malabsorption<sup>2</sup>. Endoscopic examination of these cases reveals fine granular appearance of mucosa, polypoid protrusions, erosions, ulcerations and mucosal friability<sup>3</sup>. We present here a case of primary amyloidosis of gut who presented with dysphagia.

## Case report

A sixty-five year old lady presented with increasing dysphagia for both solids and liquids. Her initial symptom was feeling of food sticking in the retrosternal region followed by vomiting of food, anorexia and constipation. She became dependent on laxatives to move her bowels on alternate days. She lost about 10 Kg of body weight and became completely bedridden. There was a past history of breast carcinoma operated one year back, which was stage I disease. Post-operatively radiotherapy was administered and presently tamoxifen was in use. On examination, the patient was afebrile, looked pale and had bilateral xanthelasma. Pulse rate was 80 per minute and blood pressure 90/60 mmHg in supine position and there was mild pedal edema. Systemic examination revealed no abnormality. Haemoglobin was 9.4 g/dl with normochromic normocytic picture, total leucocyte count 10400/uf, ESR 8 mm 1st hr., serum creatinine 1.2 mg/dl and serum sodium 128 mmol/l. Transaminases were normal. Albumin was 2.0 g/dl and globulins 1.7 g/dl. Protein electrophoresis showed an increase in alpha one fraction with a decrease in beta and gamma fractions of globulin. She was mildly hypothyroid with a TSH of 8.29 uU/ml (0.3-5.0) and T4 of 4.0 ug/dl (4.5-12.0). Urine DR and Chest X-rays were normal. Barium studies could not be done as patient was bedridden. Upper gastrointestinal endoscopy was performed. There was paucity of primary peristaltic waves in oesophagus. A ring of contraction was seen in the distal oesophagus 3 cm above the Z line. The 'ring' relaxed intermittently for brief periods. Lower oesophageal sphincter was gaping. The oesophageal mucosa was erythematous with fine granularity and erosions near the Z line. The gastric lake was full of greenish biliary fluid. Pylorus was wide open and gastric and duodenal mucosa were erythematous. Biopsies were taken from oesophagus, stomach and duodenum. Later rectal biopsy was also taken. Histopathology report revealed homogenous thickening of blood vessel walls in all the specimens with areas exhibiting nodules of eosinophilic homogenous material in the lamina propria. Congo red staining with green birefringence on polarisation confirmed the amyloid deposits in these areas and vessel walls (Figures 1 and 2).

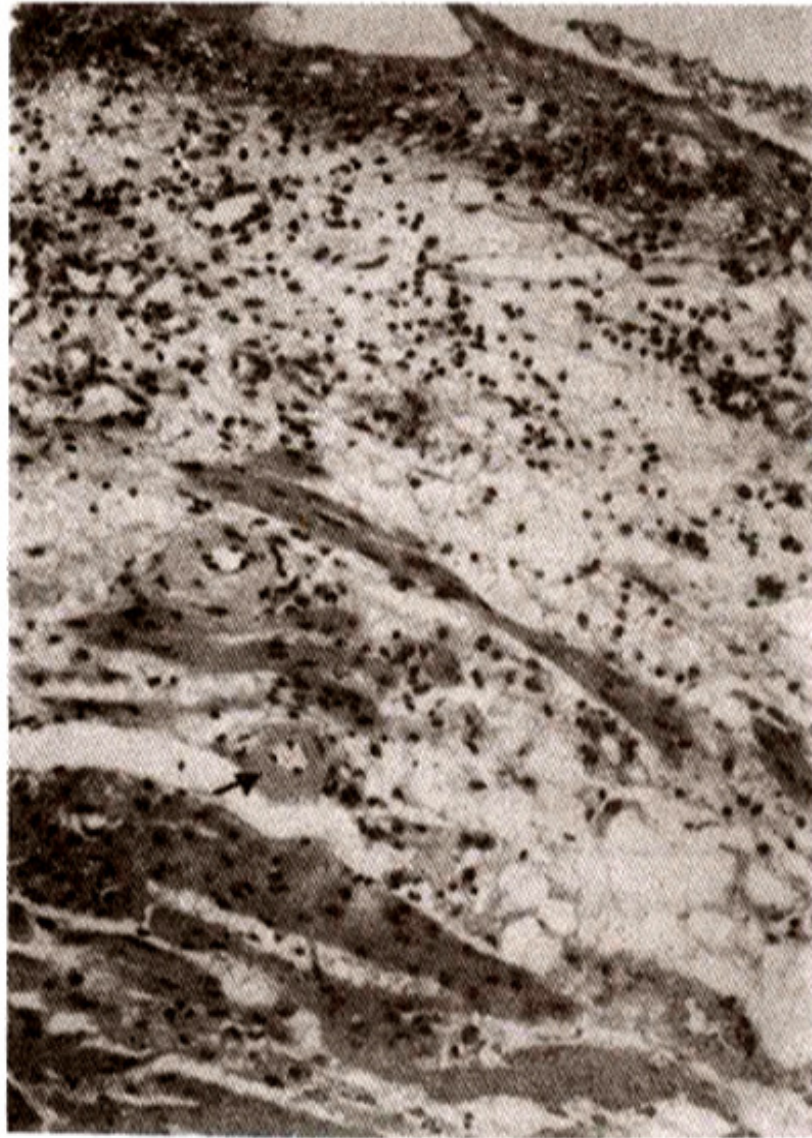

Figure 1. Section of the oesophageal biopsy with overlying mucosa. Submucosal vessels show deposition of an acellular homogenous amyloid material (arrow). H & E 10X.

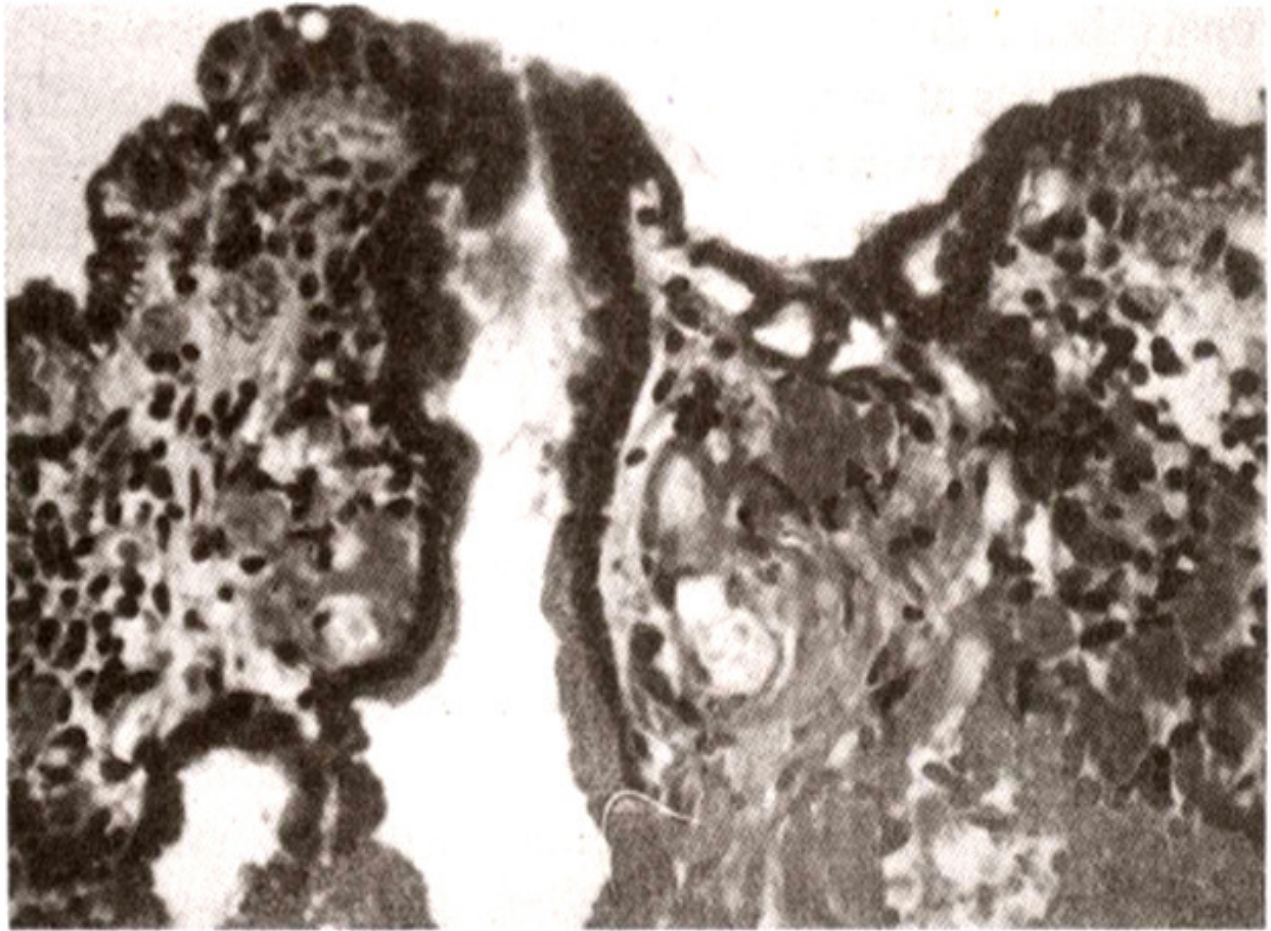


Figure 2. Section of gastric biopsy showing numerous acellular homogenous (amyloid deposits within lamina propria (arrow) H & E=40X.

Pretreatment with modified pennanganate stain followed by standard Congo red stain did not abolish the green birefringence in the polarized microscope confirming the AL type of amyloid (primary amyloidosis).

## Discussion

Amyloidosis of oesophagus may present with achalasia<sup>4-6</sup>, oesophageal spasms<sup>7</sup>, non-specific motility disorder<sup>8</sup> or decreased lower oesophageal sphincter pressure<sup>9</sup>. The manometric abnormalities observed are consistent with depositibn of amyloid in smooth and striated muscle as well as in the entire nervous system<sup>9,10</sup>. Though the manometric studies were not done in our case, severe motility dysfunction was apparent on endoscopic examination. Paucity of any propulsive waves and presence of a ring of contraction in the lower oesophagus could explain her symptoms of sticking of food and dysphagia. There was also endoscopic evidence of gastroparesis and bile reflux. Dysmotility had affected her bowel habits and she was experiencing increasing constipation, alteration in the bowel habits and intestinal pseudo-obstruction have been reported in amyloidosis of gut<sup>11</sup>. Our patient had AL type of amyloid deposits. In one study abdominal distension, nausea and vomiting were more frequent in patients of AL type whereas, incidence of diarrhoea and gastrointestinal bleeding was high in AA type<sup>12</sup>. Duodenum is involved in almost all cases of gastrointestinal amyloidosis as compared to rectum

which may be involved in 86-91% cases<sup>3,12</sup>. So duodenal biopsy should replace the rectal biopsy to increase the diagnostic yield.

## References

1. Case records of the Massachusetts General Hospital. Case 43-1985. N. Engl. J. Med., 1985;313:1070-9.
2. Kyle, R. A. and Greipp, P.R. Amyloidosis (AL). Clinical and laboratory features in 229 cases. Mayo Clin. Proc., 1983;58 :665-83.
3. Tada, S., Iida, M., Iwashita, A. et al. Endoscopic and biopsy findings of the upper digestive tract in patients with amyloidosis. Gastrointest. Endosc., 1990;36: 10-14
4. Costigan, D. J. and Clouse, R. E. Achalasia - like oesophagus from amyloidosis Successful treatment with pneumatic bag dilatation. Dig. Dis. Sci., 1983;28:763-5.
5. Lctkowitz, J. R., Brand, D. L., Schuffler, M. D. et al. Amyloidosis mimics achalasia's effect on lower esophageal sphincter. Dig. Dis. Sci., 1989;34:630-5.
6. Suns, X., Moya, F., Panes, J. et al. Achalasia of the esophagus in secondary amyloidosis. Am. J. Gastroenterol., 1993;88: 1959-60.
7. Funch - Jensen, P., Foged, E., Ravnsback, J. et al. A case of esophageal spasm in amyloidosis. Acta Med. Scand., 1986;219:229- 33.
8. Bjerle, P, Ek, B., Linderholm, H. et al. Oesophageal dysfunction in familial amyloidosis with polyneuropathy. Clin. Physiol., 1993; 13:57-69.
9. Burakoff. R., Rubinow. A. and Cohen, A. S. Esophageal manometry in familial polyneuropathy. Am. J. Med., 1985;79:85-9.
10. Rubinow, A., Burakoff R., Cohen, A. S. et al. Esophageal manometry in systemic amyloidosis. A study of 30 patients. Am. J. Med., 1983;75:951-6.
11. Lea, J. G., Wilson, J. A. and Gottfried, M. R. Gastrointestinal manifestations of amyloidosis. South Med. J., 1994;87:243-7.
12. Tada, S. Diagnosis of gastrointestinal amyloidosis with special reference to the relationship with amyloid fibril protein. Fukuoka Igaku Zasshi, 1991 ;82:624-47.