



7-2014

Coil embolization of wide neck cerebral aneurysms using balloon remodeling technique-initial experience in pakistan

Qasim Bashir

Bahria Town Hospital, Lahore, Pakistan.

Hina Nabi Ahmed

Bahria Town Hospital, Lahore, Pakistan.

Follow this and additional works at: <http://ecommons.aku.edu/pjns>

 Part of the [Neurology Commons](#)

Recommended Citation

Bashir, Qasim and Nabi Ahmed, Hina (2014) "Coil embolization of wide neck cerebral aneurysms using balloon remodeling technique-initial experience in pakistan," *Pakistan Journal of Neurological Sciences (PJNS)*: Vol. 9: Iss. 3, Article 6.

Available at: <http://ecommons.aku.edu/pjns/vol9/iss3/6>

COIL EMBOLIZATION OF WIDE NECK CEREBRAL ANEURYSMS USING BALLOON REMODELING TECHNIQUE-INITIAL EXPERIENCE IN PAKISTAN

Dr.Qasim Bashir¹, Dr.Hina Nabi Ahmed²

¹ Department of Neurointervention, Bahria Town Hospital, Lahore, Pakistan.

² Department of Anesthesia, Bahria Town Hospital, Lahore, Pakistan.

Date of submission: July 22, 2014, **Date of revision:** August 15, 2014, **Date of acceptance:** September 1, 2014

ABSTRACT

The balloon remodeling technique [BRT] was developed for neuroendovascular treatment of wide-necked cerebral aneurysms. Herein, we describe our initial experience of aneurysm embolization using BRT in Pakistan with the new double-lumen balloon catheters (Sceptor C and Ascent) and Hyperform balloon micro catheter and discuss its benefits.

Keywords: Balloon-assisted coil embolization, intracranial aneurysm, wide-neck

INTRODUCTION

First described by Moret J et al in 1994, the balloon remodeling technique [BRT] ⁽¹⁾ has been used to treat wide-neck cerebral aneurysms with a higher rate of coil packing density and safety if done in experienced hands. The balloon mounted micro catheter is temporarily placed across the neck of the aneurysm. With the balloon inflated, the aneurysm is then coiled through a second micro catheter placed within the dome of the aneurysm. At the end of the procedure, no device is left in place. In experienced hands, BRT can be used to treat sidewall, carotid bifurcation, basilar tip and bifurcating cerebral aneurysms. Herein, we report our initial experience of balloon assist coil embolization of wide neck cerebral aneurysms in Pakistan.

METHODS

A retrospective review of our neuroendovascular procedural data from the start of the program in May 2013 to May 31st, 2014 was performed. Of the total 120 neurointerventional cases, 21 cerebral aneurysms were treated. Of these 21 cases, 4 cases required balloon assist coiling [see Table 1].

RESULTS

The technique of coiling has been described in detail by the author with Debrun et al (2). All cases were performed under general anesthesia using single plane Toshiba Japan Infinix CFI Angiography system. Patients were systemically heparinized and serial activated clotting times [ACT] was obtained during the entire procedure to achieve adequate anticoagulation. 6Fr-guiding catheter [Chape Microvention,

Table 1: Baseline patient characteristics

Total Cases	4
Mean Age [years]	68.6
Gender	Females 2 Males 2
Indication	Unruptured -0 Ruptured -4
Hunt and Hess Grade	I-1 II-1 III-2
Previous SAH	1
Aneurysm Location	MCA-2 Acom-1 Basilar-1
Balloon Used	1. Sceptor-C x1 2. Ascent x 1 3. HyperGlide x2

Tustin, CA, USA] was placed in the ipsilateral internal carotid artery for anterior circulation aneurysms and left vertebral artery for the single case of brainstem AVM with prenidial aneurysm. The selected balloon micro catheter was conducted through a 0.014-inch guidewire and positioned across the neck of the aneurysm in each case. All four cases where BRT was employed had either a wide neck and/or a branch vessel in close proximity to the neck. A Headway 17 microcatheter [Microvention, Tustin, CA, USA] was positioned within the dome of the aneurysm sac. Aneurysm coiling was then performed with temporary balloon inflation until angiographic exclusion was complete. In case 2, we attempted coil embolization using BRT but this was impossible due to the wide neck of the aneurysm and MCA bifurcation location. BRT using two balloons simultaneously could not be entertained because of the same reason. If the aneurysm had been unruptured, stent assist coiling would have been a good option. However this could not be consid-

ered given the ruptured nature of the aneurysm and brain imaging showing impending progressive hydrocephalus. This patient was subsequently referred to Neurosurgery for clipping. All patients were extubated and arterial access sheaths removed. They were then monitored in Intensive Care Unit for 24 hours. Assessment of the completeness of endovascular therapy was assessed using the Assessment Scale as described by Debrun et al (2) [see Table 2].

Table 2:

Percentage [%] Occlusion	Description
100%	No contrast filling of the aneurysm on post coiling angiography
95%	Dog ear remnant or subtle contrast filling of the coil interstices.
<95%	Noticeable amount of contrast filling seen on post coiling angiography.

Table 3: Final Outcomes

Technical Success	75% [Fourth case-wide neck and referred for clipping]
Morphological Outcome	Initial Occlusion 100%-2 >95%-1 <95%-0
Procedural Outcomes	Asymptomatic Rupture-1 Symptomatic Rupture-0 Thromboembolic-0

DISCUSSION

The neuroendovascular management of cerebral aneurysms has advanced tremendously since the introduction of Guglielmi Detachable Coils [GDC] [3]. Long-term outcomes of this technique have shown that it is feasible option for both ruptured and unruptured cerebral aneurysms (4, 5). BRT or Stent assist coiling techniques have been proposed for wide necked bifurcation or side-wall aneurysms (6, 7, 8, 9, 10). In comparison to the stent assist coiling, BRT has the advantage of not requiring dual antiplatelet therapy during or after the procedure. Since 2003 with the invention of super compliant Hyperform [eV3, Plymouth, MN, USA] balloons, ones currently available include HyperGlide [eV3, Plymouth, MN, USA] and the newer double-lumen balloon catheters, Scepter C /XC [Microvention Inc., CA, USA] and Ascent [Cordis, USA]. The hydrophilic-coated balloon catheters come with radiopaque markers at the end of the balloon and the distal tip to facilitate fluoroscopic visualization. The newer double lumen balloon catheters allow a 0.014-inch guidewire for enhanced navigation as compared to 0.010-inch used for both HyperForm and HyperGlide [eV3

CASE 1: 70/M with ruptured Anterior Communicating [Acomm] Artery Cerebral Aneurysm.

Fig 1A: Right carotid angiography with contralateral carotid occlusion showing a saccular inferiorly directed Acomm aneurysm.

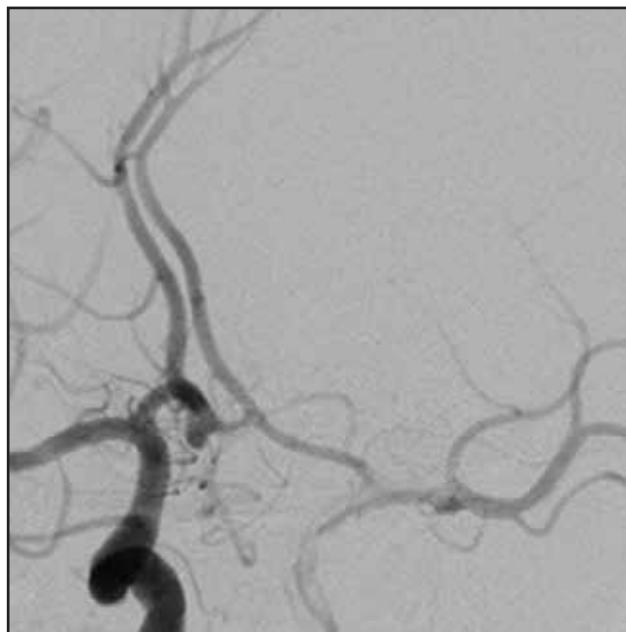


Fig 1A

Fig 1B: Native roadmap image showing microcatheter tip [Red arrow] within the dome of the aneurysm and balloon mounted microcatheter [Blue Arrow] across the aneurysm neck.




Fig 1B

Plymouth, MN, USA]. We report our first and initial experience

Fig 1C: Post Balloon-Assist coiling, complete obliteration of the aneurysm achieved without compromising the bilateral Anterior Cerebral Arteries and Acomm parent vessel

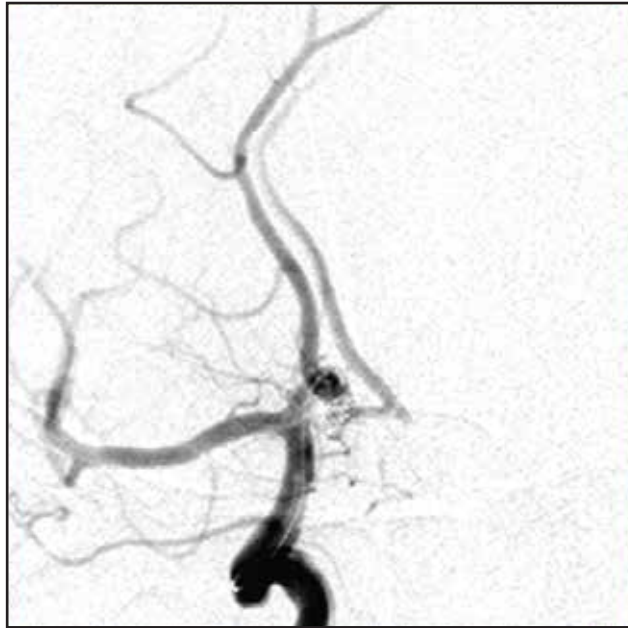

Fig 1C

Fig 2B: Native Roadmap image showing balloon assist coiling in progress. Note the coils conforming to the shape of the aneurysm and balloon inflated enough to prevent the coils hemiating down to the origin of the side branch.

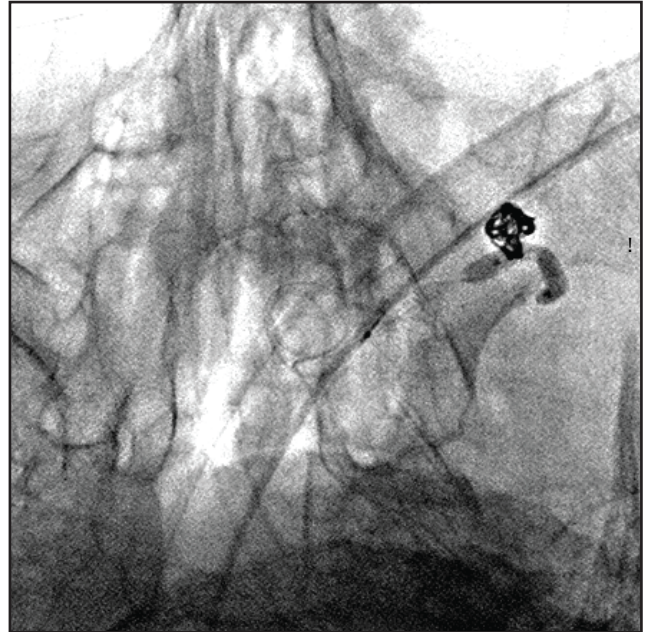


Fig 2B

CASE 2: 77F with ruptured Left Middle Cerebral Artery [MCA] Aneurysm.

Fig 2A: Left Carotid [Anteroposterior Projection] angiography showing a distal Left M1/MCA small aneurysm with a small side branch originating from its dome.

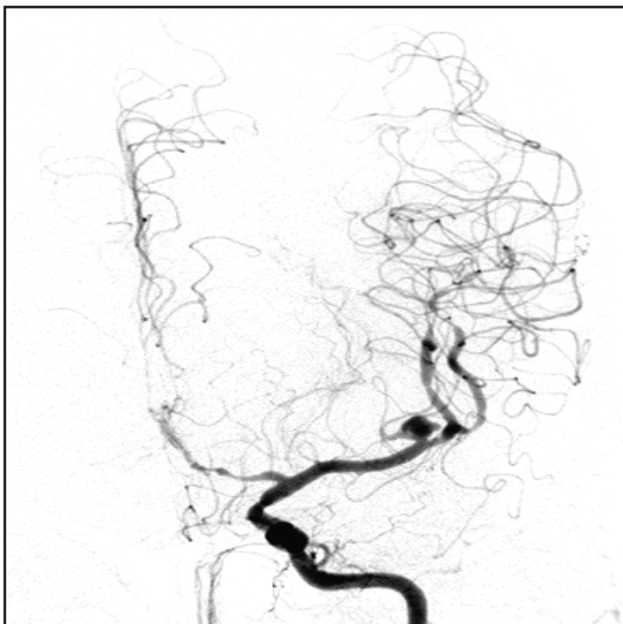


Fig 2A

Fig 2C: Post balloon assist coiling tiny aneurysm neck remnant intentionally left to preserve the patency of the side branch with complete obliteration of the aneurysm dome.

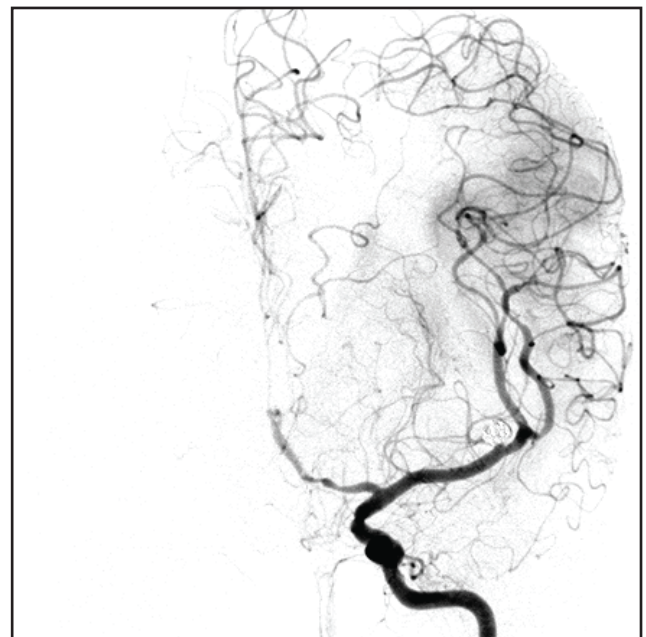


Fig 2C

Case 3: 69M with ruptured Arteriovenous Malformation and prolonged ICU stay before undergoing definitive neuroendovascular therapeutic intervention. Of note, the patient had been recommended radiation therapy for the AV malformation without determining its angioarchitecture.

Fig 3A: Left Vertebral artery angiography [Oblique projection] showing multiple [3] pre-nidal small aneurysms [Blue arrows] originating from pontine perforator branches and Right Anterior Inferior Cerebellar arterial feeder to the AV malformation nidus and draining vein [Red Arrow].

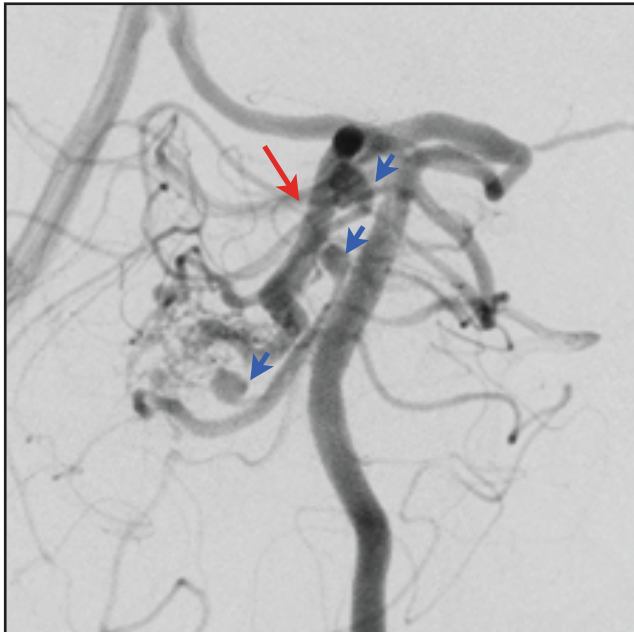


Fig 3A

of BRT for neuroendovascular treatment of cerebral aneurysms in Pakistan with a good technical success rate without any untoward complications using single plane angiography. Of the total 21 cerebral aneurysms treated with coil embolization, BRT was used in four and Stent Assistance in two. Our anatomic and clinical results treated with remodeling technique are at par with those reported in the literature ^(11,12)

CONCLUSION

Our case series of balloon remodeling using single plane angiography in a developing country suggests that this technique is not associated with higher complications related to thromboembolism or perforation. Postoperative infection risks are considerably high in such countries. Neuroendovascular approaches offer reduced length of hospital stay, infection risks and overall cost. However, operator experience with BRT is an essential pre-requisite. Neuroendovascular therapeutic modalities are at their

Fig 3B: Post balloon assist coiling and glue embolization left vertebral artery angiography. Note complete obliteration of the aneurysms without compromising the patency of the pontine perforators & noticeable reduction in the venous outflow of the AV malformation. Patient was recommended radiation therapy for the small residual AV malformation after a few months of general recovery following the initial bleed

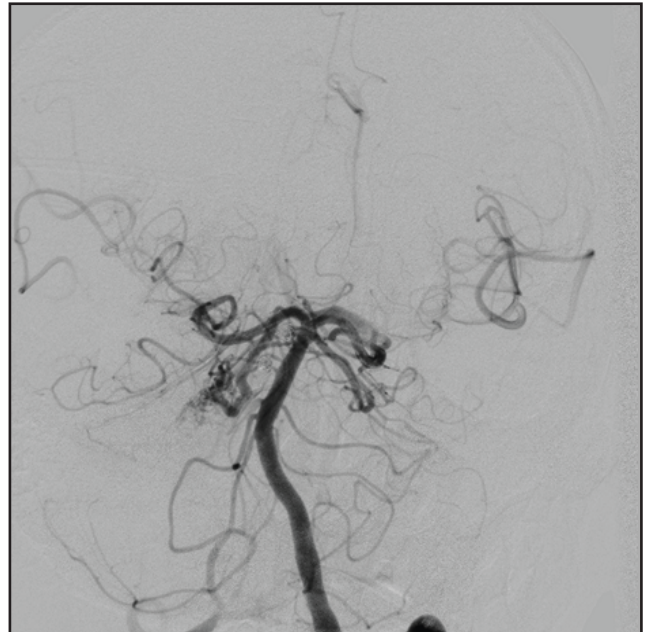

Fig 3B

infancy in these countries. Lack of universal health insurance system in such countries adds a huge financial burden to the poor and needy patients. All neurologic emergencies are time sensitive. Most often, even the most affluent are not be able to seek medical attention in time to reduce the associated neurological morbidity and mortality.

REFERENCES

1. Moret J, Cognard C, Weill A, et al. Reconstruction technique in the treatment of wide-neck intracranial aneurysms: long-term angiographic and clinical results. A propos of 56 cases. *J Neuroradiol.* 1997; 24: 30-44
2. Techniques of coiling cerebral aneurysms. G.M. De brun, V.A. Aletich, J.Thornton, A.Alazzaz, F.T.Char bel, J.I. Ausman, Q.Bashir. *Surg Neurol* 2000;53:150-6

3. Guglielmi G, Viñuela F, Dion J, Duckwiler G: Electro thrombosis of saccular aneurysms via endovascular approach: Part II—Preliminary clinical experience. *J Neurosurg* 75:8–14, 1991.
4. Sluzewski M, Von Rooij WJ, Beute GN, et al. Balloon-assisted coil embolization of intracranial aneurysms: incidence, complications, and angiography results. *J Neurosurg* 2006;105:396–99.
5. Pierot L, Cognard C, Anxionnat R, et al, for the CLARITY group. Remodeling technique for endovascular treatment of ruptured intracranial aneurysms had a higher rate of adequate postoperative occlusion than did conventional coil embolization with comparable safety. *Radiology*. 2011;258:546–53.
6. Cekirge H S, Yavuz K, Geyik S, et al. A novel “Y” stent flow diversion technique for the endovascular treatment of bifurcation aneurysms without endovascular coiling. *Am J Neuroradiol*. 2011; 32: 1262-1268.
7. Saatci I, Geyik S, Yavuz K, et al. X-configured stent-assisted coiling in the endovascular treatment of complex anterior communicating artery aneurysms: a novel reconstructive technique. *Am J Neuroradiol*. 2011; 32:E113-117.
8. Chow MM, Woo HH, Masaryk TJ, et al. A novel endovascular treatment of a wide-necked basilar apex aneurysm by using a Y -configuration, double-stent technique. *Am J Neuroradiol*. 2004; 25: 509-512.
9. Baldi S, Mounayer C, Piotin M, et al. Balloon-assisted coil placement in wide-necked bifurcation aneurysms by use of a new, compliant balloon microcatheter. *Am J Neuroradiol*. 2003; 24: 1222-1225.
10. Mocco J, Snyder KV, Albuquerque FC, et al. Treatment of intracranial aneurysms with the Enterprise stent: a multicenter registry. *J Neurosurg*. 2009; 110: 35-39.
11. Cottier JP, Pasco A, Gallas S, et al. Utility of balloon-assisted Guglielmi detachable coiling in the treatment of 49 cerebral aneurysms: a retrospective, multicenter study. *AJNR Am J Neuroradiol* 2001;22:345–51
12. Lefkowitz MA, Gobin YP, Akiba Y, et al. Balloon-assisted Guglielmi detachable coiling of wide-necked aneurysms. II. Clinical results. *Neurosurgery* 1999;45: 531–37.

Conflict of Interest: Author declares no conflict of interest.

Funding Disclosure: Nil

Author’s Contribution:

Dr. Qasim Bashir: Study concept and design, protocol writing, data collection, data analysis, manuscript writing, manuscript review

Dr. Hina Nabi Ahmed: Data collection, data analysis, manuscript writing, manuscript review