



THE AGA KHAN UNIVERSITY

eCommons@AKU

---

General Surgery, East Africa

Medical College, East Africa

---

June 2011

# Gynaecomastia; management with liposuction and glandular excision

Stanley Ominde Khainga  
*University of Nairobi*

Ronald Wasike  
*Agha Khan University, [ronald.wasike@aku.edu](mailto:ronald.wasike@aku.edu)*

P. K. Biribwa  
*University of Nairobi*

Follow this and additional works at: [http://ecommons.aku.edu/eastafrica\\_fhs\\_mc\\_gen\\_surg](http://ecommons.aku.edu/eastafrica_fhs_mc_gen_surg)

 Part of the [Plastic Surgery Commons](#)

---

## Recommended Citation

Khainga, S. O., Wasike, R., Biribwa, P. K. (2011). Gynaecomastia; management with liposuction and glandular excision. *East African Medical Journal*, 88(6), 212-216.

**Available at:** [http://ecommons.aku.edu/eastafrica\\_fhs\\_mc\\_gen\\_surg/19](http://ecommons.aku.edu/eastafrica_fhs_mc_gen_surg/19)

*East African Medical Journal Vol 88 No. 6 June 2011*

#### GYNAECOMASTIA: MANAGEMENT WITH LIPOSUCTION AND GLANDULAR EXCISION

S. O. Khainga, MBChB, MMed Surg, FCS (Plast) FCS(COSECSA), Senior Lecturer, Department of Plastic Surgery, College of Health Sciences, University of Nairobi, P. O. Box 19676-00202, Nairobi, R. W. Wasike, MBChB, MMed Surg(U.O.N), FRCS (C), Aga Khan University Hospital, P. O. Box 30270-00100, Nairobi, Kenya, P. K. Biribwa, MBChB, Registrar, Department of Plastic Surgery, College of Health Sciences, University of Nairobi, P. O. Box 19676-00202, Nairobi, Kenya

Request for reprints to: Dr. S. O. Khainga, Department of Plastic Surgery, College of Health Sciences, University of Nairobi, P. O. Box 19676-00202, Nairobi, Kenya

## GYNAECOMASTIA: MANAGEMENT WITH LIPOSUCTION AND GLANDULAR EXCISION

S. O. KHAINGA, R. W. WASIKE and P. K. BIRIBWA

### SUMMARY

**Gynaecomastia is caused by an increase in ductal tissue, stroma and fat in the male breast. Frequently it occurs at the time of hormonal changes during infancy, adolescence and old age. Galen, introduced the term gynaecomastia in the second century AD and surgical excision was first described by Pauli of Aegina in the seventh AD (1,2). Ultrasound assisted liposuction and surgical excision of glandular tissue through an inferior circumareolar incision is currently the best mode of treatment. In this study seven patients varying from the ages 17-45 years were operated on using this technique at the Aga Khan University teaching Hospital. Of these, four had drains inserted and the other three had none. Of the latter, two had seromas as a complication which was managed with serial aspiration. The group with drains healed without complication of seroma. Investigations done were limited and non exhaustive for patients with gynaecomastia.**

### INTRODUCTION

Gynaecomastia is a common condition being present in 30-50% of healthy men. It may be an incidental finding, an acute unilateral or bilateral tender breast enlargement or a progressive painless enlargement of the male breast. A general medical history and examination to rule out features suggestive of cancer is mandatory. Gynaecomastia of recent onset requires a more detailed evaluation including laboratory tests to establish the underlying cause (1-4).

Treatment depends on the cause for instance an offending drug may need to be withdrawn or an alternative treatment such as radiotherapy, surgery and medical therapy may be necessary. The use of a combination of surgical excision through a periareolar incision and liposuction represents the surgical approach of choice (5).

Gynaecomastia is caused by an increase in the ratio of estrogen to androgen activity (4). It is commonly associated with breast pain, which may range from mild tenderness to constant pain and tension. In this case series, palpable breast tissue was detected on physical examination in 36% of healthy young adults, 57% of the healthy older men and more than 70% of hospitalised elderly men. In autopsy studies, its prevalence has been as high as 55% (4,6).

In general gynaecomastia can be observed in three peaks during life. In the neonatal period, 60-90% of infants have transient of maternal estrogens (6). At puberty, 48-64% of boys experience gynaecomastia and peaks at 13-14 years only to decline in late teenage years (7). In late life, the incidence of gynaecomastia is seen among men aged 50-80 years.

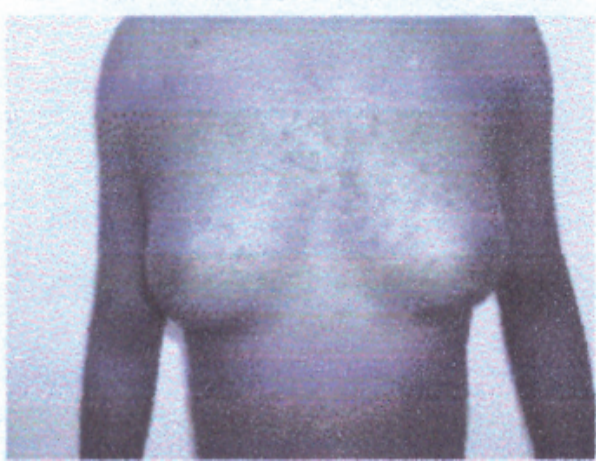
### CASE REPORT

Liposuction markings are made with the patient in an erect position. Tumescant fluid infiltrated into the areas for liposuction as already marked and ultrasound assisted liposuction performed. The volume of fat aspirated recorded so as to correlate with the opposite side. The glandular tissue of both sides excised via an inferior semicircumareolar incision and a closed drain left *in situ*. A pressure garment vest is worn by the patient for three weeks. The drains are removed once the hematoma is less than 20cc per 24 hours.

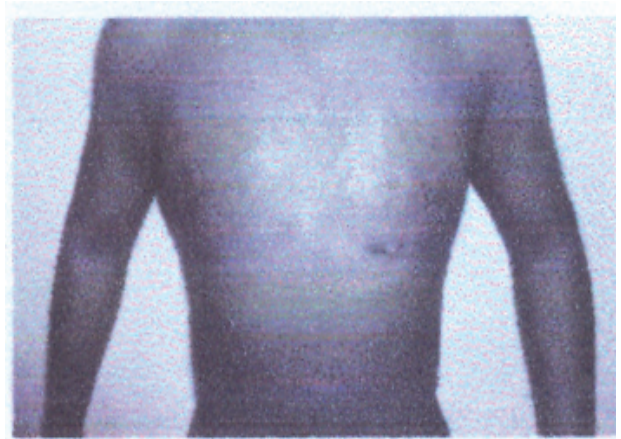### RESULTS

Appearances of front and lateral views of patients before and after ultrasound assisted liposuction and glandular excision are illustrated in figs. 1 to 4.

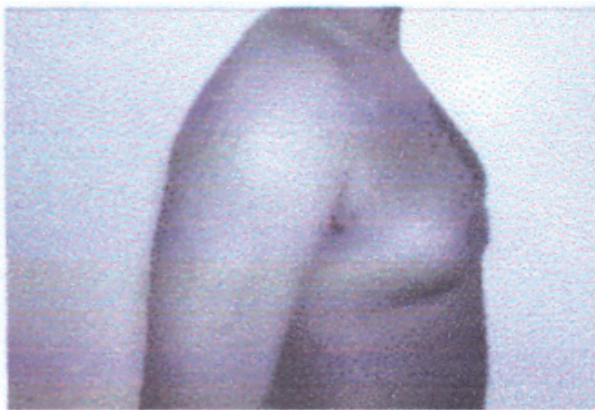
**Figure 1a**  
*Gyneacomastia Front view before procedure*



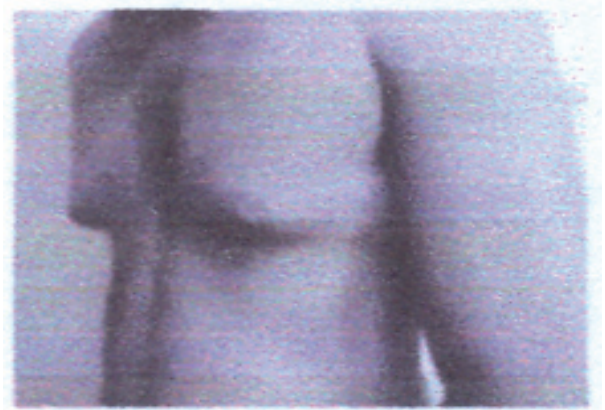**Figure 1b**  
*Front view after the procedure*



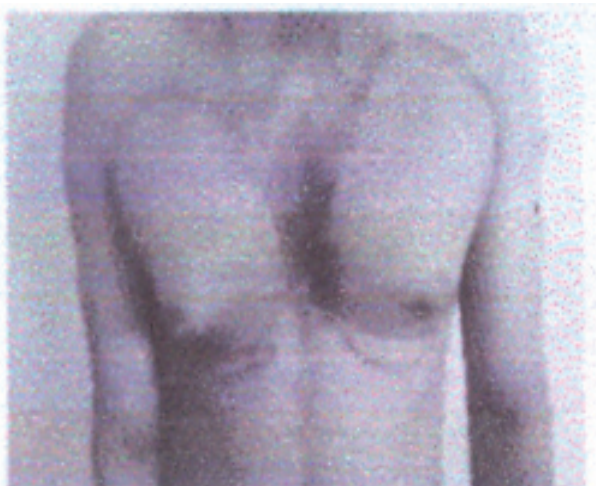**Figure 1c**  
*Lateral view before*



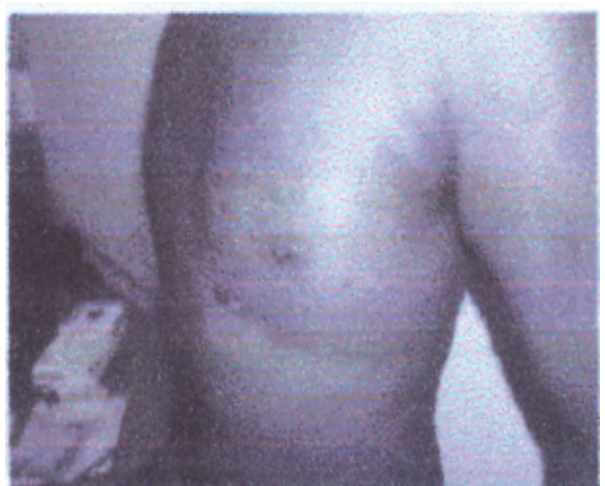**Figure 1d**  
*Lateral view before*



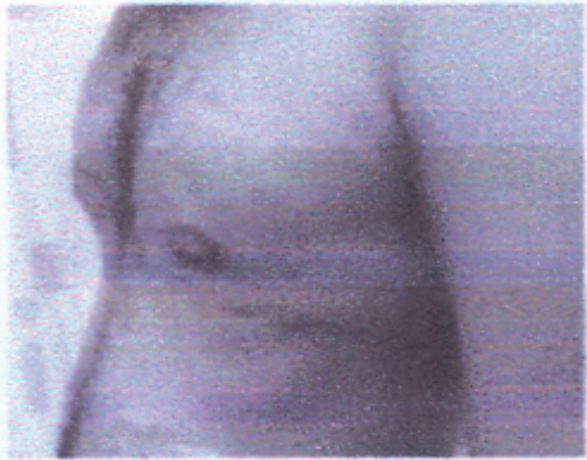
**Figure 2a**  
*Front view before*



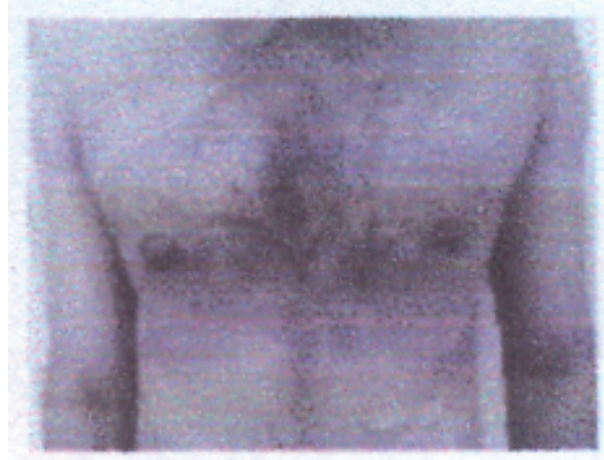
**Figure 2b**  
*Lateral view after*



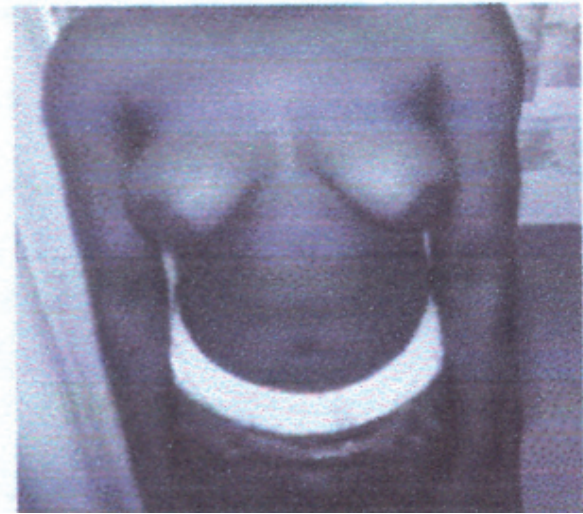**Figure 2c**  
*Lateral view after*



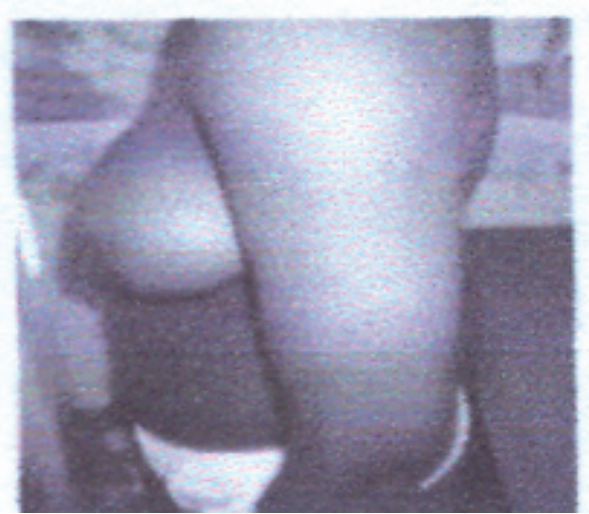**Figure 2d**  
*Front view after*



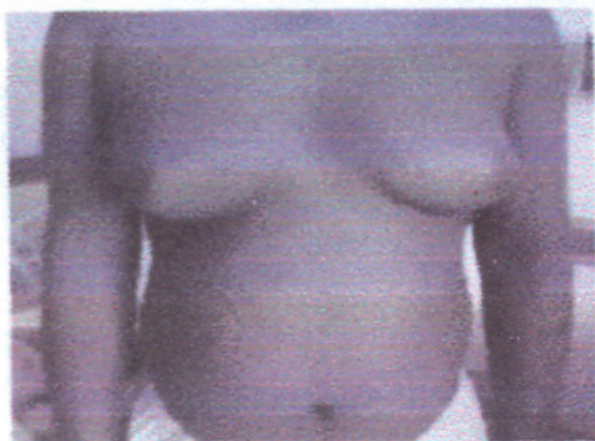**Figure 3a**  
*Gynaecomastia; Massive gynaecomastia*  
*Front view before procedure*



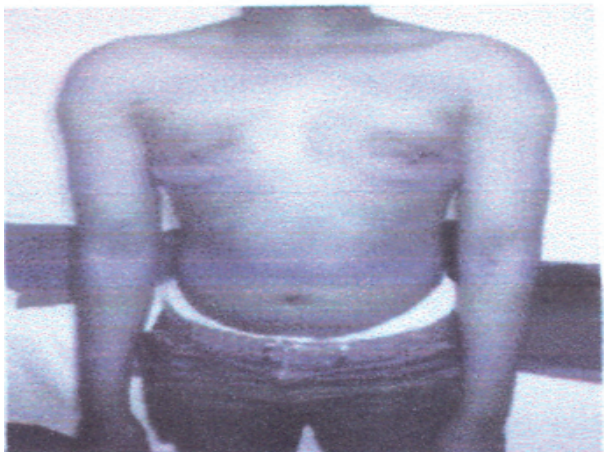**Figure 3b**  
*Before procedure Lateral view*



**Figure 3c**  
*Front view before*



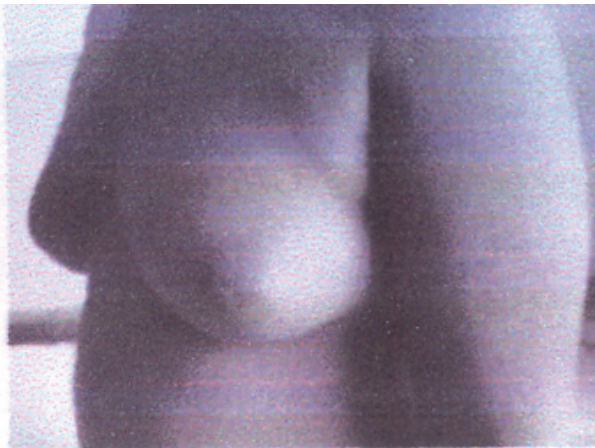
**Figure 3d**  
*Front view after the procedure*



**Figure 4a**  
*After procedure Lateral view*



**Figure 4b**  
*Lateral view before*



**Figure 4c**  
*Immediate post-operative*



## DISCUSSION

Gynaecomastia is enlargement of male breast tissue. 'Gynae' means 'woman' and 'mastos' means breast in Greek. It can be defined as the presence of >2cm of palpable form, subareolar gland and ductal breast tissue (6).

In this study, the weight measurement was done of breast tissue excised and volume (cc) of fat tissue suctioned. The weight of glandular tissue excised was recorded in grams. The volume ranged from as low as 300cc to as high as 1010cc fat suctioned while the lowest weight was 180gm and the highest was 400gm. A close correlation between volume of fat suctioned and the weight of glandular tissue excised was observed.

This condition may occur at any age and there are a number of causes, some physiological and others pathological. Pathological causes involve an imbalance between the activity of androgens and oestrogens the former is decreased compared to the latter (5, 6). In this study, the youngest patient was 17years and the oldest was 45 years. The latter had low levels of testosterone in his hormonal profile.

The approach to a patient with gynecomastia needs to be meticulous. A comprehensive history, careful complete examination of the patient and investigations based on clinical findings performed (6). The history should determine the onset and duration of enlargement, tenderness, presence of sexual dysfunction and drug ingestion or abuse. The examination should determine whether the enlargement is pseudogynaecomastia due to proliferation of breast tissue (2). Size and asymmetry of enlarged breasts, evidence of liver disease, evidence of lack of testosterone, presence or absence, of sexual characteristics and signs of hyperthyroidism or Cushing's syndrome, all should be looked for.

Investigations should be relevant and have clinical basis. Renal, liver and thyroid function tests, hormonal profile, ultrasound, mammography, CXR, chromosomal studies and biopsy are tests which can be of relevance in patients with gynecomastia. In this study, all the patients had ultrasound done, majority had renal function test and total blood count done, two had hormonal profile assay and one had CT scan of the head done. The 45-year old patient reported low testosterone level.

The first surgical procedures to treat gynecomastia were excisional in nature (8) suction assisted lipectomy was first reported in the early 1980s (9) and more recently ultrasound assisted liposuction has been used for certain types of gynecomastia (3). In this study, a combination of ultrasound assisted liposuction and excision of glandular breast tissue through a periareolar incision was applied. The tissue is pulled through the wound and is removed with scissors or electric cautery. The pull through resection

is performed until desired contours are achieved. All patients are treated with pressure garments. Our patients wore pressure garments for three weeks. This maintains close contact of the skin and underlying subcutaneous tissues onto the chest wall and this prevents hematoma formation. In this study, two of the seven patients developed seromas which resolved after weekly aspiration over three weeks. In some patients, skin resection maybe required from 6 to 12 months after the initial surgery. For the majority of patients, this is not usually necessary but in cases where it is done, the skin resection and the length of the incision line are much less than if the resection were performed at the time of the initial surgery.

The most common early complication after gynaecomastia surgery is hematoma. Post-operative closed suction drainage decreases the incidence of this complication. The two patients with seroma formation in this study did not have drains inserted. Other complications that may arise are; under resection especially at the periphery, over resection in the nipple areolar area can cause a saucer type deformity that is difficult to correct. Loose skin may occur in an unexpected manner and surgical excision may be required. Wound sepsis is uncommon and use of prophylactic antibiotics may account for the low incidence. None of the patients developed wound infection. In conclusion, this technique that combines ultrasound assisted liposuction and pull through

resection of glandular breast tissue is effective and provides good cosmetic results as well as high degree of patient satisfaction.

#### REFERENCES

1. Goldwyn, R. Plastic and Reconstructive Surgery of the Breast. *Boston: Little Brown*; 1976.
2. McGrath, M. H. Gynaecomastia In: Jurkiewicz, J. M. J., Mathes, S. J., Krizek, T. J., *et al.* Plastic surg: principles & Practices St. louis: Mosby;
3. Rohrich, R. J., Ha, R. Y., Kenkel, J. M., *et al.* Classification and Managent of gynaecomastia: defining the role of ultrasound assisted liposuction. *Plastic & Reconstructive Surg.* 2003; **111**: 909.
4. P. Gikas, M. D., Kefah Mokbel, M. S. FRCS; An Update. *Intl. J. Clin. Pract.* 2007; **71**: 1209-1215.
5. Bembo, S. A. and Carlson, H. E. Gynaecomastia: its features, when and how to treat it. *Cleve. Clin. J. med.* 2004; **71**: 511-517.
6. Neiwöhner, C. B. and Schorer, A. E. Gynaecomasti and Breast Cancer in men *Brit. Med. J.* 2008; **25**: **336**: 709-713.
7. Navura, H. S. and Carlson, H. E. Gynaecomastia, Endocrine Metab. *Clin. North Am.* 2007; **36**: 497-529.
8. Webster, J. P. Mastectomy for gynaecomastia through a semi circular incision. *Ann surg.* 1946; **124**: 557.
9. Courtiss, E. H. Gynaecomastia: analysis of 159 patients and current recommendations for treatment. *Plast. Reconstr. Surg.* 1957; **79**: 740.