



THE AGA KHAN UNIVERSITY

eCommons@AKU

Department of Pathology and Laboratory Medicine

Medical College, Pakistan

March 2011

Gastric MALT lymphoma: a rarity

Shahid Pervez
Aga Khan University

Naureen Ali
Aga Khan University

Hina Aaqil
Aga Khan University

Khalid Mumtaz
Aga Khan University

Syed Siddiq Ullah
Aga Khan University

See next page for additional authors

Follow this and additional works at: http://ecommons.aku.edu/pakistan_fhs_mc_pathol_microbiol

 Part of the [Pathology Commons](#)

Recommended Citation

Pervez, S., Ali, N., Aaqil, H., Mumtaz, K., Siddiq Ullah, S., Akhtar, N. (2011). Gastric MALT lymphoma: a rarity. *Journal of the College of Physicians and Surgeons Pakistan*, 21(3), 171-2.

Available at: http://ecommons.aku.edu/pakistan_fhs_mc_pathol_microbiol/8

Authors

Shahid Pervez, Naureen Ali, Hina Aaqil, Khalid Mumtaz, Syed Siddiq Ullah, and Nake Akhtar

Gastric MALT Lymphoma: A Rarity

Shahid Pervez¹, Naureen Ali¹, Hina Aaqil¹, Khalid Mumtaz², Syed Siddiq Ullah¹ and Nake Akhtar¹

ABSTRACT

Association of *Helicobacter pylori* (*H. Pylori*) infection with gastric 'Mucosa Associated Lymphoid Tissue' (MALT) lymphomas (MALTomas) is well established. In this study the frequency and characteristics of gastric MALToma over a period of 18 years was evaluated. During this period 24 patients with gastric MALToma were diagnosed; out of them, 13 (54.2%) had active *H. Pylori* infection. The mean and median age was 49.7 and 53.5 years. The male: female ratio was 17:7. The common presenting complaints were epigastric pain (n=10) and dyspepsia (n=9). Endoscopic findings revealed mild gastric hyperemia (n=16), superficial erosions (n=4) and superficial ulcers (n=4). It was concluded that the prevalence of gastric MALToma was very low in contrast to a high *H. pylori* gastritis in the Pakistani population.

Key words: *Helicobacter pylori*. MALToma. Lymphoma. Stomach.

MALT lymphomas were first described in 1983 by Peter Isaacson and Dennis Wright. They noted that primary low grade gastric B-cell lymphomas recapitulate the histology of Mucosa Associated Lymphoid Tissue (MALT) exemplified by the Peyer's patches and coined the term 'MALT lymphoma'. These lymphomas are currently recognized as 'Extranodal marginal zone B-cell lymphomas of MALT type' according to the 'WHO Classification for tumours of hematopoietic and lymphoid tissues'.¹ The stomach is the most reported and best studied site of MALT lymphomas. An intimate relationship has been reported between the presence of *Helicobacter pylori* (*H. pylori*) in the stomach and the development of MALT lymphoma. In fact the pathogenesis of gastric MALT lymphoma is believed to be caused by repeated antigenic stimulation of the immune system in the stomach by *H. pylori*. The role of *H. pylori* in the pathogenesis of gastric MALTomas can be illustrated by the fact that 75% of the patients who have gastric MALToma undergo remission if treated with antibiotics to eradicate *H. pylori*.² About half the people in the world have *H. pylori* colonized in their gastrointestinal tract. Of these most remain asymptomatic. Despite the fact that, a high prevalence of *H. pylori* is reported from Pakistan,^{3,4} the prevalence of gastric MALToma is very low in our experience. Therefore, this study was carried out with the objective of studying the frequency of MALTomas in a population with a high prevalence of *H. pylori* associated gastritis.

Medical records of all the patients diagnosed to have gastric MALToma over an 18 years period (January 1991 to December 2008) according to ICS-9 coding system

were retrieved. A total of approximately, 4000 ± 500 gastroscopies are performed in the institution's endoscopy unit annually. The medical records of all cases with diagnosis of gastric MALToma (extra nodal marginal B-cell lymphomas of the MALT) were reviewed for relevant clinical information along with retrieval and review of histopathological slides and blocks. Relevant immunohistochemical workup was done in all cases. Twenty four confirmed cases of gastric MALTomas over a period of 18 years were retrieved.

The mean and median ages of patients with gastric MALToma were 49.7 years and 53.5 (ranging from 18-80 years). The male: female ratio was 17:7. Thirteen patients (54.2%) were found to have active *H. pylori* infection at the time of diagnosis. Two of these cases had a past diagnosis of active *H. pylori* associated gastritis on endoscopic biopsies which was not treated.

The presenting symptoms of the cohort included epigastric pain (n=10), dyspepsia (n=9), chronic diarrhoea (n=2), weight loss (n=2) and nausea (n=1). The endoscopic examination findings included gastric antral hyperemia, gastric antral erosion, small gastric antral superficial ulcer etc. The typical histopathologic features included extensive mucosal infiltration by centrocyte-like B-cells and lymphoepithelial lesions (Figure 1). Neoplastic cells were positive for LCA, CD20 and CD79a with low mib-1 (ki-67). The reactive population contained abundant CD3 positive T cells and in many cases well developed lymphoid follicles with germinal centers (Figure 1).

This study is the first report of its kind from Pakistan. It was found that despite the high seroprevalence of *H. pylori* infection in the Pakistani population (58.3%),^{3,4} cases with MALT lymphomas were few. This correlates with the 'Asian enigma' described by various authors where less developed Asian countries like Pakistan, India, Bangladesh and Thailand have lower rates of

Department of Pathology¹/Medicine², The Aga Khan University Hospital, Karachi.

Correspondence: Dr. Shahid Pervez, House No. 639, DOHS-1, Malir Cantt, Karachi.

E-mail: shahid.pervez@aku.edu

Received January 12, 2010; accepted January 07, 2011.

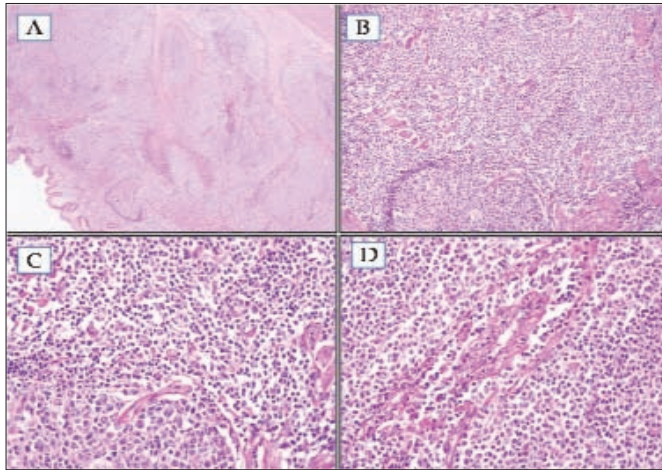


Figure 1: Microphotographs of a case of gastric MALToma (A, B & C) showing a lymphoid follicle with sheets of monomorphic small and irregular centrocyte like tumour cells emanating from inconspicuous marginal zone of the follicle (H & E, Mag: 4X, 10X & 20X). (D) Lympho-epithelial lesion showing extensive infiltration of the glandular epithelium by small neoplastic cells, H & E: Mag 20X

gastric carcinoma compared to well developed countries like Japan and China, despite a higher prevalence of *H. pylori* infection in the former population. *H. pylori* infection has been established to have a role in the etiology of gastric carcinoma and its paradoxical high prevalence in areas with few cases of gastric carcinoma has long puzzled researchers. Available evidence does not support difference in *H. pylori* strains as the sole explanation for this enigma. It has also been observed that patients with duodenal ulcer caused by *H. pylori*, do not develop gastric tumours, in contrast to other *H. pylori*-associated pathology, such as gastric ulcer. This illustrates variation in host responses despite infection with the same organism, and so suggests the role of genetic factors in different ethnic groups.

Thus, precisely, who will develop a neoplastic lesion associated with *H. pylori*, like MALToma, probably depends on 3 factors: the virulence of the *H. pylori* strain, types and extent of the host immune response and co-factors like diet and smoking.

In 1993 Wotherspoon and colleagues described remarkable observation of regression of MALToma, by eradication of *H. pylori* with use of antibiotics.⁵ Response range was reported to be between 60-90%. Transformation into large B-Cell lymphoma is also possible. Most of the lesions appeared to pursue an indolent clinical course. In some cases (45.8%), no evidence of *H. pylori* infection was found. In such cases it is not clear whether the infection has been present previously and resolved at a stage after the lymphoma has attained autonomous growth or whether there is yet another unrecognized causative agent. A more detailed investigation into the epidemiologic and etiological factors in this part of the world would be invaluable in the search for the exact cause of gastric MALT lymphoma and its link to *H. pylori*.

REFERENCES

1. Issaacson PG, Chott A, Nakamura S, Hermelink M, Harris NL, Swerdlow SH, editors. WHO classification of tumours of haematopoietic and lymphoid tissues. Extranodal marginal zone lymphoma of mucosa-associated lymphoid tissue (MALT lymphoma), 4th ed. France: IARC; 2008. p. 214-9.
2. Ono S, Kato M, Ono Y, Itoh T, Kubota K, Nakagawa M, et al. Characteristics of magnified endoscopic images of gastric extranodal marginal zone B-cell lymphoma of the mucosa-associated lymphoid tissue, including changes after treatment. *Gastrointest Endosc* 2008; **68**:624-31. Epub 2008 Jun 5. Comment in: p. 632-4.
3. Abbas Z, Jafri W, Khan AH, Shah MA. Prevalence of *Helicobacter pylori* antibodies in endoscopy personnel and non-medical volunteers of Karachi. *J Pak Med Assoc* 1998; **48**:201-3
4. Ahmad T, Rakhshanda B, Azra K. Prevalence of *Helicobacter pylori* infection in asymptomatic children of Islamabad suburbs (Pakistan). *Int J Agriculture Biol* 2008; **10**:685-8.
5. Fischbach W, Goebeler-Kolve ME, Dragosics B, Greiner A, Stolte M. Long-term outcome of patients with gastric marginal zone B cell lymphoma of mucosa associated lymphoid tissue (MALT) following exclusive *Helicobacter pylori* eradication therapy: experience from a large prospective series. *Gut* 2004; **53**:34-7.

