



THE AGA KHAN UNIVERSITY

eCommons@AKU

Department of Pathology and Laboratory Medicine

Medical College, Pakistan

May 1996

# Churg-Strauss Syndrome with Intestinal perforation

Javaid A. Khan  
*Aga Khan University*

Imran Hassan  
*Aga Khan University*

Shahid Pervez  
*Aga Khan University, shahid.pervez@aku.edu*

Wasim Jafri  
*Aga Khan University*

Shaista Khan  
*Aga Khan University*

Follow this and additional works at: [http://ecommons.aku.edu/pakistan\\_fhs\\_mc\\_pathol\\_microbiol](http://ecommons.aku.edu/pakistan_fhs_mc_pathol_microbiol)

 Part of the [Medical Pathology Commons](#), [Otolaryngology Commons](#), [Pathology Commons](#), and the [Respiratory Tract Diseases Commons](#)

## Recommended Citation

Khan, J. A., Hassan, I., Pervez, S., Jafri, W., Khan, S. (1996). Churg-Strauss Syndrome with Intestinal perforation. *Journal of Pakistan Medical Association*, 46(5), 109-110.

**Available at:** [http://ecommons.aku.edu/pakistan\\_fhs\\_mc\\_pathol\\_microbiol/308](http://ecommons.aku.edu/pakistan_fhs_mc_pathol_microbiol/308)

# Churg-Strauss Syndrome with Intestinal Perforation

Pages with reference to book, From 109 To 110

Javaid A. Khan, Imran Hassan ( Departments of Medicine, The Aga Khan University Hospital, Karachi. )

Shahid Pervaiz ( Department of Pathology, The Aga Khan University Hospital, Karachi. )

Wasim Jafri ( Department of Medicine, The Aga Khan University Hospital, Karachi. )

Shaista Khan ( Departments of Surgery, The Aga Khan University Hospital, Karachi. )

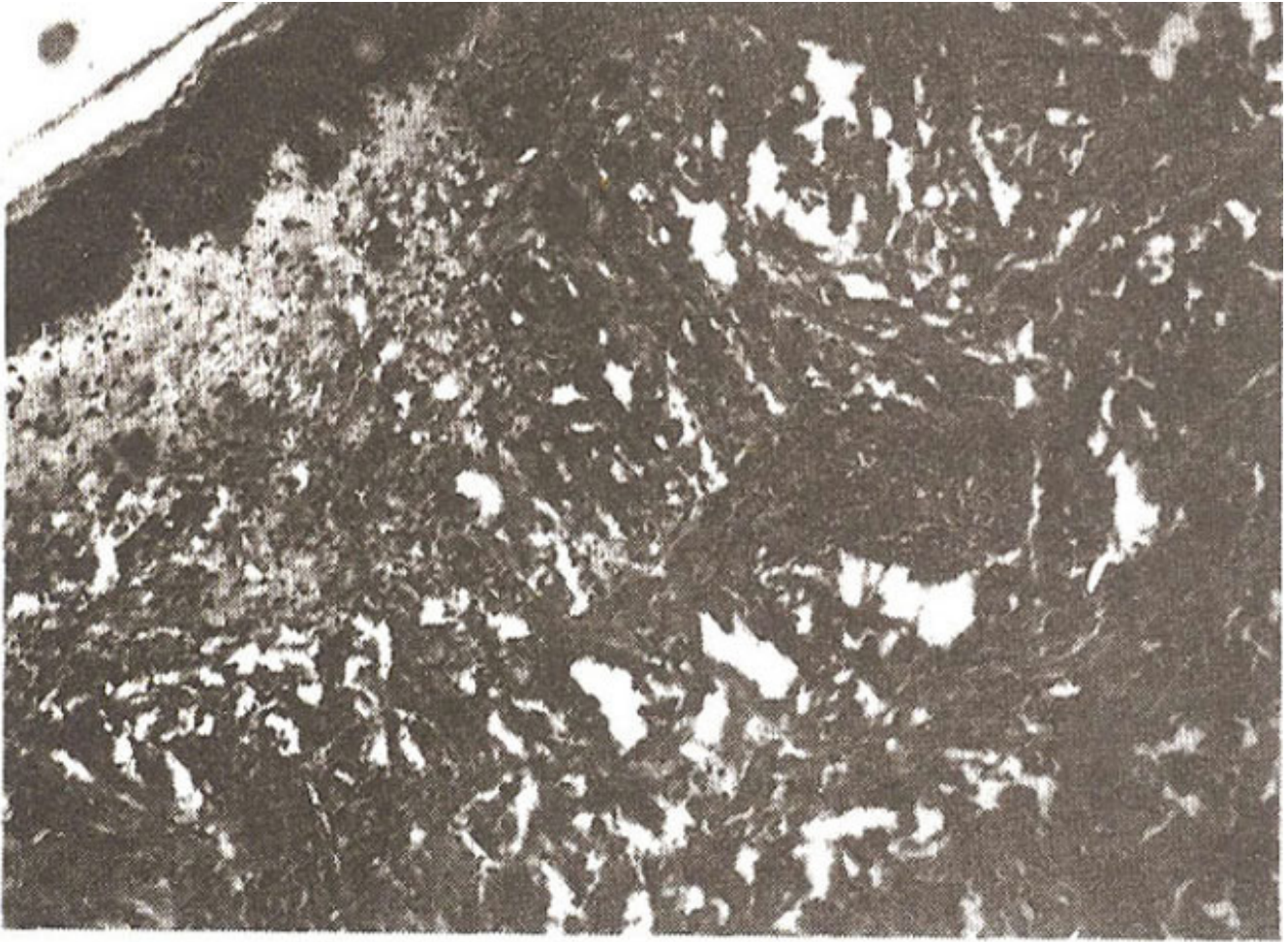
## Introduction

Churg Strauss syndrome (CSS) (allergic granulomatosis and angiitis) is a systemic disorder characterized by asthma, transient pulmonary infiltrates, hypereosinophilia and a systemic vasculitis<sup>1-3</sup>. CSS is a rare disease; however, this syndrome has been reported with increasing frequency in recent years<sup>2</sup>. The organs most evidently involved clinically are the heart, lungs, kidney, gut, skin and peripheral nerves<sup>3</sup>.

We present a case of Churg-Strauss Syndrome complicated by intestinal perforation and intracerebral hemorrhage, along with a review of literature regarding gastrointestinal involvement in this condition.

## Case History

A 45 years old gentleman was admitted to the hospital because of headache, dysphasia and right hemiparesis for one day. He had been well until two years ago when he began experiencing paroxysmal attacks of wheezing. A total white count done at that time was  $18 \times 10^9/L$  with 73% eosinophils. He was prescribed inhaled bronchodilators and steroids, yet he continued to have episodes of breathlessness and wheezing during the next two years. One month prior to admission to the hospital he began complaining of intense joint pain, dyspnoea and weakness in his hands. He also developed a papular rash over both feet. A complete blood picture showed the white blood count to be  $30.9 \times 10^9/L$  with 64% eosinophils. A skin biopsy was taken which showed leukoclastic vasculitis (Figure).



**Figure.** Section of the skin showing dermal capillaries with severe inflammatory infiltrate. It is composed largely of neutrophils with some eosinophils many of which show fragmentation (leukoclastic vasculitis) MAG = 20X.

He was treated with prednisolone for one week following which his symptoms, particularly his wheezing improved.

At the time of admission, he was conscious but disorientated in time, place and person. He was afebrile, pulse was 90/minute and blood pressure was 140/80 mmHg. Neurological examination showed dysphasia and upper motor neuron palsy of the seventh and twelfth cranial nerves on the right side. There was right hemiparesis along with bilateral wrist drop with wasting of small muscles of both hands. There also was evidence of Raynaud's phenomenon. Examination of all other systems was unremarkable. His hemoglobin was 14.4 g/dl and white cell count was  $9 \times 10^9/\text{L}$  with 70% polymorphs, 18% lymphocytes and 12% eosinophils. A CT scan showed an intracerebral bleed in the left temporal region. Subsequently his neurological status improved over the next few days. The nerve conduction study was consistent with mononeuritis multiplex. His anti-neutrophilic cytoplasmic antibodies (ANCA) was positive while the chest x-ray was normal. He was treated with cyclophosphamide and steroids.

On the sixth day of admission, he suddenly developed severe abdominal pain which gradually increased. He became hypotensive and developed signs of generalized peritonitis. An X-ray film of the abdomen showed pneumoperitoneum. A laparotomy was performed and per operatively a solitary punched out perforation 135 cm from the duodenojejunal flexure was seen. Wedge resection and primary closure of the perforation was done.

Histopathology of the gut wall taken from the perforation showed heavy infiltration of acute inflammatory cells.

His post-operative course was uneventful and he was discharged on Prednisolone and Cyclophosphamide. Six months post-operation, he had a grand-mal seizure, while coming back from work and was started on Phenytoin. Till the writing of this report it has been over 2 years since the operation and he has remained asymptomatic on 5 mg Prednisolone.

## Discussion

The original description of this disorder as a distinct clinicopathological entity was done by Churg and Strauss in 1949<sup>2,3</sup>. Since then, several reports of CSS have appeared in the literature. Although Lanham et al<sup>1</sup> reviewed 154 cases with CSS in 1984, this remains a rare disease.

Lanham et al noted 3 criteria for the diagnosis of CSS; asthma peak peripheral blood eosinophil count in excess of  $1.5 \times 10^9/L$  and the characteristic systemic vasculitis involving 2 or more extrapulmonary organs. The presentation of this syndrome is highly variable and its clinical manifestations are protean<sup>5</sup>. CSS can involve a number of organs including the cardiovascular, pulmonary, gastrointestinal, nervous, renal and musculoskeletal system<sup>6,7</sup>. Cardiac disease is recorded as the major cause of death in CSS. It can present as pericarditis, cardiac failure or merely an abnormal electrocardiogram. Pulmonary disease may manifest as infiltrates which are generally transient. Pulmonary hemorrhage is an important complication. Pleural effusion can occur and contains large amount of eosinophils. Renal disease occurs in the majority of the patients and is characterized by focal segmental glomerulonephritis, but renal failure is relatively uncommon. The usual lesion in CNS involvement is a mononeuritis multiplex, although a diffuse symmetric neuropathy can occur. Cerebral infarction, although rare is the second most common cause of death. Rash is a common feature, appearing as palpable purpura, erythema or urticaria. Arthritis or arthralgia may also be seen.

Our patient demonstrates several important features of CSS. He initially had adult onset of asthma and peripheral eosinophilia. Later on he had evidence of a systemic disease involving the joints, skin, central nervous system and gastrointestinal tract.

Gastrointestinal symptoms in CSS include abdominal pain, bloody stools, diarrhoea and nausea and vomiting. Although gastrointestinal symptoms are commonly seen, the literature contains few detailed descriptions of the gastrointestinal lesion<sup>2</sup>. The gastrointestinal tract may be involved in 20% of the patients with CSS and typically results in intestinal inflammation, ulceration, perforation or hemorrhage<sup>8</sup>.

In a review of 154 cases reported in the English literature, Lanham found abdominal pain as a common symptom (59% of all cases) which reflected bowel perforation, peritonitis, intestinal obstruction, mesenteric vasculitis or cholecystitis<sup>6</sup>. In a large series of 165 patients which included both Churg Strauss syndrome and Polyarteritis Nodosa patients<sup>9</sup>, 52 (31%) had abdominal signs and symptoms. The most severe episodes of abdominal pain were due to peritonitis (9 cases), duodenal ulcer (3 cases), intestinal infarction (1 case) and unexplained pain (1 case). while 11 patients presented with gastrointestinal hemorrhage. In the Japanese literature there have been 21 cases of lesions in the gastrointestinal tract in association with CSS. These lesions were in the form of multiple ulcers located in the stomach, small intestine and the colon. Twelve of these 21 cases presented as a gastrointestinal perforation. The small intestine was the most common site of involvement and the most frequently perforated. Most of the cases in the literature were not diagnosed until surgery or death<sup>2</sup>.

Other gastrointestinal manifestations of CSS reported in the literature are chronic active hepatitis, chronic ulcerative colitis<sup>10</sup>, intrahepatic duct perforation caused by hepatic aneurysm rupture<sup>11</sup> and a calculous cholecystitis<sup>12</sup>. Schoretsantis et al have recently reported a case of Churg-Strauss syndrome

where severe mesenteric intestinal ischemia lead to small bowel necrosis<sup>13</sup>. This patient underwent five laparotomies for resection of small bowel and survived.

The case that we have described fits most likely to the diagnosis of Churg Strauss Syndrome (CSS). Abdominal pain and intestinal ulceration and perforation are not rare. If physicians and surgeons keep this condition in mind and accurate and reliable histopathological reports are available, we have no doubt that more of such cases would be diagnosed. In tropical countries eosinophilia should not be labeled as only due to parasitic and allergic causes. Other less common causes like Churg Strauss syndrome and Polyarteritis Nodosa should also be considered.

## Acknowledgement

We are grateful to Mr. Sulaiman S. Gilani for his help in the preparation of this manuscript.

## References

1. Vogel, P.S., Nemer, J., Sau, P. et al. Churg Strauss syndrome J. Am. Acad. Dermatol.. 1992;5 822-824.
2. Shimamoto, C., Hirata, I., Ohshiba, S. et al. Churg-Strauss syndrome (allergic granulomatous angiitis) with peculiar multiple colonic ulcers. Am. J. Gastroenterol., 1990;55:316-19.
3. Schwartz, R.A. and Churg, J. Churg-Strauss syndrome. British J. Dermatol., 1992;127:199-204.
4. Lanham, J.O. Churg-Strauss syndrome. Br. J. Hosp. Med.. 1992;47:667-673.
5. Hasley, P.B., Follansbee, W.P. and Coulehan, J.L. Cardiac manifestations of Churg-Strauss syndrome: Report of a case and review of the literature. Am. Heart J., 1990;120:996-999.
6. Lanham, J.G., Elkon, K.B., Pusey, C.D. Systemic vasculitis with asthma and eosinophilia: A clinical approach to the Churg-Strauss syndrome. Medicine, 1984;63:2:65-81.
7. Chumbley, L.C., Harrison, E.G. and DeRemee, R.A. Allergic Granulomatosis and angiitis (Churg-Strauss syndrome), Mayo. Clin. Proc., 1977;52:477-484.
8. Camilleri, M., Pusey, C.D., Chadwick, V.S. et al. Gastrointestinal manifestation of systemic vasculitis. Q. J. Med., 1983; 141-149.
9. Guilleuin, L., Huong, D.L.T, Gorden, P. et al. Clinical findings and prognosis of polyarteritis nodosa and churg-strauss angitis: A study of 165 patients. Br. J. Rheumatol., 1988;27:258-264.
10. Finan, M.C. and Winkmann, R.K. The cutaneous extravascular necrotizing granuloma (Churg-Strauss Granuloma) and systemic disease: A review of 27 cases. Medicine, 1983;62: 3:142-157.
11. Imai, H., Nakamoto, Y., Nakajima, Y. et al. Allergic granulomatosis and angiitis (Churg-Strauss syndrome) presenting as a calculous cholecystitis. J. Rheumatol., 1990;17:247-9.
12. Nakamura, S., Yokoi, Y., Suzuki, S. et al. A case of melena caused by a hepatic aneurysm ruptured into the intrahepatic bile duct in a patient with allergic granulomatous angiitis. Jpn. J. Surg., 1991;21:471-475.
13. Schoretsanitis, G.N., Wakely, D.M., Maddox, T. et al. A case of Churg-Strauss vasculitis complicated by small bowel necrosis. Postgrad. Med. J., 1993;69:828-831.