



THE AGA KHAN UNIVERSITY

eCommons@AKU

---

Department of Medicine

Department of Medicine

---

July 2007

# Acute stroke secondary to internal carotid artery pseudoaneurysm: MRI findings and treatment with endovascularcoiling

Mohammad Wasay  
*Aga Khan University*

Alper Dai  
*Gaziantep University*

Neeraj Dubey  
*Dent Neurologic Institute*

Saadat Kamran  
*Hammad Medical Center*

Follow this and additional works at: [http://ecommons.aku.edu/pakistan\\_fhs\\_mc\\_med\\_med](http://ecommons.aku.edu/pakistan_fhs_mc_med_med)

 Part of the [Nervous System Diseases Commons](#), and the [Neurology Commons](#)

---

## Recommended Citation

Wasay, M., Dai, A., Dubey, N., Kamran, S. (2007). Acute stroke secondary to internal carotid artery pseudoaneurysm: MRI findings and treatment with endovascularcoiling. *Journal of Pakistan Medical Association*, 57(7), 377-378.

Available at: [http://ecommons.aku.edu/pakistan\\_fhs\\_mc\\_med\\_med/137](http://ecommons.aku.edu/pakistan_fhs_mc_med_med/137)

---

## **Case Report**

# **Acute stroke secondary to internal carotid artery pseudoaneurysm: MRI findings and treatment with endovascular coiling**

Mohammad Wasay<sup>1</sup>, Alper Dai<sup>2</sup>, Neeraj Dubey<sup>3</sup>, Saadat Kamran<sup>4</sup>

.The Aga Khan University<sup>1</sup>, Karachi, Gaziantep University, Gaziantep<sup>2</sup>, Turkey , Dent Neurologic Institute<sup>3</sup>, Buffalo, NY, USA, Hammad Medical Center<sup>4</sup>, Doha, Qatar

### **Abstract**

Internal carotid artery pseudoaneurysms are uncommon. We report a young man with history of trivial trauma who presented with middle cerebral artery stroke. Head CT scan revealed a right parapharyngeal mass. MRI confirmed the diagnosis of internal carotid pseudoaneurysm. Cerebral angiogram showed dissection of internal carotid artery with a large pseudoaneurysm and almost complete occlusion of vessel distal to aneurysm. Vessel was obliterated by fibercoiling and gluing by endovascular technique to diminish risk of further embolization. MRI characteristics of carotid pseudoaneurysms and role of endovascular treatment are discussed.

### **Introduction**

Internal carotid artery dissection and pseudoaneurysms are uncommon and are associated with high morbidity and mortality.<sup>1,2</sup> Thrombosis, embolism and rupture with haemorrhage are common complications.<sup>3,4</sup> Majority of cases have no history of trauma and may present as parapharyngeal or peri tonsillar mass.<sup>5</sup> Spontaneous resolution is uncommon among patients with pseudoaneurysm. Surgical treatment is controversial and is associated with major complications.<sup>6-8</sup> Endovascular

coiling and stenting has been used with success in selected patients.<sup>9</sup> We report a young man who presented with right middle cerebral artery embolic stroke due to an internal carotid artery pseudoaneurysm. As the vessel was almost completely occluded, proximal obliteration of vessel was obtained using fiber coils to diminish the risk of further embolism.

### **Case Report**

A 31 year old man with history of minor neck trauma six months ago, presented with acute stroke. Neurological examination revealed slurring of speech, left upper motor neuron facial paresis and left hemiparesis. General physical examination was unremarkable except swollen and protruded right pharyngeal tonsils. There were no redness, inflammation or exudates present involving tonsils. A retropharyngeal mass was suspected based on clinical examination. Non-contrast head CT scan in axial plane showed a well defined rounded mass involving right parapharyngeal space representing a large pseudoaneurysm of right internal carotid artery (Figure 1). The etiology of stroke was most likely embolic from partially thrombosed aneurysm. Cerebral angiogram showed dissection of internal carotid artery with a large pseudoaneurysm and almost complete occlusion of vessel distal to aneurysm (Figure 2). Vessel was obliterated by fibercoiling and gluing by

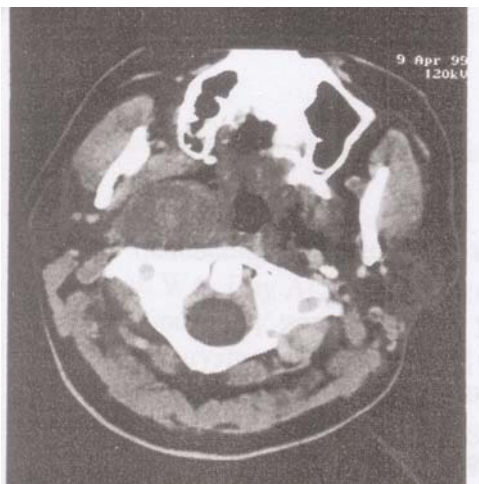


Figure 1. Non contrast head CT scan in axial plane showing well defined rounded mass involving right parapharyngeal space.

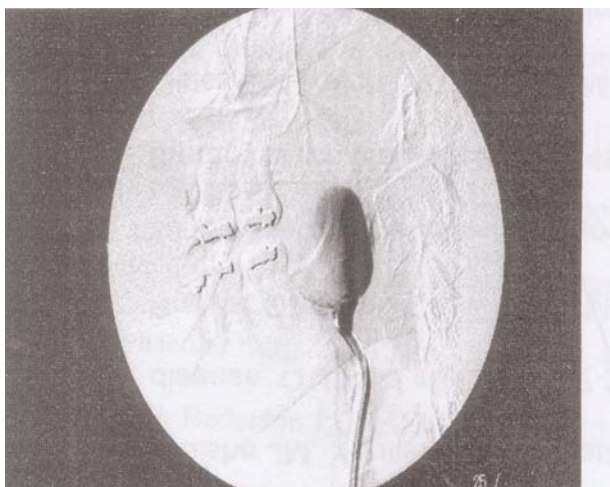


Figure 2. Right carotid angiogram in lateral projection showing partially thrombosed pseudoaneurysm.

endovascular technique to diminish risk of further embolization. We believe that pseudoaneurysm resulted from a clinically asymptomatic internal carotid artery dissection due to minor trauma as illustrated in history.

## Discussion

Stroke is a common complication of carotid artery dissection.<sup>1</sup> The mechanism underlying stroke is related to thrombosis, embolism or slow flow due to dissection. Time duration between dissection and stroke could range from immediately post dissection to years. Majority of these patients have history of neck trauma but patients with spontaneous dissection are increasingly recognized. Patients with carotid dissection can be divided into two groups depending on presence or absence of pseudoaneurysm.<sup>2</sup> Only a minority of these patients develop pseudoaneurysm.

Dissection between tunica media and adventitia is the underlying mechanism for pseudoaneurysm formation.<sup>3</sup> Spontaneous resolution is rare in patients with pseudoaneurysm due to carotid and vertebral artery dissection.

Diagnosis of possible carotid aneurysm was suggested due to a large parapharyngeal mass. MRI showed a well-defined mass measuring seven-centimeter superior inferiorly containing multiple layers of thrombus of different ages. These signal characteristics are highly suggestive of thrombosed aneurysm as compared to a parapharyngeal abscess or mass. MRI findings described above may be characteristic for carotid artery pseudoaneurysm. These findings may be helpful in differential diagnosis of a pharyngeal mass. The diagnosis could be suggested on routine CT and MRI examination. Recent reports have showed utility of Helical CT angiography and contrast-enhanced MR Angiography in the diagnosis of carotid dissection and pseudoaneurysm.<sup>10</sup>

In conclusion, carotid pseudoaneurysm could present as acute stroke. The diagnosis could be established based on routine CT and MRI. Endovascular and gluing are effective and safe in obliterating pseudoaneurysm. Due to high complication rate of surgery in these cases endovascular treatment may be a good alternative. Alternate endovascular procedures used to treat this condition include, stenting and stent supported coiling of pseudoaneurysm.

## References

1. Gonzales-Portillo F, Bruno A, Biller J. Outcome of extracranial cervicocephalic arterial dissections: a follow-up study. *Neurol Res.* 2002;24:395-8.
2. Friedman WA, Day AL, Quisling RG, Sybert GW, Rhoton AL. Cervical carotid dissecting aneurysms. *Neurosurgery.* 1980;7:207-14.
3. Goldstein LB, Gray L, Hulette CM. Stroke due to recurrent ipsilateral carotid artery dissection in a young adult. *Stroke.* 1995;26:480-3.
4. Tanaka S, Kimura Y, Furukawa M. Pseudoaneurysm of the carotid artery with haemorrhage into the hypopharynx. *J Laryngol Otol.* 1995;109:889-91.
5. Thomas JA, Ware TM, Counselman FL. Internal carotid artery pseudoaneurysm masquerading as a peritonsillar abscess. *J Emerg Med.* 2002;22:257-61.
6. El-Sabroun R, Cooley DA. Extracranial carotid artery aneurysms: Texas Heart Institute experience. *J Vasc Surg.* 2000;31:702-12.
7. Yamashita T, Higami T, Shida T. Surgical correction of pseudoaneurysm of the extracranial carotid artery: the usefulness of retrograde cerebral perfusion—a case report. *Vasc Endovascular Surg.* 2003;37:445-8.
8. Catalano PJ, Bederson J, Turk JB, Sen C, Biller HF. New approach for operative management of vascular lesions of the infratemporal internal carotid artery. *Am J Otol.* 1994;15:495-501.
9. Delgado F, Bravo-Rodriguez FA, Bautista MD, Chiroso MA, Molina T, Martos JM, et al. Carotid pseudoaneurysms secondary to dissection: endovascular management with bare stent-graft. *Cerebrovasc Dis.* 2005;19:136-8.
10. Phan T, Huston J, Bernstein MA, Riederer SJ, Brown RD. Contrast-enhanced magnetic resonance angiography of the cervical vessels: experience with 422 patients. *Stroke.* 2001;32:2282-6.