



THE AGA KHAN UNIVERSITY

eCommons@AKU

Medical College Documents

Medical College, Pakistan

July 2012

Melanotic Neuroectodermal Tumour of Infancy: A Rare Brain Tumour of Childhood

Muhammad Babar Khan

Aga Khan University

Delvene Soares

Ziauddin University

Muhammad Zubair Tahir

Aga Khan University

Rajesh Kumar

Aga Khan University

Khurram Minhas

Aga Khan University

See next page for additional authors

Follow this and additional works at: http://ecommons.aku.edu/pakistan_fhs_mc_mc



Part of the [Neurology Commons](#)

Recommended Citation

Khan, M. B., Soares, D., Tahir, M. Z., Kumar, R., Minhas, K., Bari, M. E. (2012). Melanotic Neuroectodermal Tumour of Infancy: A Rare Brain Tumour of Childhood. *Journal of the College of Physicians and Surgeons Pakistan*, 23(5), 367-369.

Available at: http://ecommons.aku.edu/pakistan_fhs_mc_mc/24

Authors

Muhammad Babar Khan, Delvene Soares, Muhammad Zubair Tahir, Rajesh Kumar, Khurram Minhas, and Muhammad Ehsan Bari

Melanotic Neuroectodermal Tumour of Infancy: A Rare Brain Tumour of Childhood

Muhammad Babar Khan³, Delvene Soares⁴, Muhammad Zubair Tahir¹, Rajesh Kumar¹,
Khurram Minhas² and Muhammad Ehsan Bari¹

ABSTRACT

Melanotic neuroectodermal tumour of infancy is a rare, mostly benign but locally aggressive tumour of neural crest cell origin occurring in infants. The most commonly affected anatomic site is the maxilla. Such tumours of the brain and skull are very rare. We present the case of an 8 months old baby girl whose presenting complaint was a swelling in the scalp for 6 months. She was otherwise asymptomatic. CT imaging confirmed the presence of an osteolytic tumour in the anterior parasagittal skull with dural involvement. The tumour was surgically excised *enbloc*. The patient has been well at 2 years follow-up without any evidence of recurrence.

Key words: *Melanotic neuroectodermal tumour. Scalp swelling. Enbloc tumour excision. Vanillylmandelic acid. Osteolytic pigmented lesion. GFAP stain.*

INTRODUCTION

Melanotic neuroectodermal tumour of infancy (MNTI) was first described by Krompecher in 1918. However, it was named several years later in 1966, by Borello and Gorlin, after they reported a case with elevated urinary levels of VMA suggesting a neural crest origin.^{1,2} Melanotic neuroectodermal tumour of infancy (MNTI) is a rare, osteolytic pigmented lesion of neural crest origin, occurring in infants.³ Majority of cases have been reported in the maxilla, with the skull and the brain being less common locations. Very rarely MNTI can also be found in the epididymis, mediastinum and the female reproductive organs.² Although melanotic neuroectodermal tumour of infancy is mostly benign, a malignancy rate of 6.6% has been reported.² The majority of cases occur within the first year of life without any gender predilection.^{1,2,4,5}

MNTI often presents as a swiftly growing mass resulting in skull deformation.⁴ The recurrence rates after resections have been reported from 10% to as high as 60%.^{2,5} Here, we present the first case of MNTI from Pakistan.

CASE REPORT

An 8 months old female presented with a swelling on the scalp for the last 6 months. The swelling appeared gradually and was progressive. There was no history of

trauma, fever, weight loss, vomiting or seizures. She had otherwise normal growth and development milestones. On examination, the lesion was a 5 x 6 cm midline swelling which was non-tender and firm. The overlying skin was mobile but the lesion was attached to the underlying structures. The lesion was located in the anterior parasagittal skull with dural involvement. A CT scan was carried out which showed an iso- to hypodense lesion with reactionary bony enlargement, compressing the superior sagittal sinus (Figure 1). An excision biopsy was performed which showed a right frontal lesion that was firm in consistency, grayish in colour and avascular. There was involvement of the subgaleal tissue, pericranium, bone and dura mater. The lesion was removed *enbloc* along with involved dura mater. There was no brain parenchymal involvement. Duraplasty was performed using normal pericranium and a cranioplasty was carried out using bone cement.

Histopathology reports finally confirmed it to be a melanotic neuroectodermal tumour of infancy. Sections examined showed a lesion composed of variable sized tubule-like structures and nests of small cells. Tubule-like structures were composed of flattened to polygonal melanin pigment containing cells. Nuclei were small and exhibit evenly dispersed chromatin pattern. Within the luminal spaces, small euplastic cell aggregates were seen with a central fibrillary background imparting a rosette like architecture. These tubules and nests of cells were scattered in a fibrous stroma with variable sized blood vessels. In some areas, loosely arranged small neoplastic cells with a fibrillary background were seen in the fibrotic stroma (Figure 2 and 3).

On follow-up at 3 months, the child was asymptomatic, her urinary VMA levels were within normal limits and she had fully recovered. The child was followed-up for 2 years and there was no recurrence of tumour or clinical symptoms.

¹ Department of Neurosurgery / Pathology², The Aga Khan University Hospital, Karachi.

³ Medical Student, The Aga Khan University, Karachi.

⁴ Medical Student, Ziauddin University, Karachi.

Correspondence: Dr. Muhammad Ehsan Bari, Department of Neurosurgery, The Aga Khan University Hospital, Karachi.

E-mail: ehsan.bari@aku.edu

Received January 02, 2012; accepted July 31, 2012.

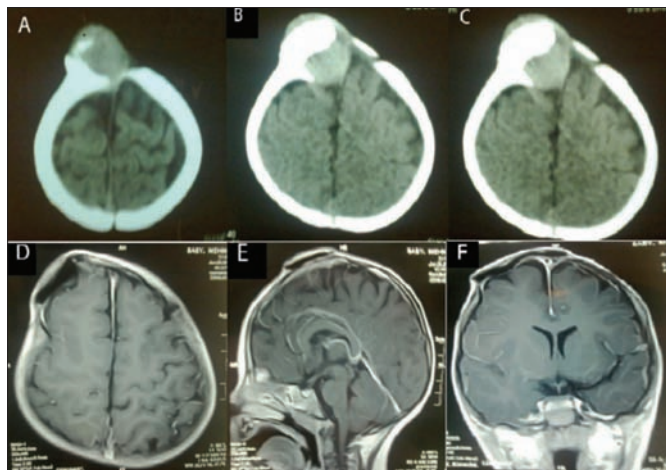


Figure 1: A,B,C: Pre-operative CT scans of the patient showing an iso to hypo dense lesion with reactionary bony enlargement, and which was compressing the superior sagittal sinus. D,E,F: Postoperative contrast enhanced T1 images showing complete tumour excision without recurrence.

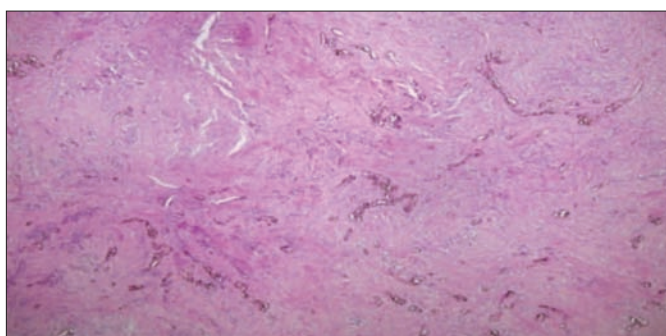


Figure 2: Low power view (2X); Alveolar nests and tubules of cells separated by fibrous stroma.

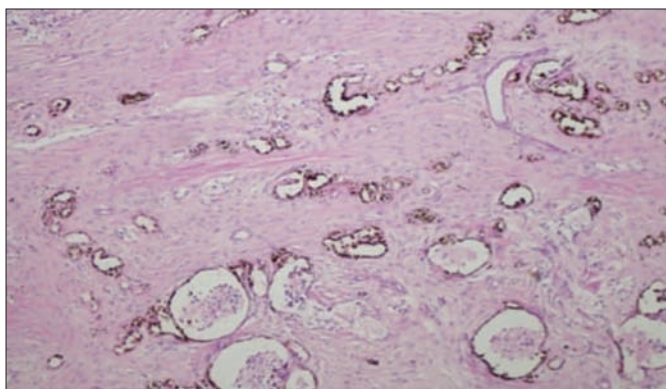


Figure 3: Low power view (4X) Tubules are populated by two cell types: a peripheral layer of melanin-pigmented large cells surrounding groups of small neuroblastic type cells.

DISCUSSION

Most MNTI lesions occur in the maxilla, with skull and brain involvement being quite rare (Figure 4).² Primary tumours originating from the brain itself are even rarer and very few cases have been reported involving the cerebellar vermis and the third ventricle.⁶

Signs of anaplasia such as mitoses and pleomorphism are not evident in MNTI. Under a light microscope, three

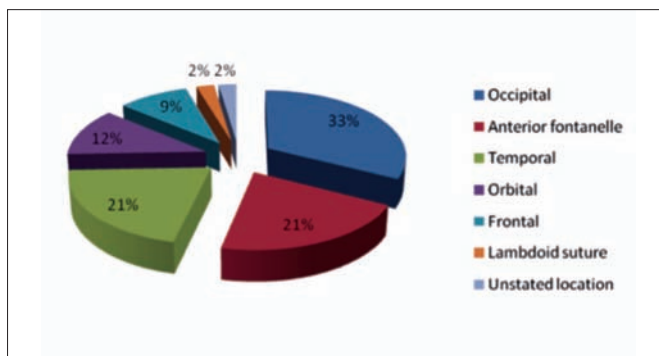


Figure 4: Distribution of reported cranial MNTI from 1977 to 2008. Total number (n = 43).

different kinds of cells can be appreciated. The first resemble epithelial cells are large with abundant cytoplasm, have many vacuoles and a large ovoid sharply marginated nucleus. The second cell type has a hyper chromatic nucleus with a non-pigmented cytoplasm and is small and immature while the third type of cells are small, stellate and resemble fibroblasts.⁴ The tumour cells are divided into clusters with slit like alveoli which are irregular in size and shape.⁴

The lesion may be mistaken as malignant due to its rapid growth rate, therefore, careful workup especially that of histopathology is advocated before a final diagnosis is reached. Various studies show that the MNTI is a congenital dysembryogenetic neoplasm arising out of neural crest cells.¹ Like other tumours of neural crest origin, MNTI secretes VMA and other catecholamines, the levels of which go down after complete tumour excision.⁷ MNTI also expresses melanotransferrin which further supports its neuroectodermal origin.¹

However, VMA is not diagnostic as many patients have also shown normal urinary VMA levels.⁸ This is probably because not all the cells of neural crest origin are involved in the metabolism of catecholamines.⁸ Immunocytochemistry is also of help. The smaller hyper chromatic neuroblast-like cells are usually positive for neuron-specific enolase, glial fibrillary acidic protein, and synaptophysin; while the larger epithelioid cells may be positive for vimentin, cytokeratin, epithelial membrane antigen, neuron-specific enolase, glial fibrillary acidic protein, synaptophysin, Leu 7, and HMB45.¹ S-100 protein, alpha fetoprotein and neurofilament are usually non-reactive.¹ This can help differentiate MNTI from other PNETs (Primitive Neuro Ectodermal Tumours). Neoplastic cells with poly-phenotypic expression of neural, melanocytic and neural markers exhibit no photo-receptor or myogenic differentiation.¹

Clinical differentials are broad but MNTI must be distinguished from Ewing's sarcoma, rhabdomyosarcoma, peripheral neuroepithelioma, neuroblastoma, desmoplastic round cell tumour, leukemia, malignant melanoma, and infections or cephalohematomas.^{1,2,9}

MNTI can be differentiated from Ewing's sarcoma, peripheral neuroepithelioma, desmoplastic round cell tumour, leukemia and infections or cephalohematomas as it has biphasic neoplastic population and a polyphenotypic immunohistochemical expression.⁷ The lack of S-100 reactivity coupled with lack of neuroendocrine differentiation markers, myo D-1, myoglobin, myogenin and muscle specific Actin reactivity can differentiate MNTI from cellular blue nevus, melanoma, neuroblastoma and rhabdomyosarcoma.¹

In the course of the disease, a well demarcated osteolytic radiolucency is found which may have regular or irregular borders. A well grown MNTI can cause displacement of the surrounding tissues and damage the bone as well.⁶ However, these changes may not be apparent if the conventional radiographs are done early. MR angiography can prove particularly useful in midline tumours that have invaded the dural sinuses as it can best demonstrate the adherence of tumour to the sinuses.^{2,4} The boundaries of the tumour are well demarcated on CT scan and serve as good guides for surgical excision.² The tumour appears hyper to iso intense on T1 weighted images and exhibits homogeneous enhancement after a gadolinium contrast, while on T2 weighted images it appears hypo intense.⁶ However, the peripheral margins of the tumour in direct apposition to bone may appear hypo intense on T1 weighted images.⁶ A pre-operative cytological diagnosis of MNTI through aspirates from the site of the lesion is possible.⁴

The MNTI is a locally aggressive tumour. After a complete surgical resection, the chances of recurrence are reported between 10% to 20%.⁵ The probability of the tumour becoming malignant is 6.5%.⁵ Most recurrences after complete resection occur within 4 weeks; there was one exception where the tumour recurred after being in remission for 12 years.⁵ Incomplete surgical resections have recurrence rates as high as 60%.^{2,5,10} At present, there is no effective adjuvant therapy for recurrent and residual tumour.³ A complete surgical resection wherever possible, offers a definitive cure for the vast majority of the patients. Surgical outcomes are better if the tumour is in a favourable location. Tumours along the midline or cranial base and those adherent to dural sinuses or tumours with significant intracranial extensions are difficult to manipulate surgically and a complete excision may not be possible.⁴ Furthermore, the use of operating microscope ensures the complete resection of tumour when it is in a favourable location; missed parts of the

tumour may cause recurrence. Complete *en bloc* excision reduces the anaesthetic risks and undue manipulation of the lesion which occurs during a prior biopsy. It has been reported that the tumour grows more aggressively along the site of a previous biopsy.¹ Recurrence may also occur because of inadvertent seeding during the excision surgery.

It is also noteworthy that the biological behaviour of the MNTI, such as local growth rate and the possibility of metastasis cannot be judged adequately from either clinical or histological features.⁵ Patient's family should be informed of all these variables in treatment. The child should be followed-up till adulthood so that surgical complications and recurrences can be picked up early and managed accordingly allowing the child to reach normal growth and development milestones.

REFERENCES

1. Gaiger de Oliveira M, Thompson LD, Chaves AC, Rados PV, da Silva Lauxen I, Filho MS. Management of melanotic neuroectodermal tumour of infancy. *Ann Diagn Pathol* 2004; **8**:207-12.
2. Lambropoulos V, Neofytou A, Sfougaris D, Mouravas V, Petropoulos A. Melanotic neuroectodermal tumour of infancy (MNT1) arising in the skull: short review of two cases. *Acta Neurochirurgica* 2009; **152**:869-75.
3. Agarwal P, Agarwal V, Raina VK. Melanotic neuroectodermal tumour of infancy: case report of an unusual tumour. *Indian J Plastic Surg* 2003; **36**:2.
4. Antunes ACM, Freitas RM, Oliveira PP, Rebouças RG. Melanotic neuroectodermal tumour of infancy: case report. *Arq Neuropsiquiatr* 2005; **63**:670-2.
5. Omodaka S, Saito R, Kawagishi TKJ, Jokura H, Sonoda Y, Watanabe M, *et al*. Melanotic neuroectodermal tumour of the brain recurring 12 years after complete remission: case report. *Brain Tumor Pathol* 2010; **27**:51-7.
6. George JC, Edwards MK, Jakacki RI, Kho-Duffin J. Melanotic neuroectodermal tumour of infancy. *AJNR Am J Neuroradiol* 1995; **16**:1273-5.
7. Kapadia SB, Frisman DM, Hitchcock CL, Ellis GL, Popek EJ. Melanotic neuroectodermal tumour of infancy; clinical, immunohistochemical, and flow cytometric study. *Am J Surg Pathol* 1993; **17**:566-73.
8. Madrid C, Aziza J, Hlali A, Bouferrache K, Abarca M. Melanotic neuroectodermal tumour of infancy: a case report and review of the aetiopathogenic hypotheses. *Med Oral Patol Oral Cir Bucal* 2010; **15**:e739-42.
9. Hoshino S, Takahashi H, Shimura T, Nakazawa S, Naito Z, Asano G. Melanotic neuroectodermal tumour of infancy in the skull associated with high serum levels of catecholamine. *J Neurosurg* 1994; **80**:919-24.
10. Woessmann W, Neugebauer M, Gossen R, Blütters-Sawatzki R, Reiter A. successful chemotherapy for melanotic neuroectodermal tumour of infancy in a baby. *Med Pediatr Oncol* 2003; **40**:198-9.

