



THE AGA KHAN UNIVERSITY

eCommons@AKU

---

Section of Otolaryngology, Head & Neck Surgery

Department of Surgery

---

May 2011

# Extracranial Meningioma: an Unusual Presentation of a Mass Over Inner Canthus of Left Eye

Nasir Ali  
*Aga Khan University*

Mubasher Ikram  
*Aga Khan University*

Tahir Shafi Khan  
*Aga Khan University*

Syed Athar Enam  
*Aga Khan University*

Abdul Qadir Jangda  
*Aga Khan University*

*See next page for additional authors*

Follow this and additional works at: [http://ecommons.aku.edu/pakistan\\_fhs\\_mc\\_surg\\_otolaryngol\\_head\\_neck](http://ecommons.aku.edu/pakistan_fhs_mc_surg_otolaryngol_head_neck)

 Part of the [Otolaryngology Commons](#), and the [Radiology Commons](#)

---

## Recommended Citation

Ali, N., Ikram, M., Khan, T. S., Enam, S. A., Jangda, A. Q., Karsan, F. (2011). Extracranial Meningioma: an Unusual Presentation of a Mass Over Inner Canthus of Left Eye. *Journal of The College of Physicians and Surgeons Pakistan*, 21(5), 309-10.

**Available at:** [http://ecommons.aku.edu/pakistan\\_fhs\\_mc\\_surg\\_otolaryngol\\_head\\_neck/51](http://ecommons.aku.edu/pakistan_fhs_mc_surg_otolaryngol_head_neck/51)

---

**Authors**

Nasir Ali, Mubasher Ikram, Tahir Shafi Khan, Syed Athar Enam, Abdul Qadir Jangda, and Farrok Karsan

# Extracranial Meningioma: an Unusual Presentation of a Mass Over Inner Canthus of Left Eye

Nasir Ali<sup>1</sup>, Mubasher Ikram<sup>2</sup>, Tahir Shafi Khan<sup>2</sup>, Syed Athar Enam<sup>3</sup>, Abdul Qadir Jangda<sup>1</sup> and Farrok Karsan<sup>1</sup>

## ABSTRACT

Meningiomas are commonly encountered as intracranial brain tumours, but extracranial meningiomas do occur although seen rarely. Here we present a case of extracranial meningioma presenting as a mass over the medial canthus of left eye and the glabella with extension into the left ethmoid sinuses, without any neurological symptoms or signs. The patient underwent surgical excision, plastic surgical reconstruction and adjuvant radiotherapy after 3-dimensional conformal treatment planning.

**Key words:** *Extracranial meningioma. Ethmoid sinus meningioma. Orbital meningioma. Medial canthus mass.*

## INTRODUCTION

Meningioma is a well recognized tumour of the central nervous system. Its incidence as intracranial disease is approximately 15-20%, but the primary extracranial meningioma is exceedingly rare, accounting for only 2% or less which can extend into the paranasal sinuses.<sup>1</sup> Intracranial meningiomas arise from arachnoid meninges of the brain, present with neurological symptoms and signs, and typical locations include the cerebral convexities, falx cerebri, tentorium cerebelli, cerebellopontine angle and sphenoid ridge. Intracranial meningiomas are not strictly brain tumours, since they arise from arachnoid cap cells that form the external membranes of the brain. However, since they grow inside the intracranial cavity and are followed by neurological symptoms and signs, they are usually classified as brain tumours. Grossly meningiomas are well circumscribed, firm, tan or grayish lesions; hyperostosis of adjacent bone may be present.<sup>2</sup> They usually occur at an average age of 40-60 years.

Unusual extracranial locations are on forehead, neck and forearm etc. We report an interesting case of an extracranial meningioma which presented as a swelling over the medial canthus of left eye, left supra orbital ridge and over bridge of nose also causing proptosis without any neurological symptoms and signs.

## CASE REPORT

A 60 years old man presented with swelling on the left periorbital region for 2 years. During the previous one year he was operated twice outside our centre. This was

a second recurrence when he presented. Clinically this was a hyperemic mass at the medial canthus of left eye and extending over the glabella (Figure 1). CT scan of head and neck showed a lesion involving predominantly the left side of the nose measuring approximately 7 x 5 cm extending into the left orbit causing destruction and remodeling of the lamina papyracea and into the frontal and ethmoid sinuses on left side. Defect was also identified in the fovea ethmoidalis with a possible intracranial extension on the left side. It was biopsied and histopathology was consistent with meningioma, grade I, according to WHO classification of CNS neoplasms. A panel of immunohistochemical staining was performed to confirm the diagnosis, cytokeratin (AE1/AE3), S 100, HMB 45 was negative and EMA was positive.

MRI brain ruled out any intracranial connection, however, there was proptosis of the left eye with involvement of the left medial rectus muscle. A team of surgeons comprising of ENT, neurosurgery and plastic surgery operated on him. He underwent wide local excision and plastic surgical reconstruction, with acceptably good cosmesis.

Histological examination including immunohisto-chemistry confirmed the diagnosis of meningioma. The frozen section examination showed close margins on medial canthus of eye and scalp and the frontal and ethmoid sinuses were involved.

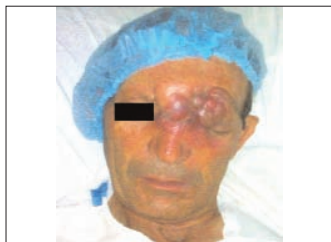On account of high risk of local recurrence he was offered adjuvant radiotherapy after 3-dimensional conformal radiation treatment planning (Figure 2) to receive 45 Gy dose @ 1.80 Gy/ fraction on 6 mega voltage energy on linear accelerator, followed by a boost of 09 Gy over five fractions to the areas of positive margins (the medial canthus of left eye and frontal and ethmoid sinuses) to a total radiation dose of 54 Gy. He completed scheduled treatment in September 2008 and is free of local recurrence at 2 years follow-up.

*Department of Radiation Oncology<sup>1</sup>/Surgery<sup>2</sup>/Neurosurgery<sup>3</sup>,  
The Aga Khan University Hospital, Karachi.*

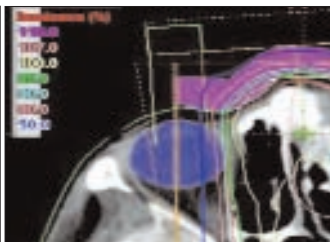
**Correspondence:** *Dr. Nasir Ali, A-5, Al-Mustafa Square,  
Block 14, Gulshan-e-Iqbal, Karachi.*

*E-mail: nasir.ali@aku.edu*

*Received January 21, 2009; accepted March 12, 2011.*



**Figure 1:** Hyperemic mass at medial canthus of left eye and over glabella, pre-operative photograph.



**Figure 2:** Radiotherapy 3-D CT planning photograph showing isode lines covering planning treatment volume.

## DISCUSSION

Intracranial meningiomas are the most common adult benign intracranial neoplasms, whereas extracranial meningiomas are rare tumours comprising 1-2% of all meningiomas. The morphological features of extracranial meningiomas are similar to intracranial counterparts.<sup>3</sup>

The prognosis of meningiomas is generally favourable. However, in rare cases meningiomas are aggressive and can occur as a malignant meningioma. Arndt *et al.* described a case of a papillary meningioma as an aggressive histological variant, which accounts for 1.0-2.5% of all meningiomas.<sup>4</sup> Extracranial sinonasal tract meningiomas often demonstrate an erosion of the sinus wall, with extension to the surrounding soft tissue, to the orbit and occasionally to the skull base<sup>5</sup>, as was seen in this patient who presented with a soft tissue mass on the medial canthus of left orbit.

Complete surgical excision of sinonasal meningioma is the treatment of choice without the need for adjuvant treatment.<sup>6</sup> Relapses are possible in case of incomplete removal of the primary lesion; this patient had undergone excision twice and presented to us with second recurrence. The prognosis of extracranial meningioma is always good if the excision is complete.<sup>3</sup> The CT scan and MRI are the investigations of choice to

see any intracranial connection or origin of the tumour,<sup>7</sup> and the differential diagnosis of extracranial meningiomas located in the nasal sinus region can include mucocele, sinonasal carcinoma and hemangioma.<sup>8</sup>

The treatment of choice is the surgical resection and adjuvant treatment is reserved for incomplete excisions and the positive margins. In the case being presented, patient was offered adjuvant radiation therapy because it was a recurrent disease and extending to frontal and ethmoid sinuses and surgical pathology report showed close margins at two sites.

## REFERENCES

1. Jovanovic MB, Berisavac I, Perovic JV, Grubor A, Milenkovic S. Huge extracranial asymptomatic frontal invasive meningioma: a case report. *Eur Arch Otorhinolaryngol* 2006; **263**:223-7. Epub 2005 Jul 14.
2. Perez CA, Brady LW, editors. Principles and practice of radiation oncology. 4th ed. Philadelphia: Lippincott Williams & Wilkins; 2003.
3. Murata H, Takahashi M, Takagi T, Katagiri H, Ito I, Ishida T. A case of primary extracranial meningioma of the forearm with bone invasion. *Skeletal Radiol* 2007; **36**:551-3. Epub 2007 Mar 7.
4. Arndt S, Wiech T, Mader I, Aschendorff A, Maier W. Rare extracranial localization of primary intracranial neoplasm. *Diagn Pathol* 2008; **3**:14.
5. Kainuma K, Takumi Y, Uehara T, Usami S. Meningioma of the paranasal sinus: a case report. *Auris Nasus Larynx* 2007; **34**: 397-400. Epub 2007 Feb 7.
6. Gökdoğan CA, Iplikcioglu AC, Kuzdere M, Bek S, Cosar M. Primary meningioma of the paranasal sinus. *J Clin Neurosci* 2005; **12**:832-4.
7. Saloner D, Uzelac A, Hetts S, Martin A, Dillon W. Modern meningioma imaging techniques. *J Neurooncol* 2010; **99**:333-40. Epub 2010 Sep 1.
8. Thompson LD, Gyure KA. Extracranial sinonasal tract meningiomas: a clinicopathologic study of 30 cases with a review of the literature. *Am J Surg Pathol* 2000; **24**:640-50.

.....★.....