



THE AGA KHAN UNIVERSITY

eCommons@AKU

Section of Otolaryngology, Head & Neck Surgery

Department of Surgery

July 2013

Toluidine blue: Yet another low cost method for screening oral cavity tumour margins in Third World countries

Montasir Junaid

Jinnah Medical College Hospital

Anwar Suhail

Aga Khan University

Beena Umer

Aga Khan University

Mubasher Ikram

Aga Khan University

Zain-ul-Abideen Sobani

Aga Khan University

See next page for additional authors

Follow this and additional works at: http://ecommons.aku.edu/pakistan_fhs_mc_surg_otolaryngol_head_neck

 Part of the [Otolaryngology Commons](#)

Recommended Citation

Junaid, M., Suhail, A., Umer, B., Ikram, M., Sobani, Z., Ali, N. S., Nawaz, A. (2013). Toluidine blue: Yet another low cost method for screening oral cavity tumour margins in Third World countries. *Journal of the Pakistan Medical Association*, 63(7), 835-837.

Available at: http://ecommons.aku.edu/pakistan_fhs_mc_surg_otolaryngol_head_neck/47

Authors

Montasir Junaid, Anwar Suhail, Beena Umer, Mubasher Ikram, Zain-ul-Abideen Sobani, Naeem Sultan Ali, and Ahmad Nawaz

Toluidine blue: Yet another low cost method for screening oral cavity tumour margins in Third World countries

Montasir Junaid,¹ Anwar Suhail,² Beena Umer,³ Ahmad Nawaz,⁴ Mubasher Ikram,⁵ Zain-ul-Abideen Sobani,⁶ Naeem Sultan Ali⁷

Abstract

Objective: To use toluidine blue intra-operatively to identify tumour involved margins after the removal of oral cavity squamous cell carcinoma, and to compare the findings with those of final histopathology.

Methods: The study was conducted at the Aga Khan University Hospital from December 1, 2009, to March 14, 2010, and comprised 56 consecutive patients with biopsy-proven squamous cell carcinoma of oral cavity regardless of grade and stage of tumour. Intra-operatively toluidine blue was used on the resected tumour margins and the staining patterns were assessed. Results were then compared with the final histopathology report.

Results: A total of 11 (19.64%) margins were positive with toluidine blue staining out of which 8 (14.28%) were false positive. Sensitivity and specificity was found to be 100% and 84.9% respectively with a positive predictive value of 27.2%; a negative predictive value of 100%; and diagnostic accuracy of 85.71%.

Conclusion: Toluidine blue costs only Rs25 (USD 0.30) and takes only 5 minutes for application and interpretation. It can be used with significant confidence in smaller lesions (T-I and T-II) as an alternative to frozen sections in developing countries where facilities are unavailable. Its use in larger lesions (T-III and T-IV) remains the topic of controversy and awaits a multi centre trial with a larger cohort.

Keywords: Toluidine blue, Sensitivity and Specificity, Staining, Pathology. (JPMA 63: 835; 2013)

Introduction

Oral cancer with a global incidence of 10 million cases in the year 2000 is among the most frequent head and neck malignancies. Further, this figure is expected to rise to about 15 million in 2020.¹ Due to cultural practices, a majority of these patients reside in developing countries, especially Southeast Asia. Karachi south ranks highest in terms of age-standardised ratio for oral cancers in both men and women.²

With the primary management for oral cancer being surgical excision, the importance of intra-operative tumour-free margins need not be emphasised. Given the high burden of disease, a quick, safe and economical intra-operative method to confirm the presence of residual disease is of essence. Different techniques have been used to identify the status of tumour margins intra-operatively. The most commonly used method is a frozen-section biopsy of the margins due to its high sensitivity (86.6, 88.8%) and specificity (99.6, 98.9%).^{3,4} However, given the relative developing status of our health-care system, it is not available in a majority of centres. Where available, the service costing around Rs 6500 (USD-75) for 5 margins is out of the financial reach for a majority of patients.

Considering this dilemma, the current study set out to find a cost-effective alternative for the intra-operative assessment of tumour margins. One such method involves the use of supravital stains, such as toluidine blue (toluinium chloride). The dye, due to its inherent affinity for nucleic acids, stains the tumour cells strongly.⁵ Further, it has been demonstrated to stain malignant and pre-malignant lesions of the oral cavity. However, results have been diverse.⁶⁻⁸ Given this we decided to study the application of toluidine for the assessment of intra-operative tumour margins in oral cavity squamous cell carcinoma (OCSCC).

Patients and Methods

After approval from the ethics review committee, a prospective, cross-sectional study was carried out on 56 consecutive + 2 pilot patients with biopsy-proven OCSCC at the Aga Khan University Hospital, Karachi. Consenting patients undergoing surgical excision were recruited without any prerequisite criteria between December 1, 2009, and March 14, 2010. The patients were included in the study regardless of age, gender, stage and grade of tumour. However, patients with a history of previous oral cavity surgery and/or radiation therapy were excluded as increased inflammation and scar tissue lead to errors while interpreting the results.

During this period, 2 experienced head and neck surgeons performed the procedures with assistance from senior residents. Primary tumour resection varied on an individual

¹Jinnah Medical College Hospital, ^{2,3,5-7}Aga Khan University Hospital, ⁴Dar-ul-Sehat Hospital, Karachi, Pakistan.

Correspondence: Montasir Junaid. Email: doc_montsj@yahoo.com

basis with a focus on excision of the tumour with safe margins. The primary excision was followed by a neck dissection, the extent of which was defined by the patient's disease. The operative protocol was essentially the same with negligible differences due to the attending surgeon's preference. All tumours were stained as per the given protocol and no deviations were made due to the location or extent of disease. One senior resident was assigned the responsibility for this procedure in all patients. The senior resident recorded his findings in a log and was blinded from the final results of the histopathology. Once the margins were painted and log noted, regular-frozen section biopsies were taken by the primary surgeon as per the institutional policy and ethical constraints. In addition, if any margin stained positive with toluidine blue, the primary surgeon was requested to take a frozen-section biopsy from the area. After the resection of primary tumour and frozen biopsies, the specimens were sent to the histopathology lab within 10 mins. The histopathologist was also blinded to the findings of the log; However, it is possible that the staining may have persisted after processing, influencing the decision of the histopathologist. Post-operatively, all the cases were discussed in weekly tumour board meetings where further treatment with radiation or chemotherapy was decided on an individual basis.

After the primary tumour was excised, the tumour margins were irrigated with normal saline, followed by 1% acetic acid and gently dried with gauze. The margins were then painted with 1% toluidine blue solution, prepared as described in literature,⁵ with a cotton swab and left in place for 30 seconds (Figure). This was subsequently followed by irrigation with normal saline and 1% acetic acid. The margins were gently dried and the staining patterns observed by the senior resident independently. Margins which stained dark blue were considered to be positive, whereas those which stained light blue or did not take the stain at all were considered negative. In order to establish staining patterns, we used simultaneous frozen sections in our 2 pilot patients and revealed the results to the interpreter during the surgery. No bony margin was stained due to the inherent property of the dye to stain mucosa only.

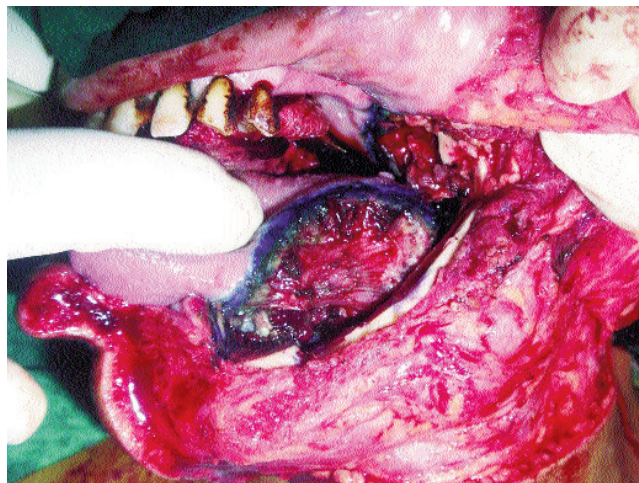
Hence, we also compared the histopathology of the

surgical specimens with the peri-operative toluidine blue results and evaluated the sensitivity, specificity, positive predictive value (PPV), negative predictive value (NPV), and overall accuracy of toluidine blue staining to differentiate between positive and negative tumour margins.

Results

Fifty six consenting patients were enrolled in the study, of which 42 (75%) were male and 14 (25%) were female with an average age of 50.07 ± 15.73 years. The most common site of the lesion was the buccal mucosa 23 (41%), followed by tongue 13 (23.2%), lower alveolus 7 (12.5%), retro-molar trigone 5 (8.95%), upper alveolus 5 (8.95%), and floor of the mouth 3 (5.3%). Of these, 11 (19.6%) were staged as T-I lesions, whereas 19 (33.9%) were T-II, 11 (19.6%) were T-III and 15 (26.7%) were T-IV lesions (Table-1).

The log showed 11 (19.56%) positive margins taking up the toluidine blue stain. In these cases further excision of stained margin was done to achieve clear margins intra-operatively. Of the 11 positive margins on toluidine blue staining, 3 (5.37%) were found to be positive on final histopathology, and false positives were reported for 8 (14.28%) margins. None of the negative margins were reported as positive on the final histopathology report (Table-2). The test, as such, had sensitivity of 100% and



Figures: Toluidine blue applied to tumour resected margin.

Table-1: Site-specific T staging.

T-Staging	Buccal mucosa	Tongue	Retromolar trigone	Lower alveolus	Upper alveolus	Floor of mouth	Total
T-I	3	4	2	1	1	0	11
T-II	6	5	2	1	3	2	19
T-III	4	3	1	2	0	1	11
T-IV	10	1	0	3	1	0	15
Total	23	13	5	7	5	3	56

Table-2: Comparison of toluidine blue results with final histopathology results.

		Histopathological Diagnoses		Total
		Positive	Negative	
Toluidine Blue	Positive	3(TP)	8 (FP)	11
	Negative	0 (FN)	45 (TN)	45
	Total	3	53	56

TN= True Negative. TP= True Positive. FN= False Negative. FP= False Positive.

specificity of 84.9%; with a PPV of 27.2%, of 100%, and diagnostic accuracy of 85.71%. The false positives were seen in T-IV (n=7/15) and T-III (n=1/11) lesions, whereas T-I and T-II lesions had no false positive results. None of the patients had any adverse effects as a direct consequence of the stain.

Discussion

Surgery, with a longstanding history of over a century, is the primary treatment option for a majority of oral cancers.⁹ The importance of complete resection in head and neck lesions can be emphasised by its influences on loco-regional recurrence and overall survival.¹⁰ The standard of care includes assessment of tumour margins with the use of intra-operative frozen sections to confirm that the margins of resection are free of cancerous tissue.³ Unfortunately the facility of frozen-section sampling is not readily available in most of the surgical centres in the developing world. Given that most of these countries have a fee for service health system, the added cost of frozen-section sampling limits its application. At our center set of five frozen section margins costs about Rs 6500 (USD75). Further, approximately half-an-hour is spent awaiting the results of a frozen section, which indirectly adds to the patient's expenses. A study also concluded that though accurate, intra-operative frozen-section margins are costly and cannot reliably eradicate positive final margins.⁴ Considering these limitations, a safe, cost-effective and reliable means of assessing the status of tumour margins is the need of the hour.

Toluidine blue costs only Rs25 (USD 0.30) and takes only 5 minutes for application and interpretation, alleviating financial constraints of the patient significantly. While assessing its application in 50 patients with squamous cell cancers of the aero-digestive tract, a study found positive margins of which 3 were true positive, while no false negative results were seen. It attributed the false positive staining to traumatic handling of mucosa during the resection.¹¹

We had similar results in our study with sensitivities of 100% and specificities of 84.9%. Most of our false positive results were observed in T-IV lesions (>6cm lesion/ involving

surrounding structures) and, hence, had wider excision margins and more traumatic handling of the mucosa. One false positive margin was observed in T-III lesion. Given the lack of false negatives, we can consider the use of toluidine blue as an effective screening tool for marginal status. Further protocols can be established to either excise the positive staining to tissue or minimise the number of frozen sections to those staining positive on toluidine blue.

However, in our initial experience with 2 pilot patients, we found the interpretation of mucosal staining to be difficult and used simultaneous frozen sections with the staining to get an idea of the staining pattern and avoid interpretational errors.

Conclusion

Intra-operative use of toluidine blue is a simple, safe and cost-effective method to screen tumour involved margins. It can be used with significant confidence in smaller lesions (T-I and T-II) as an alternative to frozen sections in developing countries where facilities are unavailable. Its use in larger lesions (T-III and TIV) remains the topic of controversy and awaits a multi centre trial with a larger cohort.

References

1. Mignogna MD, Fedele S, Lo Russo L. The World Cancer Report and the burden of oral cancer. *Eur J Cancer Prev* 2004; 13: 139-42.
2. Bhurgri Y, Bhurgri A, Nishter S, Ahmed A, Usman A, Pervez S, et al. Pakistan - country profile of cancer and cancer control 1995-2004. *J Pak Med Assoc* 2006; 56: 124-30.
3. Ord RA, Aisner S. Accuracy of frozen sections in assessing margins in oral cancer resection. *J Oral Maxillofac Surg* 1997; 55: 663-9; discussion 669-71.
4. DiNardo LJ, Lin J, Karageorge LS, Powers CN. Accuracy, utility, and cost of frozen section margins in head and neck cancer surgery. *Laryngoscope* 2000; 110: 1773-6.
5. Mashberg A, Samit A. Early diagnosis of asymptomatic oral and oropharyngeal squamous cancers. *CA Cancer J Clin* 1995; 45: 328-51.
6. Onofre MA, Sposto MR, Navarro CM. Reliability of toluidine blue application in the detection of oral epithelial dysplasia and in situ and invasive squamous cell carcinomas. *Oral Surg Oral Med Oral Pathol Oral Radiol Endod* 2001; 91: 535-40.
7. Siddiqui IA, Farooq MU, Siddiqui RA, Rafi SMT. Role of toluidine blue in early detection of oral cancer. *Pak J Med Sci*. 2006; 22: 184-7.
8. Epstein JB, Sciubba J, Silverman S Jr, Sroussi HY. Utility of toluidine blue in oral premalignant lesions and squamous cell carcinoma: continuing research and implications for clinical practice. *Head Neck* 2007; 29: 948-58.
9. Shah JP, Gil Z. Current concepts in management of oral cancer - surgery. *Oral Oncol* 2009; 45: 394-401.
10. Loree TR, Strong EW. Significance of positive margins in oral cavity squamous carcinoma. *Am J Surg* 1990; 160: 410-4.
11. Portugal LG, Wilson KM, Biddinger PW, Gluckman JL. The role of toluidine blue in assessing margin status after resection of squamous cell carcinomas of the upper aerodigestive tract. *Arch Otolaryngol Head Neck Surg* 1996; 122: 517-9.