



THE AGA KHAN UNIVERSITY

eCommons@AKU

Section of Otolaryngology, Head & Neck Surgery

Department of Surgery

September 2006

Incorporating endoscope in middle ear surgery

Shehzad Ghaffar
Aga Khan University

Mubasher Ikram
Aga Khan University

Ahsan Raza
Aga Khan University

Follow this and additional works at: https://ecommons.aku.edu/pakistan_fhs_mc_surg_otolaryngol_head_neck

 Part of the [Otolaryngology Commons](#), and the [Surgery Commons](#)

Recommended Citation

Ghaffar, S., Ikram, M., Raza, A. (2006). Incorporating endoscope in middle ear surgery. *ENT-Ear, Nose & Throat Journal*, 85(9), 593-596.

Available at: https://ecommons.aku.edu/pakistan_fhs_mc_surg_otolaryngol_head_neck/42

Incorporating the endoscope into middle ear surgery

Shehzad Ghaffar, FCPS, FRCS; Mubasher Ikram, FCPS; Sadaf Zia, FCPS; Ahsan Raza, MSc

Abstract

We conducted a study to evaluate the use of a pediatric rigid otoendoscope for determining the extent of middle ear disease and for assessing ossicular integrity and mobility during tympanoplasty. Our study population was made up of 132 patients who were undergoing surgery for the treatment of chronic suppurative otitis media; of this group, 41 patients underwent otoendoscopy and 91 underwent scutum lowering for purposes of visualization. In the otoendoscopy group, the ossicles were successfully visualized and their mobility assessed in 34 patients; the remaining 7 patients subsequently underwent scutum lowering. A 30° endoscope allowed for complete visualization of the middle ear in almost all of the 34 cases. The mean duration of surgery for the 34 patients in the otoendoscopy group was 62.85 minutes (± 15.57), which was significantly shorter than the duration of surgery (71.23 ± 15.65 min) for the 98 patients who underwent scutum lowering ($p < 0.005$). A total of 50 patients required less than 60 minutes of surgical time—26 of 34 (76.5%) in the endoscopy group and 24 of 98 (24.5%) in the scutum-lowering group. Statistical analysis revealed that the possibility of completing a procedure in less than 60 minutes was 73.65% ($\pm 12.56\%$) when endoscopy was used and 58.62% ($\pm 12.60\%$) when scutum lowering was used—again, a statistically significant difference ($p < 0.005$). We conclude that incorporation of an angled otoendoscope into middle ear surgery is a worthwhile alternative to scutum lowering.

Introduction

In the management of ear disease, early knowledge of the extent of damage can help in the planning of the appropriate surgical procedure.¹ Audiologic and radiologic assessments

are useful to some extent, but they do not provide a complete picture of the extent of damage. For many decades, direct visual examination of the middle ear was carried out with a microscope in the clinic or during surgery, but a microscope cannot provide a complete visual examination unless the scutum is lowered.² Scutum lowering during an operation allows the surgeon to see the normal structure of the ossicles and assess the continuity of the ossicular chain and ossicle mobility, but it adds to the length of surgery and is associated with increased morbidity, such as damage to the ossicular chain and the chorda tympani nerve.^{1,3}

The development of angled endoscopes has given surgeons a new tool for examining anatomic structures in the middle ear (figure 1).⁴ Comparisons of otoendoscopy and otomicroscopy have been made during canal-wall-up and canal-wall-down mastoid surgeries.⁵ Visualization seems to be better with angled endoscopes than with otomicroscopes.⁶ Also, the clarity of the image of the rigid endoscope is nearly equal to that of the operating microscope.⁷ Finally, many middle ear structures can be visualized with endoscopes through a perforated tympanic membrane.

In this article, we share our experience with the use of an angled pediatric rigid endoscope during tympanoplasty to visualize the middle ear structure through the external auditory meatus without the need for lowering the scutum.

Patients and methods

Our goal was to evaluate the role of the endoscope in (1) assessing the extent of middle ear disease, (2) confirming ossicular integrity and mobility during tympanoplasty, and (3) reducing operating time.

All patients who had undergone tympanoplasty for the treatment of chronic suppurative otitis media from Jan. 1, 2001, through Dec. 31, 2002, were initially eligible for the study. The only exclusion criterion was evidence of cholesteatoma. Ultimately, 132 patients were enrolled in this case series. Data were acquired both retrospectively and prospectively.

From Jan. 1, 2001, through Feb. 28, 2002, it was the practice at our institution that tympanoplasty patients underwent scutum lowering for middle ear visualization; we identified 91 eligible patients who had undergone the procedure during that period. On March 1, 2002, we changed

From the Otolaryngology–Head and Neck Surgery Section (Dr. Ghaffar, Dr. Ikram, and Dr. Zia) and the Research Section (Mr. Raza), Department of Surgery, Aga Khan University Hospital, Karachi, Pakistan.

Reprint requests: Shehzad Ghaffar, Senior Instructor, Section of Otolaryngology–Head and Neck Surgery, Aga Khan University, Stadium Rd., Karachi, 74800 Pakistan. Phone: 92-21-486-4767; fax: 92-21-493-2095 or 92-21-493-4294; e-mail: sgm@akunet.org

Originally presented at the 10th Asia Oceania Meeting; Feb. 22-26, 2004; Kuala Lumpur, Malaysia.

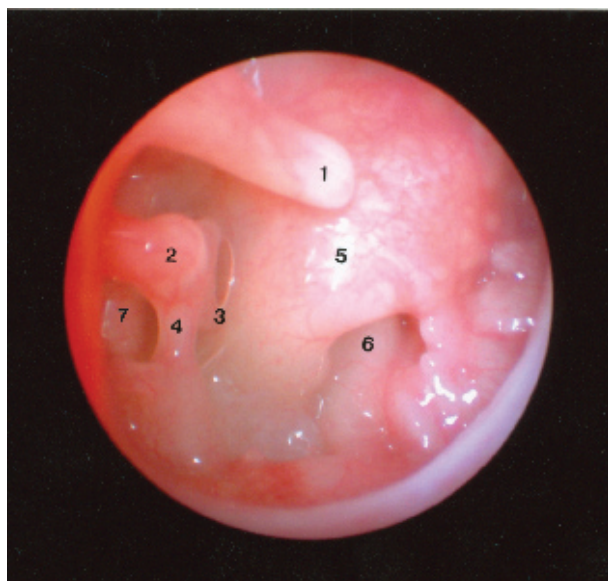

Figure 1. Endoscopic view of a right-sided middle ear shows the handle of the malleus (1), the incudostapedial joint (2), the posterior crura of the stapes (3), the stapedius tendon (4), the promontory (5), the round window (6), and the facial recess (7).

our practice and began to incorporate rigid otoendoscopy into our tympanoplasty procedures; we identified 41 patients who had undergone initial endoscopy from then until the end of the study on Dec. 31, 2002. In this group, scutum lowering was performed only when the middle ear could not be completely visualized by endoscopy.

An independent t test was used for statistical analysis. Pediatric rigid endoscopes (2.7 mm wide) of 0°, 30°, and 70° were used in this study; a pediatric scope was preferred to the adult scope (4.0 mm wide) because it leaves ample room for an instrument to manipulate the ossicles and because it is associated with a lower risk of damage to the skin of the external auditory canal.

Results

Among the 41 otoendoscopy patients, complete visualization of the ossicles was achieved in 34 (82.9%); the remaining 7 underwent subsequent scutum lowering. Scutum lowering was successful in all 7 of these patients, as well as in the original 91 patients. Among the 34 patients, the ossicles were found to be eroded in 1 patient because of the presence of cholesteatoma in the attic; the remainder

Recommended by over 1,000 ENTs

MICHAEL SEIDMAN, MD, FACS
authority on tinnitus and conditions of the inner ear/ear canal

"IT HAS BEEN MY EXPERIENCE in treating patients with Arches Tinnitus Relief Formula that the majority experience complete resolution of symptoms, 100% experience no relapse, and 80% receive some degree of relief from their symptoms, varying by individual. I recommend Arches Tinnitus Relief Formula to many of my patients and advise them to take two capsules 4 times a day and repeat after the evening and continue this dosage for 30 days before determining the degree of relief Arches Tinnitus Relief Formula will provide."

Dr. Michael Seidman, MD, FACS
 ENT Specialist, The Ear, Nose & Throat Center

ARCHES TINNITUS RELIEF FORMULA

CLINICAL STUDIES HAVE SHOWN BOTH GINKGO BILOBA EXTRACT AND CHELATED ZINC EFFECTIVE IN REDUCING TINNITUS.

- 1. **Journal of Otolaryngology, February, 1997, Vol. 116, No. 2, January, 1997, Vol. 116, No. 1, p. 106-110. Published by the American Academy of Otolaryngology-Head and Neck Surgery.**
- 2. **Mayo Clinic Proceedings, November 1997, Vol. 72, No. 11, p. 1000-1005.**
- 3. **Mayo Clinic Proceedings, February 1998, Vol. 73, No. 2, p. 186-190.**
- 4. **Journal of Otolaryngology, February 2000, Vol. 129, No. 2, p. 106-110.**

TINNITUS RELIEF IS UNDER THE ARCH

CALL FOR A FREE PHYSICIAN'S BOOKLET PLUS CD
 WITH 35 CLINICAL STUDIES, C OF A, & MORE...

TOLL FREE 800-350-8631
email: admin@archesing.com www.tinnitusformula.com

Tinnitus Formulas

THESE FORMULAS ARE NOT INTENDED TO TREAT ANY OTHER DISEASES OR CONDITIONS. THEY ARE INTENDED TO TREAT TINNITUS ONLY. IF YOU ARE TAKING ANY OTHER MEDICATIONS, PLEASE CONSULT YOUR PHYSICIAN BEFORE USING THESE FORMULAS.

Table 1. Mean duration of the tympanoplasty in the two groups

Visualization	n	Mean duration (min)	p value
Otoendoscopy	34	62.85 ± 15.57	<0.005
Scutum lowering	98	71.23 ± 15.65	

of the examinations revealed normal structures.

The mean duration of the 34 tympanoplasties in which the endoscope was successfully incorporated was 62.85 minutes (±15.57), and the mean duration of the 98 tympanoplasties in which the scutum was lowered was 71.23 minutes (±15.65); the difference is statistically significant (p < 0.005) (table 1).

Among the 132 patients, operative time was less than 60 minutes in 50 patients—26 in the otoendoscopy group and 24 in the scutum-lowering group. Using the independent t test, we calculated that the possibility of completing the procedure in less than 60 minutes was 73.65% (±12.56%) when incorporating endoscopy and 58.62% (±12.60%) when incorporating scutum lowering; again, the difference

Table 2. Possibility of completing a tympanoplasty in 60 minutes*

Visualization	n	Possibility (%)	p value
Otoendoscopy	26	73.65 ± 12.56	<0.005
Scutum lowering	24	58.62 ± 12.60	

*The independent t test was used to calculate these data on 26 patients in the otoendoscopy group and 24 patients in the scutum-lowering group whose procedures took less than 60 minutes.

is statistically significant (p < 0.005) (table 2, figure 2).

Discussion

The introduction of the binocular operating microscope was a landmark event in the development of modern otology, and it clearly changed the scope and character of ear surgery.⁸ Despite continuous technical improvements, the basic optical principles and their limitations have remained the same over the past 3 decades.

Much has been written about the diagnostic role of endoscopes for examining the tympanic membrane and

TIC-TONG™

Flavored Plastic Tongue Depressor

Makes any exam faster and less stressful for your young clients!

Sugar & Latex FREE
Fruit Flavored



Medical use. Individually Wrapped.
Single use. Allergy Free.



Available in packs of 40 units, assorted animals and colors.



**TIC-TONG®
Animals Model**
5½" long x 5/8" wide



**TIC-TONG®
Standard Model**
6" long x 5/8" wide

U.S. Patented - FDA 510K - CE

www.tic-tong.com
GEPLA21, LLC - Doral, FL 33172
Phone: (305) 539-3871

sales@tic-tong.com
commercial@tic-tong.com
Fax: (305) 704-3505

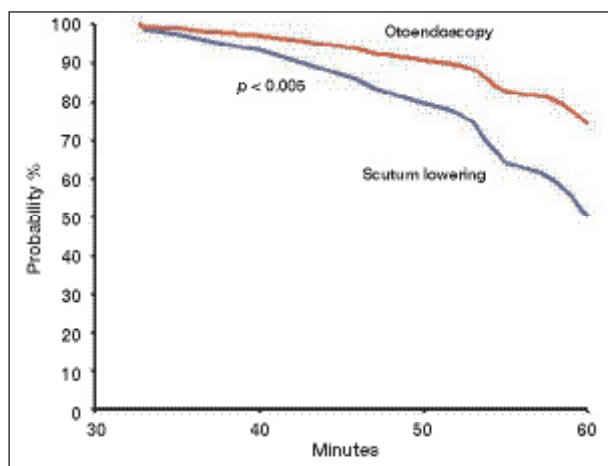


Figure 2. Graph illustrates the possibility of completing the two procedures within 60 minutes.

the ear canal.⁹ The transtympanic endoscope has been used for quite some time for the diagnosis of perilymph fistula and other middle ear disorders.¹⁰ It has also been tried as an alternative to second-look mastoidectomy in canal-wall-up mastoidectomies.¹¹

We examined another important use of the endoscope—namely, as a means of examining the middle ear space and assessing ossicular integrity. We found that a 30° endoscope can visualize the middle ear in almost all cases; a 70° endoscope can also be employed when needed.¹² During endoscopy, the malleus, incus, and stapes can be visualized and palpated.¹² The hidden structures of the middle ear—the sinus tympani, facial recess, attic, and hypotympanum—can also be easily visualized.⁸ One of the many advantages of otoendoscopy is that it provides a wide-angle view of the entire tympanic ring and ear canal at the same time without the need for repeatedly repositioning the patient.¹³ Another important advantage is that it can visualize structures parallel to its axis; this is not possible with a microscope, the use of which requires that the structures be at a right angle to the axis for adequate visualization.

The disadvantages of the endoscope include a loss of binocular vision and depth perception, but these drawbacks are easily overcome with experience. Attaching a video camera to the endoscope can compensate for the loss of focus that occurs at the level of the endoscope.⁸ One major safety concern is heat dissipation from the tip of the endoscope when a xenon light source is used; however, this risk can be obviated by using a Storz Cold Light Fountain Halogen 150W light source, which has a color temperature of approximately 3,400 K and can well illuminate the small middle ear cavity.^{8,14} Another important disadvantage is that surgery must be performed with only one hand.

In our study, otoendoscopy was attempted in 41 patients. The tympanomeatal flap was elevated and the middle ear

was exposed. However, endoscopy failed in 7 patients (17.1%). The cause of failure in these cases was either a narrow canal or excessive bleeding. Almost all of these failures occurred shortly after we began routinely using otoendoscopy as the initial means of visualizing the middle ear; as we gained experience, the failures became less frequent. Of the 34 patients who successfully underwent otoendoscopy, 1 patient was found to have eroded ossicles secondary to the presence of a cholesteatoma in the attic, and this patient was treated accordingly. In the 98 cases in which scutum-lowering was performed, no damage to the ossicular chain or chorda tympani nerve occurred.

In conclusion, incorporating the use of an angulated, pediatric, rigid 30° endoscope into middle ear surgery allows surgeons to visualize the middle ear completely and to simultaneously check for ossicular continuity and mobility without the need for lowering the scutum. Also, the use of otoendoscopy shortens operating time, and its optics are as clear as those of the microscope.

References

- Hopf JU, Hopf M, Gundlach P, Scherer H. Miniature endoscopes in otorhinolaryngologic applications. *Min Invas Ther Allied Technol* 1998;7/3:209-18.
- Karhuketo TS, Laippala PJ, Puhakka HJ, Sipila MM. Endoscopy and otomicroscopy in the estimation of middle ear structures. *Acta Otolaryngol* 1997;117:585-9.
- Sone M, Sakagami M, Tsuji K, Mishiro Y. Young patients have a higher rate of recovery of taste function after middle ear surgery. *Arch Otolaryngol Head Neck Surg* 2001;127:967-9.
- Nomura Y. A needle otoscope. An instrument of endoscopy of the middle ear. *Acta Otolaryngol* 1982;93:73-9.
- Thomassin JM, Korchia D, Doris JM. Endoscopic-guided otosurgery in the prevention of residual cholesteatomas. *Laryngoscope* 1993;103:939-43.
- Tschabitscher M, Klug C. Two-port endoscopy of the middle ear: Endoscopic anatomy. *Arch Otolaryngol Head Neck Surg* 1999;125:433-7.
- Poe DS, Rebeiz EE, Pankratov MM, Shapshay SM. Transtympanic endoscopy of the middle ear. *Laryngoscope* 1992;102:993-6.
- Tarabichi M. Endoscopic middle ear surgery. *Ann Otol Rhinol Laryngol* 1999;108:39-46.
- Hawke M. Telescopic otoscopy and photography of the tympanic membrane. *J Otolaryngol* 1982;11:35-9.
- Poe DS, Bottrill ID. Comparison of endoscopic and surgical explorations for perilymphatic fistulas. *Am J Otol* 1994;15:735-8.
- McKenna KX. Endoscopic "second look" mastoidectomy to rule out residual epitympanic/mastoid cholesteatoma. *Laryngoscope* 1993;103:810-14.
- Karhuketo TS, Puhakka HJ, Laippala PJ. Tympanoscopy to increase the accuracy of diagnosis in conductive hearing loss. *J Laryngol Otol* 1998;112:154-7.
- Rosenberg SI, Silverstein H, Hoffer M, Nichols M. Use of endoscopes for chronic ear surgery in children. *Arch Otolaryngol Head Neck Surg* 1995;121:870-2.
- Bottrill I, Perrault DF Jr., Poe D. In vitro and in vivo determination of the thermal effect of middle ear endoscopy. *Laryngoscope* 1996;106:213-16.