



Tuberculous endocarditis: valvular and right atrial involvement

Fateh Ali Tipoo Sultan¹, Saulat Fatimi², Bushra Jamil², Sherif E. Moustafa³, and Farouk Mookadam^{4*}

¹Section of Cardiology, Aga Khan University Hospital, Karachi, Pakistan; ²Section of Cardiac Surgery, Aga Khan University Hospital, Karachi, Pakistan; ³Department of Cardiology, University of Alberta hospital, Edmonton, AB, Canada; and ⁴Department of Cardiovascular Diseases & Internal Medicine, Mayo College of Medicine, Mayo Clinic, Scottsdale, AZ, USA

Received 23 July 2009; accepted after revision 10 November 2009; online publish-ahead-of-print 10 December 2009

Valvular endocarditis due to *Mycobacterium tuberculosis* is a rare clinical entity. It is usually manifest in the context of disseminated tuberculosis in immunocompromised patients. This report describes a unique case of a 30-year-old immunocompetent man with an incidental finding of tuberculous valvular endocarditis. The patient had a large mass on the anterior mitral leaflet and severe mitral regurgitation. He underwent mitral valve replacement and *Mycobacterium tuberculosis* was cultured from the valve vegetation and the right atrial masses. Post-operative recovery has been uneventful without relapse for 24 months.

Keywords *Mycobacterium tuberculosis* • Valvular endocarditis • Right atrium tuberculoma

Case presentation

A 30-year-old man was referred due to fever with progressive dyspnoea for 2 months. Physical examination was remarkable for fever (38.5°C). The cardiovascular examination revealed an apical 3/6 pansystolic murmur decreased with inspiration and radiating to the axilla consistent with significant mitral regurgitation. Jugular venous pressure was estimated at 20 mmHg. Grade 2/4 peripheral oedema was noted. Bibasilar rales were present in both lungs. Chest roentgenogram showed interstitial pulmonary oedema with a small left pleural effusion. Electrocardiogram demonstrated right bundle branch block. Laboratory data revealed a normochromic normocytic anaemia with haemoglobin of 99 g/L, white blood cells of 14 000 per μL with 83% neutrophils, and serum creatinine of 1.9 mg/dL. Serial cardiac enzymes were normal. With the provisional diagnosis of infective endocarditis, three sets of blood cultures were drawn and antibiotics (vancomycin and amikacin) were started together with anti-failure medications. Transthoracic echocardiogram (TTE) showed a mildly dilated left ventricle with normal systolic function (ejection fraction = 60%). A 29 × 10 mm highly mobile mass was seen attached to the tip of the anterior mitral leaflet with a flail segment of the anterior leaflet. Colour Doppler echocardiography confirmed severe eccentric posteriorly directed jet of mitral regurgitation (Figure 1, Supplementary data, Videos S1 and S2). There was also severe tricuspid

regurgitation with moderate pulmonary hypertension. The aortic and pulmonic valves were normal.

Blood cultures were negative after extended culture. Fever persisted with no improvement in the overall clinical condition. Cardiac surgery was planned on the 5th day of the admission. Operative findings revealed multiple, small, dense, yellowish masses in the right atrium with caseating appearance and a large vegetation on the friable perforated anterior mitral leaflet with ruptured chordae (Supplementary data, Figures S1 and S2). The mitral valve was excised and replaced with 31 mm mechanical prosthesis. The dense yellow areas inside the right atrium were cleaned and samples sent for culture and histopathology. The immediate post-operative course was uneventful.

Samples from the right atrial masses and mitral valve vegetation were negative for bacteria and fungi. Histology was non-diagnostic with no definitive granulomas. At Day 20 post-operative, positive cultures for *Mycobacterium tuberculosis* (*M. tuberculosis*) from both sites were detected and were sensitive to all anti-tuberculous medications. Four antituberculous drugs (isoniazid, ethambutol, rifampicin, and pyrazinamide) were administered for 2 months and thereafter isoniazid and rifampicin for 10 months. Post-operative recovery was subsequently unremarkable with resolution of heart failure symptoms. The patient was discharged from the hospital and was symptom-free after 24 months of follow-up.

* Corresponding author. Tel: +1 480 301 6907, Fax: +1 480 301 8018, Email: mookadam.farouk@mayo.edu

Published on behalf of the European Society of Cardiology. All rights reserved. © The Author 2009. For permissions please email: journals.permissions@oxfordjournals.org.

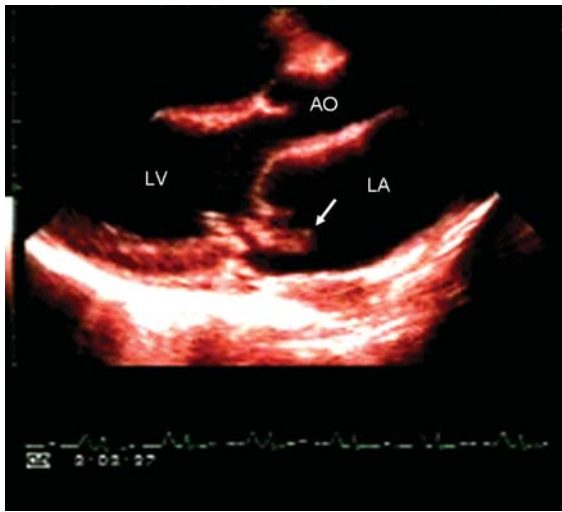


Figure 1 Transthoracic echocardiogram parasternal long-axis view showing a mass attached to the tip of the anterior mitral valve leaflet (white arrow) with severe anterior leaflet prolapse consistent with flail mitral valve. AO, ascending aorta; LA, left atrium; LV: left ventricle.

Discussion

To the best of our knowledge, this is the first case of tuberculous mitral valve endocarditis in an immunocompetent alive patient in association with right atrial tuberculoma. Tuberculous valvular endocarditis is a rare disease with most reports coming from autopsy series.^{1,2} In 1826, Laennec was the first to describe cardiac tuberculosis, assigning the heart as the 13th organ affected in the order of frequency.³ In 1906, a large series of 7683 cases of tuberculosis reported myocardial involvement in 0.62% cases.⁴

Tuberculous valvular endocarditis is usually manifest in the context of miliary tuberculosis and after valve replacement with an infected prosthetic homograft.^{5–11} Porcine prosthetic valves and water used in the cardioplegia cooling solution have been reported as sources of atypical mycobacterial contamination.^{7,8}

Two reports have been found in the literature of tuberculous valvular endocarditis in immunocompetent alive patients in the absence of miliary tuberculosis.^{12,13} Klingler et al. reported one patient with severe mitral valve regurgitation due to a perforation of the anterior mitral leaflet. Histology showed a calcified nodule with multiple granulomata and cultures from the vegetation grew *M. tuberculosis*.¹² Sogabe and Ohya described a case of acute aortic insufficiency caused by tuberculous endocarditis associated with annular subvalvular left ventricular aneurysm beneath the aortic valve. Histopathological findings of the excised aortic cusps were diagnostic of tuberculous endocarditis. However, live acid-fast bacilli were not detected either in serial blood cultures or the surgical specimens.¹³ In our patient, the mitral valve was the culprit and the histology was non-diagnostic, but cultures were positive.

The unique feature in our case is the tuberculous involvement of the right atrium in addition to tuberculous mitral valve

endocarditis. Although rare, other sites of tuberculous heart involvement include coronary arteries, atrial and ventricular tuberculoma, and tuberculous myocarditis and pericarditis. Atrial and ventricular tuberculoma originate from the endocardium and can be visualized by echocardiography as dense masses similar to atrial myxoma. During surgery, encapsulated tumours containing dough-like, yellowish-white substance have been noticed, with *M. tuberculosis* seen on smear and culture.¹²

The difficulty in the diagnosis of this disease is due to slow growth of the mycobacterium. Although histopathological findings are essential for definitive diagnosis, premortem diagnosis of tuberculous endocarditis is difficult as represented by the low rate of diagnosis of tuberculosis and infective endocarditis.^{13,14}

Anti-tuberculous medications are one of the key treatments to prevent post-operative recurrence. We used isoniazid, rifampicin, ethambutol, and pyrazinamide for 2 months and then rifampicin and isoniazid for 10 months. The patient made a good recovery with no recurrence in 24 months post-operative.

This report highlights the rare case of tuberculous mitral valve endocarditis and right atrial tuberculoma in an immunocompetent individual diagnosed by cultures for *M. tuberculosis*. Prompt surgical resection of the infected tissue and timely administration of anti-tuberculous therapy can be curative.

Supplementary data

Supplementary data are available at *European Journal of Echocardiography* online.

Conflict of interest: none declared.

References

1. Suzman S. Tuberculous endocarditis. *Br Heart J* 1943;**5**:19.
2. Rumisek JD, Albus RA, Clarke JS. Late *Mycobacterium chelonae* bioprosthetic valve endocarditis: activation of implanted contaminant? *Am Thorac Surg* 1985;**39**: 277–9.
3. Laennec RTH. Traite de l'auscultation mediate. 1826. *Bull Acad Natl Med* 1967; **151**:393–8.
4. Raviart G. La tuberculose du myocarde. *Arch Med Exper* 1906;**29**:141.
5. Kannangara DW, Salem FA, Thadepalli H. Cardiac tuberculosis: tuberculosis of the endocardium. *Am J Med Sci* 1984;**287**:45–7.
6. Cope AP, Heber M, Wilkins EGL. Valvular tuberculous endocarditis: a case report and review of the literature. *J Infection* 1990;**21**:293–6.
7. Laskowski LF, Marr JJ, Spornoga JF, Frank NJ, Barner HB, Kaiser G et al. Fastidious mycobacteria grown from porcine prosthetic heart valve cultures. *N Engl J Med* 1997;**297**:101.
8. Kuritsky JN, Bullen MG, Broome CV, Silcox VA, Good RC, Wallace RJ. Sternal wound infections and myocarditis due to organisms of the *Mycobacterium fortuitum* complex. *Ann Intern Med* 1983;**98**:938–9.
9. Wainwright J. Tuberculous endocarditis. A report of two cases. *S Afr Med J* 1979; **56**:731–3.
10. Anyanwu CH, Nassau E, Yacoub M. Miliary tuberculosis following homograft valve replacement. *Thorax* 1976;**31**:101–6.
11. Yamane H, Fujiwara T, Doko S, Inada H, Nogami A, Masaki H et al. Two cases of miliary tuberculosis following prosthetic valve replacement. *Kokyu to Junkan* 1989; **37**:803–5.
12. Klingler K, Brandli O, Doerfler M, Schluger N, Rom WN. Valvular endocarditis due to *Mycobacterium tuberculosis*. *Int J Tuberc Lung Dis* 1998;**2**:435–7.
13. Sogabe O, Ohya T. A case of tuberculous endocarditis with acute aortic valve insufficiency and annular subvalvular left ventricular aneurysm. *Gen Thorac Cardiovasc Surg* 2007;**55**:61–4.
14. Kapoor OP, Mascarenhas E, Ranananaware MM, Gadgil RK. Tuberculoma of the heart: report of 9 cases. *Am Heart J* 1973;**86**:334–40.