



THE AGA KHAN UNIVERSITY

eCommons@AKU

---

Section of Pulmonary & Critical Care

Department of Medicine

---

December 2009

# Wegener's granulomatosis: a diagnostic challenge


Ali Bin Sarwar Zubairi  
*Aga Khan University*

Hammad Bin Liaquat  
*Aga Khan University*

Shahid Javed Husain  
*Aga Khan University*

Kulsoom Fatima  
*Aga Khan University*

Follow this and additional works at: [http://ecommons.aku.edu/pakistan\\_fhs\\_mc\\_med\\_pulm\\_critcare](http://ecommons.aku.edu/pakistan_fhs_mc_med_pulm_critcare)

 Part of the [Respiratory System Commons](#), and the [Respiratory Tract Diseases Commons](#)

---

## Recommended Citation

Zubairi, A., Liaquat, H., Husain, S., Fatima, K. (2009). Wegener's granulomatosis: a diagnostic challenge. *Journal of the Pakistan Medical Association*, 59(12), 853-5.

**Available at:** [http://ecommons.aku.edu/pakistan\\_fhs\\_mc\\_med\\_pulm\\_critcare/8](http://ecommons.aku.edu/pakistan_fhs_mc_med_pulm_critcare/8)

## Case Report

### **Wegener's Granulomatosis: A diagnostic challenge**

Ali Bin Sarwar Zubairi,<sup>1</sup> Hammad Bin Liaquat,<sup>2</sup> Shahid Javed Husain,<sup>3</sup> Kulsoom Fatima<sup>4</sup>

Section of Pulmonary and Critical Care Medicine,<sup>1,3</sup> Medical Student,<sup>2</sup> Department of Radiology,<sup>4</sup>  
The Aga Khan University Hospital, Stadium Road, Karachi, Pakistan.

#### **Abstract**

Wegener's Granulomatosis (WG) is a necrotizing granulomatous vasculitis that primarily involves small vessels in the body. Patient usually presents in the fourth to fifth decade. The clinical presentation is variable; however, majority of patients (90%) seek medical attention for nasal and sinus symptoms with or without lower respiratory symptoms of cough, dyspnoea and haemoptysis. The typical form of WG tends to involve the triad of upper and lower respiratory tract and the kidneys; while involvement of other organs like ocular, cutaneous, rheumatological, neural, gastrointestinal and lower genito-urinary tract is occasionally seen. A "limited" form with clinical findings isolated to the upper respiratory tract or lungs, occur in approximately one-fourth of cases.

We present a case of Wegener's Granulomatosis in an eighty five year old lady who presented with an acute pneumonia-like illness. She underwent an extensive work-up to reach a definitive diagnosis.

#### **Introduction**

Wegener's Granulomatosis (WG) is an autoimmune disease that primarily involves small vessels in the body. The clinical presentation is variable. A typical form of the disease tends to involve the upper and lower respiratory tract and the kidneys, while ocular, cutaneous, rheumatological, neural, gastrointestinal and lower genito-urinary tract involvement has also been found occasionally.<sup>1-4</sup>

We present a case of Wegener's Granulomatosis in an elderly lady who presented with acute pneumonia-like illness. She underwent extensive work-up to reach a diagnosis.

#### **Case Report**

An eighty-five year old asthmatic female, presented to the Emergency Room (ER) with ten day history of fever, right-sided pleuritic chest pain and dry cough. On examination, the BP was 110/70 mmHg, heart rate 86/min, temperature 38.0°C, and Respiratory Rate (RR) of 20/min. Chest examination revealed decreased air entry in left lower lung zone and scattered bilateral wheezes. Rest of the systemic examination was unremarkable. Initial investigations revealed a white

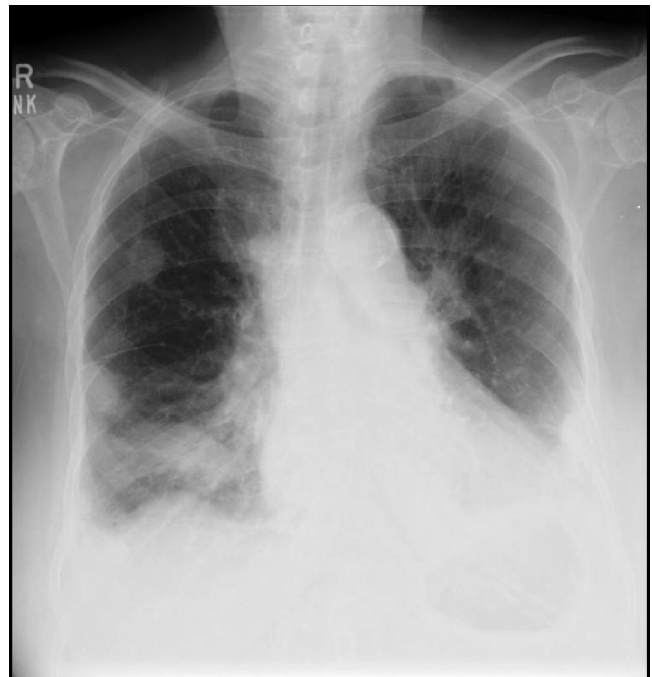

Figure-1.

blood cell count of  $11.2 \times 10^9/L$  with a left shift and an erythrocyte sedimentation rate (ESR) of 112 mm/hour. Serum electrolytes and renal function were normal. The chest radiograph showed rounded opacities in right mid and lower lung zones and confluent alveolar opacity in left lower zone silhouetting the left hemi diaphragm (Figure-1).

The patient was admitted with a diagnosis of Community-acquired pneumonia and treated with intravenous Ceftriaxone and oral Clarithromycin. Intravenous Hydrocortisone along with bronchodilators was given for bronchospasm. The patient had a good clinical response and was discharged on day 4 on oral Clarithromycin and Prednisolone in a tapering dose.

On follow-up, she complained of recurrent fever and cough. Chest x-ray revealed persistent rounded opacities in right lung. She underwent bronchoscopy with bronchoalveolar lavage and endobronchial biopsy which showed acute inflammation and no pathogens were identified on culture. Antibiotic treatment was broadened. Intravenous Piperacillin/Tazobactam and Trimethoprim/sulfamethoxazole were started as an outpatient.

The patient was re-admitted with non-resolving pneumonia. CT Chest was done which revealed nodular densities throughout both lungs and a cavitary lesion visible in right mid lung zone (Figure-2). The serum creatinine rose to 3.1 mg/dl from 1.1 mg/dl (previous admission). A urine analysis revealed proteinuria (0.3 g/L), haemoglobinuria with 10 RBC / hpf along with WBC casts. Twenty four hour urine protein was elevated (510

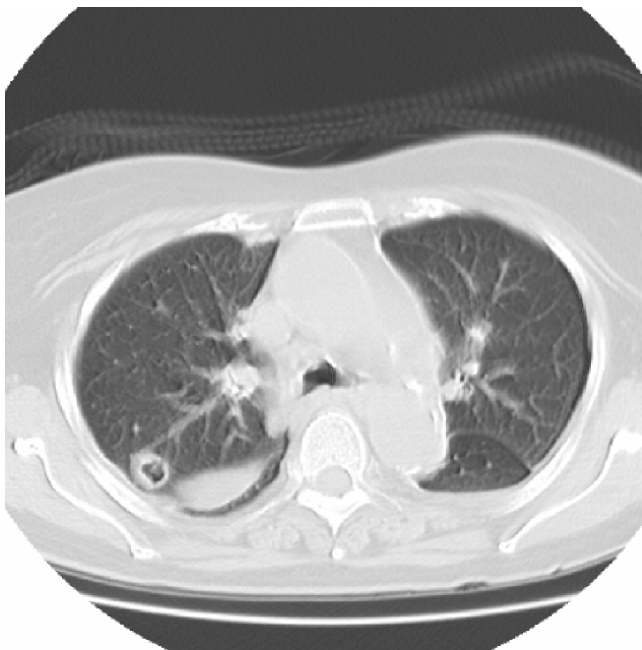


Figure-2.

mg/24 hours and the creatinine clearance was below normal (8 ml/min). A renal biopsy was done and c-ANCA (antineutrophil cytoplasmic antibody) was sent.

The renal biopsy revealed changes consistent with acute focal necrotizing process involving the glomeruli and the c-ANCA was positive (4.73 U/ml). A diagnosis of Wegener's granulomatosis was made and the patient was started on oral Prednisolone 30 mg daily and oral Cyclophosphamide at a dose of 0.5mg/kg/day. She had a dramatic response to the treatment.

## Discussion

Vasculitides are a group of systemic disorders that are classified according to the predominant type or size of vessels involved. Wegener's Granulomatosis (WG) is a non-infectious granulomatous disorder mostly involving small vessels.<sup>1-3</sup> Other disorders which fall in the same category include Microscopic polyangiitis and Churg-Strauss syndrome.

Patients tend to present with Wegener's Granulomatosis between forty to fifty years of age. Initially, they can have constitutional symptoms (fever, anorexia, malaise, myalgias, arthralgias) or have more specific complaints such as rhinorrhea, cough, haemoptysis with or without chest pain.<sup>3,4</sup> The chest radiograph may reveal non-specific findings such as nodular. Alveolar or hazy opacities with or without evidence of pleural involvement.<sup>5</sup>

A high index of suspicion is crucial as the disease has a variable presentation and, more importantly, the associated grave and, occasionally fatal outcomes.<sup>4,6</sup>

Our patient was eighty-five years old when she first presented to the pulmonary medicine clinic and, her main complaints and radiological findings on chest x-ray and C.T. scan of the chest seemed to imply an infective process on first impression. The patient's unresponsiveness to antibiotic therapy and temporary improvement observed with steroids during the initial admission indicated that a more sinister disease process was ongoing.

Renal involvement is common in WG. It is manifested by a raised serum creatinine, haematuria, proteinuria and red cell casts in majority of cases.<sup>7</sup> In our case the rise in serum creatinine within few weeks and the presence of haemoglobin and protein in the urine indicated that the disorder was rapidly compromising kidney function.

Routine laboratory tests are generally non-specific in WG. Common abnormalities include leukocytosis, thrombocytosis, marked elevation of ESR and normocytic normochromic anemia.

On the suspicion of pulmonary-renal syndrome, the autoimmune profile was sent to the laboratory which revealed presence of C-ANCA antibodies.

The antineutrophil cytoplasm antibodies (ANCA) are commonly found in small vessel vasculitides. Approximately 90% of patients with active generalized WG are ANCA-positive. A small subset of patients with active, generalized WG and up to 40% of patients with limited WG may be ANCA-negative. Studies have found that c-ANCA (cytoplasmic-ANCA) is the predominant antibody found in WG, p-ANCA (perinuclear-ANCA) is the other subtype and is associated with Microscopic polyangiitis.<sup>8</sup>

The diagnosis of WG is confirmed by tissue biopsy at a site of active disease. Biopsy of a nasopharyngeal lesion (if present) is preferred because it is relatively non-invasive.<sup>9,10</sup> If there is no lesion in the upper respiratory tract, biopsy of an affected organ such as skin, kidney or lung can be done.

Corticosteroid therapy with Cyclophosphamide results in complete remission in >90% of patients. The usual dosage of both drugs is 2 mg/kg/day. Once remission is achieved in 3 to 6 months, Cyclophosphamide is replaced by either Methotrexate or Azathioprine.

Relapses have been observed in up to 50% of patients. A relapse is usually associated with viral or bacterial infection.

### Conclusion

This particular case was a diagnostic challenge because of its atypical nature based on the fact that the age of the patient at presentation was far above the man age of presentation, and that the uncharacteristic nature of her

complaints and all initial investigations gave the impression that she was probably suffering from a chest infection. It is only when the patient did not respond to antibiotics, that subsequent workup revealed compromised renal function and elevated C-ANCA antibody levels.

Therefore it is recommended that a physician should approach such disorders with a combination of clinical findings and thorough work-up, as the disease responds well to treatment, but can lead to death if misdiagnosed.

### References

1. Blundell AG, Roe S. Wegener's granulomatosis presenting as a pleural effusion. *BMJ* 2003; 327: 95-6.
2. Uppal S, Saravanappa N, Davis JP, Farmer CK, Goldsmith DJ. Pulmonary Wegener's granulomatosis misdiagnosed as malignancy. *BMJ* 2001; 322: 89-90.
3. Seo P, Stone JH. The antineutrophil cytoplasmic antibody-associated vasculitides. *Am J Med* 2004; 117: 39-50.
4. Reinhold-Keller E, Beuge N, Latza U, deGroot K, Rudert H, Nolle B, et al. An interdisciplinary approach to the care of patients with Wegener's granulomatosis: Long-term outcome in 155 patients. *Arthritis Rheum* 2000; 43:1021-32.
5. Allen SD, Harvey CJ. Imaging of Wegener's granulomatosis. *Br J Radiol* 2007; 80: 757-65.
6. Bacon PA. The spectrum of Wegener's granulomatosis and disease relapse. *N Engl J Med* 2005; 352: 330-2.
7. Jennette JC, Falk RJ. Small-vessel vasculitis. *N Engl J Med* 1997; 337: 1512-23.
8. Kamesh L, Harper L, Savage CO. ANCA-positive vasculitis. *J Am Soc Nephrol* 2002; 13: 1953-60.
9. Hauer HA, Bajema IM, van Houwelingen HC, Ferrario F, Noel LH, Waldherr R, et al. Renal histology in ANCA-associated vasculitis: differences between diagnostic and serologic subgroups. *Kidney Int* 2002; 61:80-9.
10. Haas M, Eustace JA. Immune complex deposits in ANCA-associated crescentic glomerulonephritis: a study of 126 cases. *Kidney Int* 2004; 65: 2145-52.