



THE AGA KHAN UNIVERSITY

eCommons@AKU

---

Section of Otolaryngology, Head & Neck Surgery

Department of Surgery

---

July 2012

# A case of otogenic tetanus.

Mohammad Adeel  
*Aga Khan University*

Shaheryar Ahmed Rajput  
*Aga Khan University*

Muhammad Sohail Awan  
*Aga Khan University*

Asif Arain  
*Aga Khan University*

Follow this and additional works at: [https://ecommons.aku.edu/pakistan\\_fhs\\_mc\\_surg\\_otolaryngol\\_head\\_neck](https://ecommons.aku.edu/pakistan_fhs_mc_surg_otolaryngol_head_neck)

 Part of the [Otolaryngology Commons](#)

---

## Recommended Citation

Adeel, M., Rajput, S., Awan, M., Arain, A. (2012). A case of otogenic tetanus.. *BMJ Case Reports*, 2012, 1-21.  
**Available at:** [https://ecommons.aku.edu/pakistan\\_fhs\\_mc\\_surg\\_otolaryngol\\_head\\_neck/21](https://ecommons.aku.edu/pakistan_fhs_mc_surg_otolaryngol_head_neck/21)

## Rare disease

## A case of otogenic tetanus

Mohammad Adeel, Shaheryar Ahmed Rajput, Muhammad Sohail Awan, Asif Arain

Otorhinolaryngology Head & Neck Surgery Department, Aga Khan University Hospital, Karachi, Sindh, Pakistan

**Correspondence to** Dr Mohammad Adeel, doc.adeel.khan@gmail.com

### Summary

The authors are presenting our experience of managing an interesting case of a 12-year-old girl who presented to our clinic with otorrhea for 3 months and trismus for 1 week. Examination showed bilateral ear discharge with central perforations in tympanic membranes, palatal paralysis and trismus. Systemic examination revealed only mild stiffness of hand muscles. CT-scan head and neck was done to look for intracranial complications of otitis media. However; it revealed only decreased pneumatization of mastoid cells. She was admitted in the hospital and started on intravenous and local antibiotics after sending ear swab and blood cultures. But she showed no improvement in 48 h. So on the clinical suspicion (trismus and stiffness of hands) remote possibility of otogenic tetanus was considered and she was given tetanus toxoid and immunoglobulins. She gradually showed improvement in her symptoms. Thereafter, culture from ear discharge was also reported positive for *Clostridium tetani*.

### BACKGROUND

Otogenic tetanus does not seem to be an uncommon entity in the developing part of the world but lack of awareness may result in misdiagnosis with grim consequences. These patients initially present with discharging ears, therefore this case report is intended to increase awareness among medical practitioners especially otolaryngologists who would be the first to suspect this diagnosis and initiate appropriate management.

### CASE PRESENTATION

A 12-year-old girl came to our clinic with mild sore throat, headache and bilateral otorrhea for 3 months. Ear discharge was copious and non-foul smelling. She also had developed limited mouth opening and stiffness in her hands for 1 week. There was no associated fever, nausea vomiting or weight loss. She was previously seen by a number of physicians and otolaryngologists who managed her as a case of otitis media on clinical and radiological basis (figure 1). Her trismus remained unexplained. The history for tetanus vaccination was positive however, there was no booster administration afterwards.

At presentation in our hospital, the examination of ear revealed bilateral purulent, non-foul smelling otorrhea with central perforation in the tympanic membranes. The mouth was trismic and oral cavity showed palatal paralysis. She had nasal voice and systemic examination showed stiffness of hand muscles. Rest of the examination including chvostek and trousseau's signs were unremarkable.

### INVESTIGATIONS

The patient was admitted in the hospital and laboratory tests were drawn including serum calcium (normal), blood cultures (no growth) and ear swabs (*Clostridium tetani*).

CT scan of head and neck was done to look for intracranial complications of otitis media however; it revealed only decreased pneumatization of mastoid cells (figure 1).

### DIFFERENTIAL DIAGNOSIS

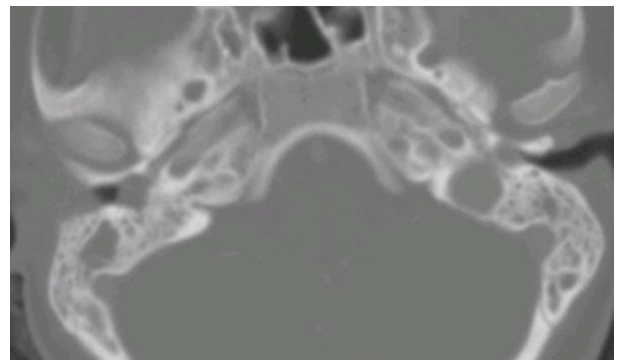
- ▶ Chronic suppurative otitis media with intracranial complication
- ▶ Hypocalcemic tetany.

### TREATMENT

She was started on both local and systemic broad-spectrum antibiotics. But no improvement was seen in 48 h. Considering her neurological features like palatal paralysis and hand stiffness input from paediatric neurologist was also taken and after combined discussion with otolaryngologist, the remote possibility of otogenic tetanus was considered and the patient was then given tetanus toxoid and immunoglobulins. She gradually showed improvement and thereafter, cultures from ear discharge were also reported as positive for *C tetani*.

### OUTCOME AND FOLLOW-UP

The patient gradually showed improvement and was discharged on 6th day of admission. She followed in the clinic at 1 week and then 6 months. She is doing well now and is planned for tympanoplasty.



**Figure 1** Fluid in mastoid air cells bilaterally.

**DISCUSSION**

Otogenic tetanus is a rare entity even though it has been reported long ago in the literature. First case of otogenic tetanus was reported in 1934 by Hyman *et al.*<sup>1</sup> But there is still not much awareness of this disease in developing countries. Otogenic tetanus is preventable neurological disorder, caused by a neurotoxin called as tetanospasmin which is produced by *C tetani*.<sup>2</sup> Considering inadequate immunisation status of developing countries the otogenic tetanus should be a part of differentials supposed by otolaryngologist.

*C tetani* is a gram positive, anaerobic, motile and non-encapsulated rod. It forms spores that can survive in dry soil for years and show severe resistance to boiling water and chemical disinfectants for a few minutes.<sup>3</sup> These spores can be inactivated by heat, disinfectant and a number of antibiotics but the only effective way to kill the spores is to process them through autoclave for 15 min.<sup>4</sup>

Continued otorrhea is a potent source of infection. Mahoney in his study revealed that the considerable devitalised tissue located in the middle ear or mastoid in chronic suppurative otitis media provides an ideal growth medium for anaerobic tetanus organisms.<sup>5</sup> *C tetani* has been reported to exist in the auditory canals in 20% of patients living in tropical areas.<sup>6</sup>

Tetanospasmin gains entry into the nervous system at the myoneuronal junctions of  $\alpha$  motor neurons. This toxin binds to presynaptic inhibitory synapses and thus prevents release of inhibitory neurotransmitters leading to insidious surge in muscle tone and rigidity. It is very important to remember that once this neurotoxin gains access to neurons it can no longer be neutralised.

Incubation period of tetanus may vary from 2 days to a few months. Otogenic tetanus is preventable by immunisation and is common in unimmunised or partially immunised group of people.<sup>7 8</sup>

Treatment of otogenic tetanus is conservative in acute phase and needs collaboration of both otolaryngologist and

paediatrician. Regular ear toilet, pus culture and sensitivity and antibiotic ear drops are taken care of by otolaryngology team, however, paediatric teams make use of systemic antibiotics, tetanus toxoid, antitetanus serum and sedatives. Relapse of otogenic tetanus has also been reported which can have dreadful consequences.<sup>9</sup>

**Learning points**

- ▶ Otogenic tetanus is not an uncommon entity in the developing part of the world but lack of awareness may result in misdiagnosis with grim consequences.
- ▶ These patients initially present with discharging ears, therefore medical practitioners especially otolaryngologists should suspect this diagnosis and initiate appropriate management.
- ▶ Early diagnosis can prevent dreadful complications.

**Competing interests** None.

**Patient consent** Obtained.

**REFERENCES**

1. **Hyman I**, Bower AG. Otogenic tetanus: report of a case. *JAMA* 1934;**103**:480.
2. **Ali M**. Epidemiological study of post neonatal tetanus. *J Pakistan Paediatric Association* 2004;**28**:173–7.
3. **Farthing MJG**, Rolston DDK. *Infectious disease: In Clinical medicine* 1992.
4. **Lorber B**. Gas gangrene and other Clostridium-associated diseases in principle and practice of infectious diseases. Fifth Edition. London: Churchill Livingstone 2000.
5. **Mahoney JL**. Otogenic tetanus in Zaire. *Laryngoscope* 1980;**90**:1196–9.
6. **Hazra AK**, Agnihotri SR. Occurrence of toxigenic *Cl tetani* in ear discharge: report of two cases. *Indian J Med Sci* 1960;**14**:197–200.
7. **Akinbohun A**, Ijaluola G. Otogenic tetanus among children in Ibadan, Nigeria. *Internet J Otorhinolaryngol* 2009;**10**.
8. **Bogomol'ski MR**, Iakushenkova AP, Ozhano S, *et al.* [Otogenic tetanus in children]. *Vestn Otorinolaringol* 2002;**3**:53–4.
9. **Sharma A**, Kapoor S. Relapse in a child with otogenic tetanus. *Trop Doct* 2006;**36**:56–7.

This pdf has been created automatically from the final edited text and images.

Copyright 2012 BMJ Publishing Group. All rights reserved. For permission to reuse any of this content visit <http://group.bmj.com/group/rights-licensing/permissions>.

BMJ Case Report Fellows may re-use this article for personal use and teaching without any further permission.

Please cite this article as follows (you will need to access the article online to obtain the date of publication).

Adeel M, Rajput SA, Awan MS, Arain A. A case of otogenic tetanus. *BMJ Case Reports* 2012;10.1136/bcr.03.2012.5976, Published XXX

Become a Fellow of BMJ Case Reports today and you can:

- ▶ Submit as many cases as you like
- ▶ Enjoy fast sympathetic peer review and rapid publication of accepted articles
- ▶ Access all the published articles
- ▶ Re-use any of the published material for personal use and teaching without further permission

For information on Institutional Fellowships contact [consortiasales@bmjgroup.com](mailto:consortiasales@bmjgroup.com)

Visit [casereports.bmj.com](http://casereports.bmj.com) for more articles like this and to become a Fellow

Keep up to date with all published cases by signing up for an alert (all we need is your email address) <http://casereports.bmj.com/cgi/alerts/etoc>