



THE AGA KHAN UNIVERSITY

eCommons@AKU

Section of Orthopaedic Surgery

Department of Surgery

January 2012

Glenohumeral tuberculous arthritis complicated with beta haemolytic streptococcus: An extraordinary rare association: A case report

Rizwan Haroon Rashid
Aga Khan University

Muhammad Usman Sarwar
Aga Khan University

J. Akhter
Aga Khan University

Shahryar Noordin
Aga Khan University

Follow this and additional works at: https://ecommons.aku.edu/pakistan_fhs_mc_surg_orthop



Part of the [Orthopedics Commons](#), and the [Surgery Commons](#)

Recommended Citation

Rashid, R., Sarwar, M., Akhter, J., Noordin, S. (2012). Glenohumeral tuberculous arthritis complicated with beta haemolytic streptococcus: An extraordinary rare association: A case report. *International Journal of Surgery Case Reports*, 3(5), 164-6.

Available at: https://ecommons.aku.edu/pakistan_fhs_mc_surg_orthop/10



Contents lists available at SciVerse ScienceDirect

International Journal of Surgery Case Reports

journal homepage: www.elsevier.com/locate/ijscr

Glenohumeral tuberculous arthritis complicated with beta haemolytic streptococcus: An extraordinary rare association: A case report

Rizwan Haroon Rashid^{a,*}, Muhammad Usman Sarwar^a, Jaweed Akhtar^b, Shahryar Noordin^a^a Section of Orthopedics, Department of Surgery, Aga Khan University Hospital, Karachi, Pakistan^b Chief Section of Endocrinology, Department of Medicine, Aga Khan University Hospital, Karachi, Pakistan

ARTICLE INFO

Article history:

Received 17 March 2011

Received in revised form 23 August 2011

Accepted 11 September 2011

Available online 23 January 2012

Keywords:

Glenohumeral tuberculous arthritis

Beta haemolytic streptococcus

Septic arthritis

ABSTRACT

INTRODUCTION: Septic arthritis of the glenohumeral joint is a rare entity and its diagnosis is difficult with a superadded infection in the presence of underlying tuberculosis. We report the first case of group B beta haemolytic streptococcal glenohumeral arthritis with underlying tuberculosis.

CASE PRESENTATION: A 40 year old lady previously diagnosed to have poliomyelitis, rheumatoid arthritis, hepatitis C, and diabetes mellitus for the last 10 years, presented to the emergency room with diabetic ketoacidosis. Two weeks prior to presentation she developed fever along with pain and swelling in left shoulder with uncontrolled blood sugars. Local examination of the shoulder revealed global swelling with significant restricted range of motion. MRI showed a large multiloculated collection around the left shoulder joint extending into the axilla, and proximal arm. Urgent arthrotomy performed and about 120 ml thick pus was drained. The patient was started on clindamicin and antituberculous chemotherapy and her symptoms dramatically improved.

DISCUSSION: Bone and joint involvement accounts for approximately 2% of all reported cases of tuberculosis (TB), and it accounts for approximately 10% of the extra pulmonary cases of TB. Tuberculosis of the shoulder joint constitutes 1–10.5% of skeletal tuberculosis. Classical symptoms of fever, night sweats, and weight loss may be absent, and a concurrent pulmonary focus may not be evident in most cases.

CONCLUSION: Despite acute presentation of septic arthritis, in areas endemic for tuberculosis and particularly in an immunocompromised patient, workup for tuberculosis should be part of the routine evaluation.

© 2012 Surgical Associates Ltd. Published by Elsevier Ltd. All rights reserved.

1. Introduction

Tuberculosis of the shoulder joint constitutes 1–10.5% of skeletal tuberculosis.⁶ Septic arthritis of the glenohumeral articulation is a rare entity and its diagnosis is difficult particularly with concomitant tuberculosis. The probability of septic arthritis increases in the presence of immunosuppressant conditions like rheumatoid arthritis,⁴ hepatitis C and diabetes mellitus. We report the first case of group B beta haemolytic *streptococcal* septic glenohumeral arthritis with underlying tuberculosis and a contiguous proximal arm abscess in a middle aged lady.

2. Case report

A 40 year old lady with a body mass index (BMI) of 26, known case of poliomyelitis (since childhood), rheumatoid arthritis (since 8 years), hepatitis C (diagnosed 2 years ago), diabetes mellitus

(10 years), and asthma presented to the emergency room with diabetic ketoacidosis. She denied any past history of tuberculosis. There was a positive history of tuberculosis contact with her mother-in-law diagnosed to have pulmonary Koch's that was fully treated 10 years ago. Constitutional symptoms were reported in the form of malaise, low grade fever for the last 2 weeks, and loss of weight and appetite. Her poliomyelitis was nonprogressive and she was ambulating with the help of bilateral lower limb orthoses. Both rheumatoid arthritis and hepatitis C were quiescent at the time of presentation. Her blood sugars were poorly controlled and she was on regular inhalers for her asthma. Two weeks prior to presentation she started complaining of pain in her left shoulder in addition to fever for which took non steroidal anti-inflammatory drugs and antibiotics with minimal relief. A week prior to admission the patient was found drowsy and her blood sugar checked at home was noted to be 600 mg/dl. She was taken to a local hospital at Hyderabad. After initial resuscitation and stabilization family shifted her to a tertiary care hospital at Karachi. She was admitted under care of medicine in step down unit for management of Diabetic Ketoacidosis. Orthopaedic consult was generated for her left shoulder pain and swelling. Local examination of the left shoulder revealed global swelling with significant restricted range of motion. Radiographs of the left shoulder showed Martini's stage

* Corresponding author. Tel.: +92 12134863190.

E-mail addresses: rizwan.haroonrashid@aku.edu, rizdoc@gmail.com (R.H. Rashid), usman.ali@aku.edu (M.U. Sarwar), jawed.akhtar@aku.edu (J. Akhtar), shahryar.noordin@aku.edu (S. Noordin).

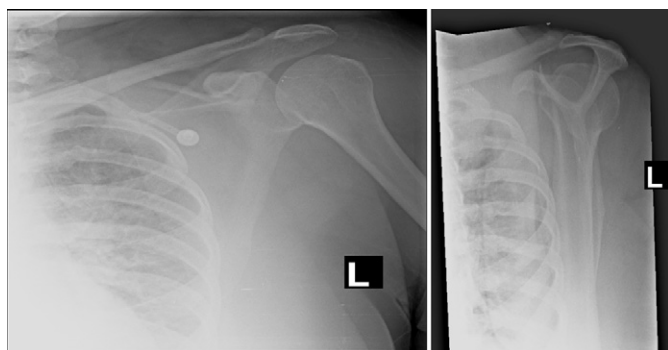


Fig. 1. showing X-ray of left shoulder.

one disease,⁶ with localized osteoporosis but no bony lesion (Fig. 1). Laboratory examination revealed a white blood count (WBC) of $14.5 \times 10^9/l$, erythrocyte sedimentation rate (ESR) 80 mm/h and C-reactive protein (CRP) of 16.1 mg/dl. She did not have any tuberculous pulmonary lesion. With a clinical suspicion of septic arthritis an urgent ultrasound guided aspiration of the left shoulder was requested. A large fluid collection extending inferiorly upto the proximal third of the arm was noted, which on aspiration was noted to be pus.

An urgent MRI scan was done to define the collection and to see any bone involvement. A large multiloculated collection was noted around the left shoulder joint extending into the axilla, and proximal arm (Fig. 2). Urgent left shoulder arthrotomy and left arm incision and drainage was performed using an anterior approach. About 120 ml pus was drained. Deep cultures were sent that grew beta haemolytic streptococcus group B (BHS Gp.B) and on Ziehl-Neelsen stain acid fast bacilli (AFB) were also seen. Blood cultures taken at the time of admission also reported BHS Gp.B. Postoperatively a peripherally inserted central venous catheter (PICC) line was inserted and she was started on antituberculosis chemotherapy (4 drug regimen for first 2 months followed by 2 drugs for 11 months) and intravenous clindamycin. Her response was remarkable in that her blood sugars normalized and with remarkable improvement in left shoulder motion. At the time of the last examination 13 months postop, her wounds had healed without any

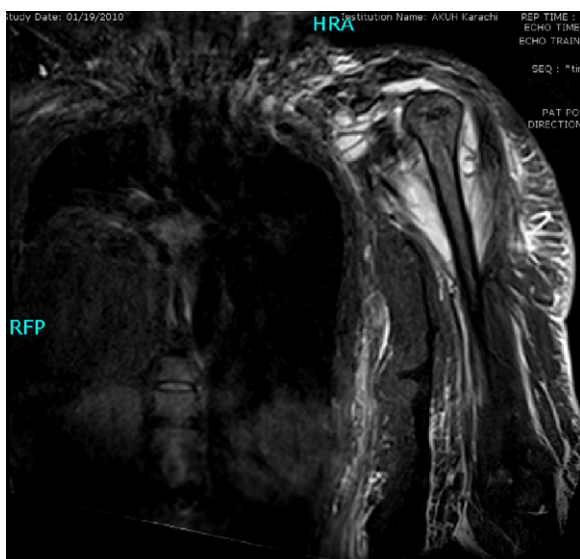


Fig. 2. MRI scan of left shoulder showing purulent collection in left shoulder and chest wall travelling down along proximal humerus.

sinuses and she was pain free. She had achieved shoulder forward flexion of 100° , abduction 110° and external rotation of 10° .

3. Discussion

Bone and joint involvement accounts for approximately 2% of all reported cases of tuberculosis (TB), and it accounts for approximately 10% of the extra pulmonary cases of TB.¹ The articular form of TB usually presents as monoarthritis with a predilection for weight-bearing joints, including intervertebral joints, hips, knees, ankles, and feet, in descending order of frequency.^{2,3}

The presence of concomitant diseases like diabetes and rheumatoid arthritis increases its chance of occurring. Tuberculosis may reach the bone through the bloodstream, through extension from contiguous infection, or spread via draining lymphatics. TB arthritis exhibits a slowly progressive course. Clinical symptoms may not appear until approximately 18 months after the onset of infection.¹ Classical symptoms of fever, night sweats, and weight loss may be absent, and a concurrent pulmonary focus may not be evident in most cases.

To our knowledge this is the first report of shoulder tuberculosis with concomitant beta haemolytic streptococcus group B. The patient's acute beta haemolytic streptococcus group B on her underlying chronic glenohumeral tuberculosis led to decompensation in her symptoms that prompted her to seek treatment. The aim of treatment and followup was biological control of the disease, as well as a painless, mobile shoulder. The clinical signs of healing were decrease in pain and swelling and improvement in postoperative shoulder motion. She did not have any toxicity or resistance to antituberculous drugs.

There have been previous reports of tuberculous osteomyelitis masked by concomitant staphylococcal infection of the shoulder.^{5,6} Usually superinfection is a complication of a draining sinus.⁴ However our patient did not have any draining sinus. Because of her depressed immunosuppressed status the beta haemolytic streptococcus group B in her blood seeded in her left shoulder that already had underlying tuberculosis and tipped her into diabetic ketoacidosis. Her case illustrates the chronic and insidious nature of tuberculosis. Therefore despite acute presentation of septic arthritis, in areas endemic for tuberculosis and particularly in an immunocompromised patient, one should request for acid-fast bacilli workup.

Conflict of interest

None.

Funding

None.

Consent

Written informed consent was obtained from the patient for publication of this case report and accompanying images and can be provided to editor in chief as and when required.

Author contributions

Dr Rizwan and Dr Usman were responsible for the writing and other stuff where as they were supervised on every step by Dr Shahryar and Dr Javed.

References

1. Shams F, Asnis D, Lombardi C. A report of two cases of tuberculous arthritis of the ankle. *J Foot Ankle Surg* 2009;**48**(4):452–6.
2. Lossos IS, Yossepowitch O, Kandel L, Yardeni D, Arber N. Septic arthritis of the glenohumeral joint. A report of 11 cases and review of the literature. *Medicine (Baltimore)* 1998;**77**(3):177–87.
3. Soria LM, Sole JMN, Sacanell AR, Valverde J, Garcia DRE. Infectious arthritis in patients with rheumatoid arthritis. *Ann Rheum Dis* 1992;**51**:402–3.
4. Kapukaya A, Subasi M, Bukte Y, Gur A, Tuzuner T, Kiln N. Tuberculosis of the shoulder joint. *Joint Bone Spine* 2006;**73**(2):177–81.
5. Sinnott 4th JT, Cancio M, Frankle MA, Gustke K, Spiegel PG. Tuberculous osteomyelitis masked by concomitant staphylococcal infection. *Arch Intern Med* 1990;**150**(9):1865–7.
6. Yahia Zayani CB, Daoued L, Tekaya R, Bouebdella M, Abdelmoula L, Kooli M, Chaabouni L, Zouari R. Tuberculous osteomyelitis masked by staphylococcal infection. *Joint Bone Spine* 2009;**76**(4):429.

Open Access

This article is published Open Access at sciedirect.com. It is distributed under the [IJSCR Supplemental terms and conditions](#), which permits unrestricted non commercial use, distribution, and reproduction in any medium, provided the original authors and source are credited.