



THE AGA KHAN UNIVERSITY

eCommons@AKU

Section of Cardiothoracic Surgery

Department of Surgery

May 2011

Aortic dissection or myocardial infarction

Saulat H. Fatimi
Aga Khan University

Maria Mahboob
Aga Khan University

Awais Ashfaq
Aga Khan University

Follow this and additional works at: http://ecommons.aku.edu/pakistan_fhs_mc_surg_cardiothoracic

 Part of the [Surgery Commons](#)

Recommended Citation

Fatimi, S., Mahboob, M., Ashfaq, A. (2011). Aortic dissection or myocardial infarction. *Journal of the Pakistan Medical Association*, 61(5), 502-4.

Available at: http://ecommons.aku.edu/pakistan_fhs_mc_surg_cardiothoracic/11

Case Report

Aortic dissection or myocardial infarction?

Saulat Hasnain Fatimi,¹ Maria Mahboob,² Awais Ashfaq³

Section of Cardiothoracic Surgery, Department of Surgery,¹ Medical Student,^{2,3} Aga Khan University, Karachi, Pakistan.

Abstract

Aortic dissection is a rare and a life threatening event. Classically, aortic dissection presents as sudden, severe chest, back or abdominal pain that is characterized as ripping or tearing in nature. However, a timely diagnosis can be elusive in the event of an atypical presentation. So, a high index of clinical suspicion is mandatory for the accurate and rapid diagnosis of aortic dissection. We report a case of a 56 years old male who presented with signs and symptoms of myocardial infarction and was later found to have aortic dissection. This patient was successfully managed with surgery.

Keywords: Aortic Dissection, Ripping Luminal tear, Chest pain.

Introduction

Aortic dissection is a rare event that is characterized by the separation of the layers of the aortic wall by extraluminal blood that enters it, almost invariably through a luminal tear.¹ The estimated incidence of aortic dissection is 5 to 30 cases per million population per year² and is a life threatening condition with a high mortality in the acute stage that is further accentuated by misdiagnosis and mishandling.³ Moreover, an atypical presentation makes this diagnosis even more difficult. The case we report is an unusual presentation of aortic dissection in an elderly male who presented to us with signs and symptoms of myocardial infarction.

Case Presentation

A 56-year-old gentleman, resident of a rural area and known case of migraine and dyslipidaemia, presented to the emergency department of our hospital with complaints of substernal chest pain, shortness of breath, palpitations and sweating for half an hour. He also complained of cough, orthopnoea and paroxysmal nocturnal dyspnoea. According to him, the pain was constricting in nature and was radiating from apex of the left shoulder across the chest towards the right shoulder.

On physical examination, his pulse was 100 beats per minutes and blood pressure was 96/44 mmHg. On auscultation of the chest, he had bilateral basal crepitations with normal air entry. Cardiovascular examination revealed a pan systolic murmur best heard at the mitral area. Chest X-ray showed signs of pulmonary oedema. At this time he was being treated for congestive heart failure. Suspecting myocardial

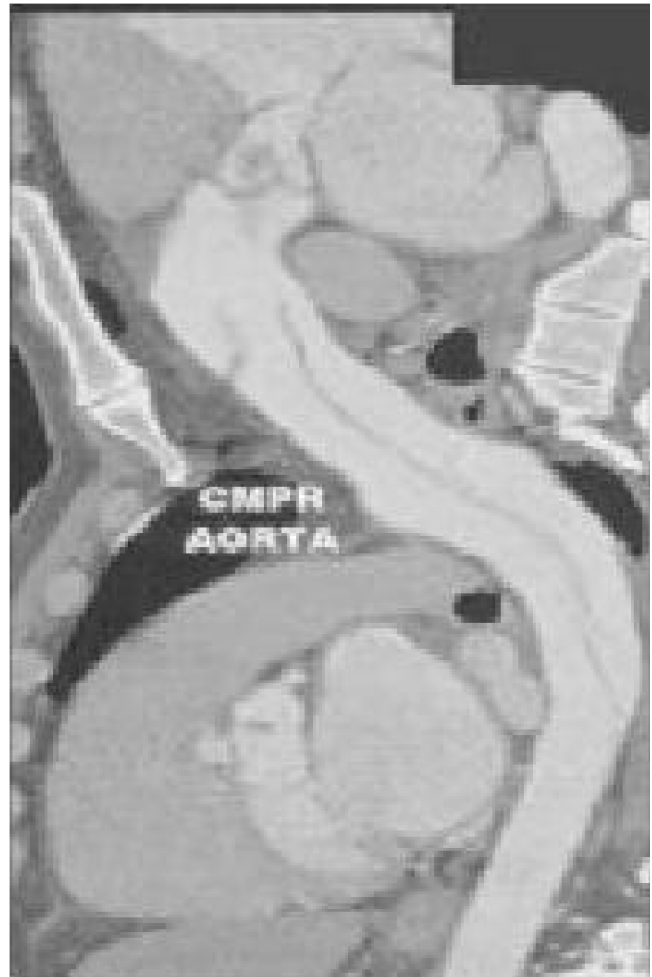


Figure-1: Pre-operative: Acute ascending aortic dissection as seen on CT angiography.

infarction leading to congestive heart failure, an ECG was performed that revealed Q waves in leads V1 and V2. His troponin levels were negative. Patient was planned for cardiac catheterization and angiography. Aortogram was done which showed severe aortic regurgitation and dilated ascending aorta. Coronary arteries could not be engaged because of severely dilated aorta.

Thereafter, transthoracic echocardiography was done that showed prolapsing aortic valve with severe aortic regurgitation, dilated aortic root and ascending aorta, with left ventricular ejection fraction of 55%. Patient was subsequently

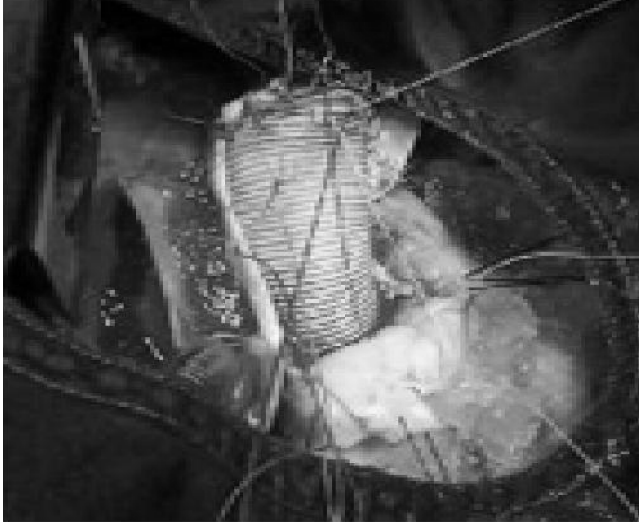

Figure-2: Intra-operative: aortic root replacement.

planned for Computed Tomographic angiography, which showed normal coronary arteries but aortic dissection starting above the cusps and extending down to D8. A diagnosis of acute aortic dissection with severe aortic regurgitation was made. The patient was planned for aortic root replacement with aortic valve conduit and reimplantation of coronary arteries, electively.

Patient was taken to the OR, a median sternotomy was done and cardiopulmonary bypass was instituted. The aorta was found to be bluish in color and the ascending portion was dilated secondary to dissection. Aorta was opened and a large dissection was identified. Entire aorta up to the innominate artery was incised and the proximal and distal ends were identified. The aortic valve was found to be severely regurgitant and valve leaflets were excised completely. The graft was placed, coronary arteries were reimplanted on the new aorta and a prosthetic aortic valve was implanted. Patient was successfully weaned off cardiopulmonary bypass with minimal inotropic support and was shifted to ICU in a stable condition.

Postoperatively, the patient remained stable throughout his hospital course of 10 days. A follow up echocardiogram showed aortic conduit and prosthetic valve functioning normally. Thereafter, patient has maintained a regular follow up and has remained asymptomatic.

Discussion

Although aortic dissection is an uncommon entity, its outcome is frequently fatal and many patients with aortic dissection die before diagnosis. When left untreated, about 33% of patients die within the first 24 hours, and 50% die within 48 hours. The 2-week mortality rate approaches 75% in patients with undiagnosed ascending aortic dissection.⁴

There are several different formats of classification for thoracic aortic dissection; the most commonly used is the Stanford Classification which divides the dissections into 2 types: A - dissection originating in the ascending aorta; B - dissection originating in the aorta distal to left subclavian artery.⁵ Our patient clearly had a type A dissection with two lumina identified from the aortic valve area.

The typical presentation of acute aortic dissection is with sudden onset of chest pain which is usually described as ripping or tearing in nature. The localization of the pain is related to the region in which the intimal rupture occurs. Spreading of the pain may be a sign of progressive dissection.⁶ Patients are typically hypertensive middle-aged or elderly men and the diagnosis should certainly be entertained in patients with such symptoms. While pain is the most common symptom of aortic dissection, more than one third of patients may develop a myriad of symptoms secondary to the involvement of organ systems. Keeping a high index of clinical suspicion is mandatory for the accurate and rapid diagnosis of aortic dissection. The diagnosis of aortic dissection has been missed in up to 38% of patients on initial evaluation.⁶

In our patient, whilst the demographics and the site of pain were typical, the patient was hypotensive and presented with signs and symptoms of congestive heart failure mimicking as myocardial infarction. The coronary arteries were normal and so were the coronary ostia. However, the severe aortic regurgitation had led to the congestive heart failure. Reaching a correct diagnosis with such atypical presentation was very critical in saving the patient.

This case has illustrated the importance of considering aortic dissection as one of the differentials in mind when a patient presents with such signs and symptoms. In this case, the temporal relationship between the onset of pain and associated shortness of breath, palpitations, sweating, orthopnoea and paroxysmal nocturnal dyspnoea would suggest the development of myocardial infarction. The identification of bilateral basal crepitations on chest auscultation and x-ray findings showing pulmonary oedema is another important finding in relation to a diagnosis of aortic dissection.

Once the diagnosis is suspected, it needs to be confirmed by means of a CT scan or trans-oesophageal echocardiography. Treatment options include open replacement of the aorta with reimplantation of arteries with or without valve replacement depending upon the location and extent of the dissection. In a proportion of cases, in particular those with a more chronic history and minimal symptoms, conservative management may be adequate.

In our patient, there was prolapsing aortic valve with severe aortic regurgitation and aortic root and ascending aorta

were also dilated so the cardiothoracic surgeons decided to replace the aortic root with the valve.

Conclusion

We report an unusual mode of presentation of a rare and often fatal condition. This case illustrates the importance of considering aortic dissection as one of the differentials in mind when a patient with signs and symptoms of myocardial infarction presents in the emergency room. It also emphasizes that non-invasive diagnostic methods such as CT and transoesophageal echocardiography should be performed promptly to rule out aortic dissection, which is a very severe life threatening condition.

References

1. DeSanctis RW, Doroghazi RM, Austen WG, Buckley MJ. Aortic dissection. *N Engl J Med* 1987; 317: 1060-7.
2. Khan IA, Nair CK. Clinical, diagnostic and management perspectives of aortic dissection. *Chest* 2002; 122: 311-28.
3. Marek D, Nemeč P, Herman M, Gwozdziejewicz M, Troubil M, Lukl J. Mistakes in dealing with aortic dissection. Lessons from three warning cases. *Biomed Pap Med Fac Univ Palacky Olomouc Czech Repub* 2008; 152: 283-7.
4. Bickerstaff LK, Pairolero PC, Hollier LH, Melton LJ, Van Peenen HJ, Cherry KJ, et al. Thoracic aortic aneurysms: a population-based study. *Surgery* 1982; 92: 1103-8.
5. Daily PO, Trueblood HW, Stinson EB, Wuerflein RD, Shumway NE. Management of acute aortic dissections. *Ann Thorac Surg* 1970; 10: 237-46.
6. Ledbetter S, Stuk JL, Kaufman J A. Helical (spiral) CT in the evaluation of emergent thoracic aortic syndromes. *Radiol Clin N Am* 1999; 37: 575-89.