



THE AGA KHAN UNIVERSITY

eCommons@AKU

---

Section of Cardiothoracic Surgery

Department of Surgery

---

April 2011

# Dual chamber pacemaker implants--a new opportunity in Pakistan for children with congenital and acquired complete heart block

Awais Ashfaq  
*Aga Khan University*

Mansoor Ahmed Khan  
*Aga Khan University*

Mehnaz Atiq  
*Aga Khan University*

Muhammad Muneer Amanullah  
*Aga Khan University*

Follow this and additional works at: [http://ecommons.aku.edu/pakistan\\_fhs\\_mc\\_surg\\_cardiothoracic](http://ecommons.aku.edu/pakistan_fhs_mc_surg_cardiothoracic)

 Part of the [Anesthesiology Commons](#), [Pediatrics Commons](#), and the [Surgery Commons](#)

---

## Recommended Citation

Ashfaq, A., Khan, M., Atiq, M., Amanullah, M. (2011). Dual chamber pacemaker implants--a new opportunity in Pakistan for children with congenital and acquired complete heart block. *Journal of the Pakistan Medical Association*, 61(4), 421-3.

**Available at:** [http://ecommons.aku.edu/pakistan\\_fhs\\_mc\\_surg\\_cardiothoracic/12](http://ecommons.aku.edu/pakistan_fhs_mc_surg_cardiothoracic/12)

## Dual Chamber Pacemaker Implants — A new opportunity in Pakistan for children with congenital and acquired complete heart block

Awais Ashfaq,<sup>1</sup> Mansoor Ahmed Khan,<sup>2</sup> Mehnaz Atiq,<sup>3</sup> Muhammad Muneer Amanullah<sup>4</sup>

Medical Student,<sup>1</sup> Department of Anaesthesia,<sup>2</sup> Department of Pediatrics and Child Health,<sup>3</sup>

Division of Cardiothoracic Surgery, Department of Surgery,<sup>4</sup> Aga Khan University, Karachi.

### Abstract

Implantation of cardiac pacemakers has been practiced for at least five decades with continuous developments of the hardware. The invention of dual chamber pacemakers has initiated a debate concerning its superiority over single chamber ventricular pacemakers. Throughout the world, surgeons have been using dual chambered permanent pacemakers with successful follow ups. However, Pakistan has not yet taken the advantage of such pacemaker devices till now. We report three cases that underwent a dual chamber permanent pacemaker implantation for the first time in children less than 8 kg with successful follow ups.

**Keywords:** Dual chamber pacemaker implants, Congenital heart block, Permanent pacemakers.

### Introduction

Since the first implantation of a cardiac pacemaker in a human in 1958 at the Karolinska Institute, Sweden; technological advances have enhanced the sophistication of cardiac pacemakers.<sup>1</sup> However, till today, the choice of pacemakers has not been based on the results of clinical trials.

There is a continuous debate on ventricular or dual chamber pacemakers regarding its design and usage. Dual chamber pacing maintains atrioventricular synchrony and can better preserve normal physiologic function compared to single chamber ventricular pacemakers.<sup>2</sup> However, dual chamber pacemakers are more expensive, complex to implant, programme and follow up.

Surgeons over the world have used dual chamber pacemakers with successful outcomes, but its use has not been implemented in Pakistan. We report three cases in which a dual chamber permanent pacemaker was implanted successfully for the first time in children less than 8 kilograms weight.

### Case-1:

A 15 month old baby boy weighing 6.5 kg was admitted electively for the Atrial switch (Senning's) procedure. The baby was cyanosed since birth and had a history of recurrent respiratory tract infections.

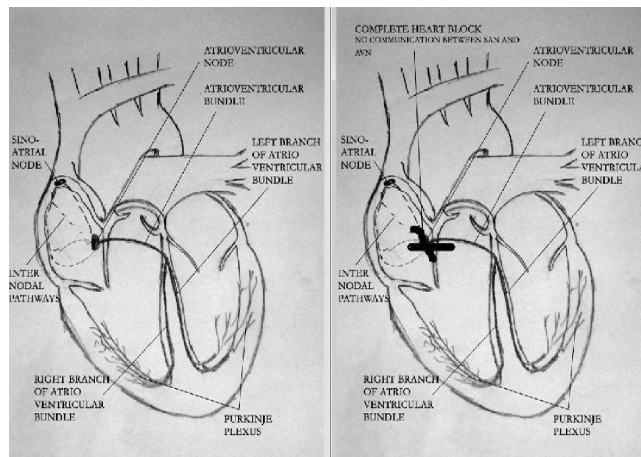


Figure-1a (Left): Normal electrical conduction system of the heart. 1b (Right): Complete Heart Block showing a total disconnection of Sino-atrial Node from Atrioventricular Node.

Echocardiography revealed dextrocardia with situs inversus, transposition of great arteries, sub-pulmonary stenosis, septal hypertrophy, and a 4 mm Atrial Septal Defect (ASD).

The baby was operated for physiological correction of dextro-transposition of the great arteries with Senning procedure. On coming off cardiopulmonary bypass he was in complete heart block requiring temporary epicardial pacing.

The patient was extubated on Day 2 but remained in heart block. Details given in Figure-1a & 1b. He was planned for placement of a dual chambered permanent pacemaker. A right antero-lateral thoracotomy was performed through the 5th inter-costal space to place the epicardial leads to the right atrium and right ventricle. Through a transverse incision in right mid abdomen, a retro-rectus sheath pocket was created to place the generator box. The pacemaker was set at 100 beats per min, patient was extubated on the operation table, and shifted in stable condition to the ICU without inotropic support.

Post-operative echocardiogram revealed normal LV and RV systolic function. The patient had an unremarkable post-op hospital stay and was discharged a week after placement of PPM.

### Case-2:

Our second child was a 5 month old Down's Syndrome boy weighing 4 kg with a complete Atrio-ventricular septal defect (CAVSD) presenting with heart failure. He was admitted electively for CAVSD repair, being referred from Dubai.

The baby underwent complete repair of CAVSD with two patch technique. On coming off cardiopulmonary bypass he was in complete heart block requiring temporary epicardial pacing. Postoperative echocardiogram showed no regurgitation of the AV valves. The patient was shifted to ICU in a stable condition on AV sequential pacing. Four days later, the baby developed intermittent sinus rhythm with heart rate of 50-60/min. This did not improve any further and the child remained in complete heart block. He was planned for implantation of a dual chamber permanent pacemaker.

The second surgery was done through a transverse incision in the left anterior upper quadrant. A pocket was created in the rectus sheath to place the pacemaker generator box. Through a right antero-lateral thoracotomy the pacemaker leads were attached to the right atrium and ventricle. The procedure was uneventful and the child was extubated on the operation table, and shifted to CICU with no inotropic support. The patient was discharged home after a week. He is being followed by the primary physician in Dubai and has remained well.

### Case-3:

A 1 year old baby girl, weighing 8 kg, presented in the ER with fever for three days, vomiting and fits for two days. She was diagnosed to have congenital complete heart block (CCHB) with Stokes Adams attacks. At the time of

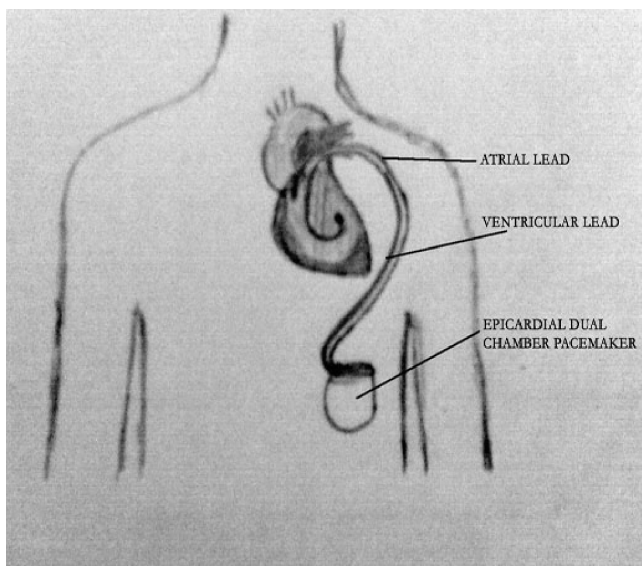


Figure-2: Endovascular Insertion technique of dual chamber pacemaker.

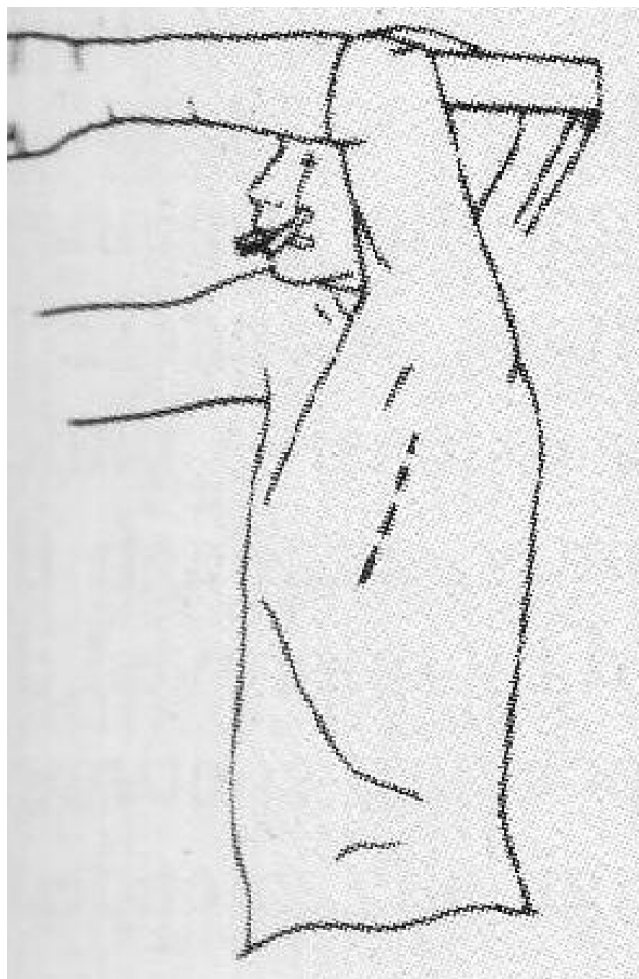


Figure-3: Patient positioning and incision for a vertical mid axillary incisions. The latissimus dorsi muscle is retracted laterally and the serratus anterior muscle split along its muscle fibers to expose the chest wall.

presentation the child was irritable, blood pressure of 100/50, heart rate of 60/min. Clinical examination was unremarkable. Her echo showed dilated left ventricle, with an ejection fraction of 75%. Her electroencephalogram (EEG) was negative for any epileptic activity.

As she was symptomatic from her slow heart rate we planned for placement of a dual chamber permanent pacemaker. Through a right lateral position, a vertical incision (Figure-3) was made along the mid-axillary line in the 4th intercostal space to enter into the pleural cavity to place the epicardial leads to the right atrium and ventricle (Figure-2). The pacing box was positioned inferior to the scapula beneath the latissimus dorsi muscle. The axillary incision scar gets well concealed under the upper arm. In prepubescent female patients, it poses less potential for subsequent breast tissue distortion. Post operatively, the child remained stable with the permanent pacemaker rate maintained at 120-130/min. Her hospital stay was

unremarkable and she was discharged on the 4th post operative day. She is regularly followed-up in the pacemaker clinic and she remains well with her PPM checks being satisfactory.

## Discussion

The number of pacemakers implanted worldwide reached to over 600,000 in 2000.<sup>3</sup> To date, clinical recommendations and guidelines regarding the selection of pacing systems have been based on small clinical studies and retrospective analyses of existing databases.<sup>4</sup>

The first randomized trial comparing ventricular with dual chamber pacing suggested that dual chamber pacing reduces the rate of death, stroke, and heart failure, particularly among patients with sinus-node dysfunction (SND).<sup>5</sup> Maintaining the normal sequence of atrial and ventricular activation tends to optimize ventricular filling and cardiac output. The pacemaker syndrome, a constellation of symptoms associated with asynchronous atrial activation from ventricular pacing, may also be prevented by dual-chamber pacing. A reduction in stroke has also been demonstrated.<sup>5</sup> However, a report by the American College of Cardiology suggests the use of dual chamber pacemaker in cases of SND and AV block where AV synchrony during pacing is desired, or when there is a suspected abnormality of AV conduction or increased risk of future AV block.<sup>6</sup>

All the three cases reported by us encountered complete heart block as a result of either SND or bundle injury involving AV node which made them ideal candidates for dual chamber pacing. They had an unremarkable post-operative recovery and 4 month follow up in each case. There were no failed attempts in any of the reported cases. This is in contradiction to earlier studies that have reported a number of complications involving cardiomyopathy and pacemaker infections.<sup>7</sup> A recent study reported dual chamber devices to be independent predictors of infection with a rate of 0.5% when compared to single chambered devices.<sup>8</sup> The study by Cohen et al also reported trisomy 21 and pacemaker revisions as significant risk factors in the development of infection after pacemaker implantation.<sup>7</sup> Our second patient, a known case of Down's syndrome had an uneventful post-op follow up with no indications for any worsening condition.

The insertion techniques are variable and depend on the surgeon's preference. Epicardial pacing is a common and effective means of pacing in children<sup>9</sup> and are preferred in children weighing less than 15 kilograms. It is also recommended for those with intra-cardiac shunts or those having functionally univentricular anatomy. The use of steroid-eluting leads has led to further decrease in the rate of

complications associated with epicardial pacing. Other means of insertion involve an Endo-cardial pacing that also has a lower complication rate.<sup>10</sup>

However, the issue of dual chamber cost-effectiveness remains to be addressed. The average cost per permanent pacemaker placement was approximately Pak Rupees 294,251.00. As these are the first cases being reported, it is not possible to generalize the cost or to calculate health expenditure to sustain this treatment for life. However it can be predicted that these individuals may have to undergo secondary surgeries for battery replacement after a period of 8-10 years. Otherwise, they are expected to lead a normal and healthy life.

Moreover, in our region this is the first time that a dual chamber pacemaker has been implanted and till today there are only 3 cases. Therefore, the results reported by us cannot be generalized but surely taken into account when such cases are managed.

## Acknowledgement

We thank the author, Awais Ashfaq, for contributing the figures for the manuscript.

## References

1. Elmqvist R, Senning A. Implantable pacemaker for the heart. In: Smyth CN, ed. Medical electronics: proceedings of the Second International Conference on Medical Electronics, Paris, June 24-27, 1959. London: Iliffe, 1960; 253-4.
2. Lamas GA. Physiological consequences of normal atrioventricular conduction: applicability to modern cardiac pacing. *J Card Surg* 1989; 4: 89-98.
3. Lamas GA, Lee KL, Sweeney MO, Silverman R, Leon A, Yee R, et al. Ventricular pacing or dual-chamber pacing for sinus-node dysfunction. *N Engl J Med* 2002; 346: 1854-62.
4. Gregoratos G, Cheitlin MD, Conill A, Epstein AE, Fellows C, Ferguson TB Jr, et al. ACC/AHA guidelines for implantation of cardiac pacemakers and antiarrhythmia devices: a report of the American College of Cardiology/American Heart Association Task Force of Practice Guidelines (Committee on Pacemaker Implantation). *J Am Coll Cardiol* 1998; 31: 1175-209.
5. Andersen HR, Thuesen L, Bagger JP, Vesterlund T, Thomsen PE. Prospective randomised trial of atrial versus ventricular pacing in sick-sinus syndrome. *Lancet* 1994; 344: 1523-8.
6. Gregoratos G, Cheitlin MD, Conill A, Epstein AE, Fellows C, Ferguson TB Jr, et al. ACC/AHA Guidelines for implantation of cardiac pacemakers and antiarrhythmia devices: Executive Summary A Report of the American College of Cardiology/American Heart Association Task Force on practice guidelines (Committee on Pacemaker Implantation). *Circulation* 1998; 97: 1325-35.
7. Cohen MI, Bush DM, Gaynor JW, Vetter VL, Tanel RE, Rhodes LA. Pediatric pacemaker infections: twenty years of experience. *J Thorac Cardiovasc Surg* 2002; 124: 821-7.
8. Nery PB, Fernandes R, Nair GM, Sumner GL, Ribas CS, Menon SM, et al. Device related infection among patients with pacemakers and implantable defibrillators: incidence, risk factors, and consequences. *J Cardiovasc Electrophysiol* 2010; 21: 786-90.
9. Walsh CA, McAlister HF, Andrews CA, Steeg CN, Eisenberg R, Furman S. Pacemaker implantation in children: a 21 year experience. *Pacing Clin Electrophysiol* 1988; 11: 1940-4.
10. Cohen MI, Bush Dm, Vetter VL, Tanel RE, Wieand TS, Gaynor JW, et al. Permanent epicardial pacing in pediatric patients: seventeen years of experience and 1200 outpatient visits. *Circulation* 2001; 103: 2585-90.