



THE AGA KHAN UNIVERSITY

eCommons@AKU

Section of Cardiology

Department of Medicine

February 2011

Carotid cavernous fistula in a patient with coronary artery disease

Omer Ashraf
Aga Khan University

Syed Shahabuddin
Aga Khan University

Muhammad Ehsan Bari
Aga Khan University

Hasanat Sharif
Aga Khan University

Follow this and additional works at: http://ecommons.aku.edu/pakistan_fhs_mc_med_cardiol

 Part of the [Cardiology Commons](#)

Recommended Citation

Ashraf, O., Shahabuddin, S., Bari, M., Sharif, H. (2011). Carotid cavernous fistula in a patient with coronary artery disease. *Journal of the College of Physicians and Surgeons Pakistan*, 21(2), 106-8.

Available at: http://ecommons.aku.edu/pakistan_fhs_mc_med_cardiol/4

Carotid Cavernous Fistula in a Patient with Coronary Artery Disease

Omer Ashraf¹, Syed Shahabuddin², Muhammad Ehsan Bari³ and Hasanat Sharif²

ABSTRACT

Carotid cavernous fistulas are abnormal communications between the carotid and cavernous vasculature, with potential for serious neurological and ocular sequelae. There is considerable literature on the neuro-radiological management of carotico-cavernous fistula depending upon their flow status. The coronary artery bypass grafting (CABG) for coronary artery disease (CAD) is a well established method of revascularization. However, the association of carotid cavernous fistula in presence of CAD is an infrequent occurrence. We present a case of coronary artery disease scheduled for bypass surgery, developed spontaneous bilateral carotid cavernous fistulas, highlighting a unique aspect of association between coronary and carotid disease.

Key words: *Coronary artery disease. Carotid cavernous fistula. Spontaneous. Headache. Proptosis.*

INTRODUCTION

Cardiovascular disease is a leading cause of death.¹ Neurological complications such as stroke are the major morbidity following cardiac surgery and are related to presence of multiple risk factors including aortic atherosclerosis and cerebral embolisation, hypoperfusion, arrhythmias, systemic inflammatory response, depression, genetic factors, anaesthesia and pre-existing cerebrovascular disease.² Carotid cavernous fistula (CCF) can be traumatic, spontaneous or congenital in origin. The invasive endovascular intervention has shown success in majority of cases to relieve symptoms and promote recovery.³ The presence of CCF in a patient with worsening coronary artery disease (CAD) is a rare one, having no direct evidence of cerebral compromise; nevertheless it poses a great challenge to surgeons who face the devastating possibility of neurological events during surgical revascularization on cardiopulmonary bypass. Simultaneous vigilance from perfusionist and anaesthetist is of paramount importance.

This case report describes spontaneous onset of carotico-cavernous fistulas in a patient with known CAD.

CASE REPORT

A 55-year-old gentleman, known case of ischemic heart disease and bronchial asthma presented to the out-

patient clinic with gradually worsening dyspnea and angina. Echocardiography indicated a mildly depressed left ventricular function. Exercise tolerance testing provided evidence of exercise induced myocardial ischemia. Subsequent cardiac catheterization revealed two-vessel coronary artery disease with total occlusion of circumflex artery and 90% stenosis of left anterior descending artery. Coronary artery bypass was therefore, scheduled for cardiac revascularization.

During the pre-operative stay, patient developed spontaneous, severe intractable headache, along with proptosis. There were no other neuro-ocular signs or element of cranial nerve palsy. There was no history of trauma. With a clinical picture of possible neuro-ophthalmic pathology, presumably of vascular origin, carotid Doppler scanning was carried out. This however failed to indicate any evidence of carotid pathology. Subsequent cerebrovascular arteriography revealed bilateral low flow CCF (Figure 1). Owing to the ongoing

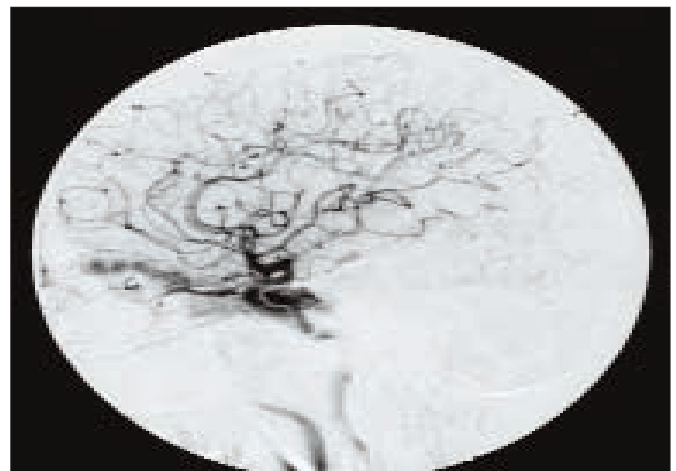


Figure 1: Left carotid angiogram, showing communication of cavernosal portion of internal carotid artery with cavernous sinus.

Department of Surgery¹/CT Surgery²/Neurosurgery³, The Aga Khan University Hospital, Karachi.

Correspondence: *Dr. Hasanat Sharif, Section of Cardiothoracic Surgery, Department of Surgery, The Aga Khan University Hospital, Stadium Road, Karachi-74800.*

E-mail: hasanat.sharif@aku.edu

Received June 18 2010; accepted July 23, 2010.

myocardial ischemia, despite the potential for adverse neurological outcome, cardiopulmonary bypass was under taken. Due to the decline in mean pressures seen with induction of cardiopulmonary bypass, as a precautionary measure, perfusion pressures were kept on higher side to allow adequate blood flow. Coronary artery grafting was carried out successfully with no further neurovascular compromise. Patient tolerated the procedure well, with no operative complications.

Patient documented a successful recovery from the operation. He was then referred to interventional radiology for prospective embolization of the fistula. He has been regularly followed-up in clinics at this institution without any evidence of neurological sequelae. His management has been conservative with symptomatic relief of headache and reassurance.

DISCUSSION

The relationship between CAD and cerebrovascular disease in the form of carotid artery stenosis is well established, with emphasis on combined surgical management. However, the association between CAD and cerebral vascular malformation, especially carotid cavernous fistula is rare.

A carotid cavernous fistula is an abnormal communication between a branch of the carotid artery and the cavernous sinus generating an arteriovenous communication that can cause severe ocular damage. Classification is based upon cause (spontaneous or traumatic), flow velocity (high or low), or pathogenesis (direct or indirect). Direct types are usually related to trauma and present with high flow velocity, while indirect CCFs lack clear etiological factors and have slower flux. Rupture of internal carotid artery in the cavernous sinus may lead to high flow shunting of blood at arterial pressure into the normally low-pressure venous congestion, cranial neuropathies, glaucoma, conjunctival chemosis and generalized arterial edema. The fistula results in haemodynamic changes, lowering arterial pressure and raising venous pressure, the net effect of which is diminished ocular blood flow which may be of sufficient magnitude to produce ocular necrosis.

General clinical presentation features include bruit, headache, loss of vision, altered mental status and neurological deficits. There may be chemosis and extra-ocular palsies. Spontaneous fistula, though, as in this case, may have somewhat atypical findings.⁴

The diagnosis and therapeutic approach towards CCF is conventionally and interdisciplinary one, involving both ophthalmology and interventional neuro-radiology guidance. If a fistula is suspected, angiography is indispensable, both for diagnostic and classification purposes, with an unfavorable spontaneous

course predisposing towards intracranial haemorrhage.⁵ Ultrasonographic assessment is a complementary tool in the assessment and follow-up of these patients.

Management approach relies on clinical and angiographic features, with spontaneous gradual resolution seen in a number of cases. Therapeutic approaches consist of conservative manual compression of the carotid artery and invasive endovascular treatment. Transvenous embolisation is used for indirect (dural) and transarterial embolisation is employed for direct CCF. Interventional occlusion affords high efficacy and low complications.^{5,6} Emphasis of clinical and imaging follow-up is paramount in order to delineate any progression or regression of clinical condition caused by more arteriovenous flow or spontaneous thrombosis in the healing process, respectively.⁷

In this case, presence of CAD and worsening of cardiac symptoms with predisposition to myocardial infarction deemed it necessary to address unstable cardiac status first. Neurological opinion was sought and it was decided to observe the CCF since it was believed to have low potential for causing neurological sequel. Indeed whilst 90% of medium and high flow CCFs warrant neurological treatment for the gravity of the symptoms, only 25% of the low flow CCFs require it, with the later being initially treated conservatively.⁸

However, an understanding of anatomy, physiology and cerebral blood flow in such cases should be kept in mind in order to conduct cardiopulmonary bypass with adequate flow and safety.

As this association of CAD and CCF is a rare entity, its effect on cerebral sequelae is not well investigated. Therefore, optimization of haemodynamics by anaesthetist at induction (mean pressures were consistently kept above 60 mmHg) and maintenance of optimal perfusion pressure during cardiopulmonary bypass was ensured as precautionary measures. This report indicates that small CCFs with low flow may be left alone and the primary emphasis should be on stabilization of cardiac status. Surgical revascularization can therefore, be carried out without an associated increased risk of postoperative neurological morbidity.

REFERENCES

1. World Health Organization. Cardiovascular disease (CVDs) [Internet]. 2005. Available from: www.who.int/mediacentre/factsheets/fs317/en/print.html
2. Newman MF, Mathew JP, Grocott HP, Mackensen GB, Monk T, Welsh-Bohmer KA, *et al.* Central nervous system injury associated with cardiac surgery. *Lancet* 2006; **368**:694-703.
3. Kirsch M, Henkes H, Liebig T, Weber W, Esser J, Golik S, *et al.* Endovascular management of dural carotid-cavernous sinus fistulas in 141 patients. *Neuroradiology* 2006; **48**:486-90. Epub 2006 Apr 26.

4. Calzolari F, Ravalli L. [Spontaneous carotid-cavernous fistula: correlations between clinical findings and venous drainage]. *Radiol Med (Torino)* 1997; **93**:358-66. Italian.
5. Solymosi L. Treatment of carotid cavernous fistulas. *Klin Monatsbl Augenheilkd* 2004; **221**:904-91.
6. Phatouras CC, Meyers PM, Dowd CF, Halbach VV, Malek AM, Higashida RT. Carotid artery cavernous fistula. *Neurosurg Clin N Am* 2000; **11**:67-84, viii.
7. de Keizer R. Carotid-cavernous in relation to visual impairment and morbidity. *Orbit* 2003; **22**:121-42.
8. Montane D, Casado J. Treatment of carotid cavernous fistulas. *Rev Neurol* 1997; **25**:1963-67.

