



THE AGA KHAN UNIVERSITY

eCommons@AKU

Department of Pathology and Laboratory Medicine

Medical College, Pakistan

March 2008

Dubin-Johnson syndrome

Aziz-un Nisa
Aga Khan University

Zubair Ahmad
Aga Khan University

Follow this and additional works at: http://ecommons.aku.edu/pakistan_fhs_mc_pathol_microbiol

 Part of the [Pathology Commons](#)

Recommended Citation

Nisa, A., Ahmad, Z. (2008). Dubin-Johnson syndrome. *Journal of the College of Physicians and Surgeons Pakistan*, 18(3), 188-9.
Available at: http://ecommons.aku.edu/pakistan_fhs_mc_pathol_microbiol/15

Dubin-Johnson Syndrome

Aziz-un-Nisa and Zubair Ahmad

ABSTRACT

A young man presented with recurrent episodes of mild jaundice. Apart from conjugated hyperbilirubinemia, other liver function tests were always normal. Clinical suspicion of Dubin-Johnson syndrome was raised. Liver biopsy showed diffuse deposition of coarse granular dark brown pigment in hepatocytes. Dubin-Johnson syndrome is a benign condition, which results from a hereditary defect in biliary secretion of bilirubin pigments, and manifests as recurrent jaundice with conjugated hyperbilirubinemia. The defect is due to the absence of the canalicular protein MRP2 located on chromosomes 10q 24, which is responsible for the transport of biliary glucuronides and related organic anions into bile. No treatment is necessary and patients have a normal life expectancy.

Key words: *Dubin-Johnson syndrome. Conjugated hyperbilirubinemia. Liver biopsy. Brown pigment.*

INTRODUCTION

Dubin-Johnson syndrome is a benign autosomal recessive condition in which biliary secretion of bilirubin pigment is defective. The defect is due to the absence of the canalicular protein MRP2 located on chromosomes 10q 24, which is responsible for the transport of biliary glucuronides and related organic anions into bile.¹ The hepatocytes contain diffusely a coarsely granular dark brown pigment.² The liver is otherwise normal. Apart from chronic or recurrent jaundice of fluctuating intensity, most patients are asymptomatic and have a normal life expectancy.³

This case report describes Dubin-Johnson syndrome in a 28-year-old male with jaundice since childhood.

CASE REPORT

A 28-year-old gentleman from Sahiwal presented in November 2006 with a history of recurrent mild jaundice since childhood. He was pale and jaundiced. Abdominal examination was unremarkable. Liver was not enlarged. Rest of physical examination was also unremarkable.

His liver function tests performed at the time showed a total serum bilirubin level of 4.2 mg/dl (normal upto 1.00 mg/dl, and conjugated bilirubin level 3.6 mg/dl (normal upto 0.20). The liver enzymes, total proteins and albumin: globulin ratio were normal. Urine examination showed increased urobilinogen. Urine for Bence Jones Protein was negative. Peripheral blood film was unremarkable with a normal reticulocyte count.

Department of Pathology and Microbiology, The Aga Khan University Hospital, Karachi.

Correspondence: *Dr. Zubair Ahmad, Assistant Professor, Histopathology, Department of Pathology and Microbiology, The Aga Khan University Hospital, Stadium Road, P.O. Box 3500, Karachi-74800- Pakistan.*

E-mail: zubair.ahmad@aku.edu

Received September 22, 2007; accepted January 26, 2008.

The patient at that time had a copy of blood tests performed earlier. That also showed increased serum bilirubin and increased conjugated bilirubin, while all other liver function tests were negative. Diagnosis of conjugated hyperbilirubinemia was made, and with a suspicion of Dubin-Johnson syndrome, liver biopsy was performed.

We received the single linear core of liver tissue submitted for histopathological examination, had normal lobular architecture of the liver on routine H and E staining. A coarsely granular dark brown pigment was diffusely present in the hepatocytes throughout the core of liver tissue (Figure 1), although it was more heavily concentrated in the perivenular zones. The brown pigment was positive with the periodic acid schiff (PAS) stain and was resistant to diastase. It also showed positivity with the Masson Fontana stain (Figure 2). Iron (Perl) and bile stains were negative. Mild chronic non-specific portal and periportal inflammation was also present. No evidence of granuloma or malignancy was seen. Based on the clinical history and histopathological findings on the liver biopsy, a diagnosis of Dubin-Johnson syndrome was made.

Since no treatment is required in this condition, no specific treatment was administered.

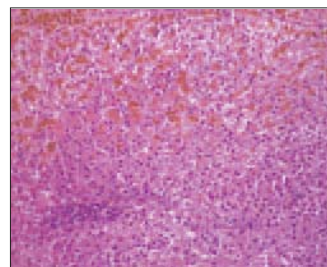


Figure 1: Coarsely granular dark brown pigment diffusely present in hepatocytes.

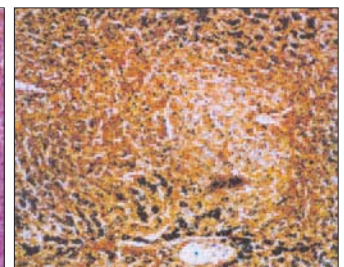


Figure 2: Pigment showed positivity with Masson Fontana stain.

DISCUSSION

Dubin-Johnson syndrome results from a hereditary defect in hepatocellular excretion of bilirubin glucuronides across the bile canalicular membrane.³ Inheritance is autosomal recessive, with reduced penetrance in females.⁴ The underlying defect is the complete absence of the canalicular multispecific organic anion transporter (CMOAT), which is the same as the human multidrug-resistance protein 2 (MRP2).^{5,6} The gene is localized to chromosome 10q 24.¹ The canalicular protein is responsible for the transport of bilirubin glucuronides and related organic anions into bile.³

The liver is darkly pigmented owing to a diffuse accumulation of a coarsely granular brown pigment in hepatocyte cytoplasm, appearing grey to black in color grossly. The pigment shares some physicochemical properties with lipofuscin and melanin, being oil red O positive (in frozen sections), variably positive with PAS stain, and stains black with the Fontana stain.⁷

The differential diagnosis of liver biopsies with dark pigment mainly includes iron in iron overload states (positive with per's iron stain); and lipofuscin (or wear and tear pigment), which is also PAS positive but is finely rather than coarsely granular. Electron microscopy reveals that this pigment is lysosomal; however, it is not bilirubin pigment but rather appears to be composed of polymers of epinephrine metabolites.^{8,9}

Ultrastructurally liver biopsies show accumulation of membrane bound, electron dense lysosomal granules within the cytoplasm of hepatocytes. These were located mainly in the centrilobular region, which corresponded to the pigment deposits seen under light microscope.⁹

Patients with Dubin-Johnson syndrome present with conjugated hyperbilirubinemia (ranging from 2 to 5 mg/dl), but have normal liver enzymes and show no other evidence of hepatic dysfunction. It is rare in infancy, age of onset may be upto the fifties.⁷

In patients with repeated bouts of mild jaundice since childhood, if liver function tests only show raised serum bilirubin levels without abnormalities in liver enzymes, the next line of investigation is to determine, whether

hyperbilirubinemia is unconjugated or conjugated. In case of former, peripheral blood count and reticulocyte count are performed. If these are positive, the patient is investigated for hemolytic disorders; if negative, possibility of Gilbert's syndrome is raised. In case of conjugated hyperbilirubinemia, the possibility of Dubin-Johnson syndrome and Rotor's syndrome is raised.¹⁰

REFERENCES

1. van Kuijk MA, Kool M, Merckx GF, Geurts van Kessel A, Bindels RJ, Deen PM, *et al.* Assignment of the canalicular multispecific organic anion transporter gene (CMOAT) to human chromosome 10q 24 and mouse chromosome 19D2 by fluorescent *in situ* hybridization. *Cytogenet Cell Genet* 1997; **77**: 285-7.
2. Knisely AS, Crawford JM. Inherited and developmental disorders of the liver. In: Odze RD, Goldblum JR, Crawford JM, (edi). *Surgical pathology of the GI tract, liver, biliary tract and pancreas*. Philadelphia: *Saunders*; 2004:p.979-98.
3. Crawford JM. The liver and biliary tract. In: Kumar V, Abbas AK, Fausto N, (edi). *Robbins and Cotran pathologic basis of disease*. 7th ed. Philadelphia: *Saunders*; 2004:p.887-8.
4. Wolkoff AW, Cohen LE, Arias IM. Inheritance of the Dubin - Johnson syndrome. *N Engl J Med* 1973; **288**: 113-7.
5. Tsujii H, Konig J, Rost D, Stockel B, Leuschner U, Keppler D. Exon-intron organization of the human multidrug-resistance protein 2 (MRP2) gene mutated in Dubin-Johnson syndrome. *Gastroenterology* 1999; **117**:653-60.
6. Machida I, Wakusawa S, Sanae F, Hayashi H, Kusakabe A, Ninomiya H, *et al.* Mutational analysis of the MRP2 gene and long-term follow-up of Dubin-Johnson syndrome in Japan. *J Gastroenterol* 2005; **40**:366-70.
7. Ishak KG, Sharp HL, Schwarzenberg SJ. Metabolic errors and liver disease. In: MacSween RNM, Burt AD, Portmann BC, Ishak KG, Scheuer PJ, Anthony PP, (edi). *Pathology of the liver*. 4th ed. New York: *Churchill Livingstone*; 2002:p.221.
8. Kitamura T, Alroy J, Gatmaitan Z, Inoue M, Mikami T, Jansen P, *et al.* Defective biliary excretion of epinephrine metabolites in mutant (TR-) rats: relation to the pathogenesis of black liver in the Dubin-Johnson syndrome and corriedale sheep with an analogous excretory defect. *Hepatology* 1992; **15**:1154-9.
9. Sobaniec-Lotowska ME, Lebensztejn DM. Ultrastructure of Kupffer cells and hepatocytes in the Dubin-Johnson syndrome: a case report. *World J Gastroenterol* 2006; **12**: 987-9.
10. Chapman RW, Collier ID, Hayes PC. Liver and biliary tract disease. In: Boon NA, Colledge NR, Walker BR, Hunter JAA, (edi). *Davidson's principles and practice of medicine*. 20th ed. Edinburgh: *Churchill Livingstone*; 2006:p.945.

.....☆.....