



THE AGA KHAN UNIVERSITY

eCommons@AKU

Department of Pathology and Laboratory Medicine

Medical College, Pakistan

August 2009

Vaginal clear cell adenocarcinoma with associated Mullerian duct anomalies, renal agenesis and situs inversus: report of a case with no known in-utero exposure with diethyl stilboestrol

Zeeshan-ud-din
Aga Khan University

Aamir Ahsan
Aga Khan University

Follow this and additional works at: http://ecommons.aku.edu/pakistan_fhs_mc_pathol_microbiol

 Part of the [Pathology Commons](#)

Recommended Citation

Zeeshan-ud-din, ., Ahsan, A. (2009). Vaginal clear cell adenocarcinoma with associated Mullerian duct anomalies, renal agenesis and situs inversus: report of a case with no known in-utero exposure with diethyl stilboestrol. *Journal of the Pakistan Medical Association*, 59(8), 568-70.

Available at: http://ecommons.aku.edu/pakistan_fhs_mc_pathol_microbiol/35

Case Report

Vaginal clear cell adenocarcinoma with associated Müllerian duct anomalies, renal agenesis and situs inversus: Report of a case with no known in-utero exposure with Diethyl stilboestrol

Zeeshan-ud-din, Aamir Ahsan

Section of Histopathology, Department of Pathology & Microbiology, The Aga Khan University Hospital, Karachi.

Abstract

A 27 year old female presented with two months history of continuous vaginal bleeding. On evaluation, she was diagnosed as a case of vaginal clear cell adenocarcinoma (VCCA) along with associated Müllerian duct anomalies including didelphys uterus with double vagina; left sided renal agenesis and situs inversus. Although VCCA is strongly linked to in-utero exposure with Diethyl stilboestrol (DES), this patient had no known history regarding such exposure. Also, only a few cases have been described in the literature in which this tumour was seen in association with Müllerian duct anomalies and renal agenesis; in the absence of known DES exposure.

Introduction

Clear cell adenocarcinoma is an uncommon malignancy involving vagina which has been strongly linked to in-utero exposure of the female foetus with Diethyl stilboestrol (DES).^{1,2} DES exposure is also associated with Müllerian duct anomalies including vaginal adenosis, cervical ectropion and cervicovaginal ridges.³ Primary vaginal clear cell adenocarcinoma unrelated to DES is a rare finding.¹ However, presence of this tumour in association with Müllerian duct anomalies along with renal agenesis and situs inversus, in the absence of DES exposure is even rarer. We present a case of 27-year-old female presented with continuous bloody vaginal discharge that was later diagnosed to have vaginal clear cell adenocarcinoma along with congenital anomalies including didelphys uterus with double vagina, left sided renal agenesis and situs inversus. There was no known in-utero exposure with DES in this patient.

Case Report

A 27-year-old woman, married for 3 months, presented with continuous bloody vaginal discharge for the last two months. The patient also had a history of irregular prolonged menstrual cycle for the last one year.

Initial physical examination showed situs inversus. Ultrasound showed bicornuate uterus with right horn of uterus measuring 5.2 X 3.8cm and left horn measuring 5.9

X 3.9cm. Left kidney was found to be absent with compensatory enlargement of the right kidney. Haematometra in the body and cervix of the left uterine horn suggested a vaginal septum on the left side. Vaginal examination showed no definitive cervix, however, on the left side, a pin-hole dimple was identified with oozing of blood stained fluid and cheesy suspicious looking material, which was sent for histopathology with the clinical suspicion of malignancy versus retained products of conception. The specimen received for histopathology was coded as "Tissue from the pouch below the uterus". It consisted of multiple light to dark brown, friable and irregular soft tissue fragments, collectively measuring 12 X 12 X 3cm approximately. No gestational sac, foetal parts or chorionic villi were grossly identified and representative sections were submitted for microscopic examination. Histopathology of this tissue showed fragments of a cellular neoplastic lesion with extensive haemorrhage and necrosis. The tumour cells were large and polygonal and were arranged in sheets, nests and tubules. The cells had abundant, clear to finely granular cytoplasm and distinct cellular borders. The nuclei were large, pleomorphic and had coarse chromatin and prominent nucleoli. Abundant cytoplasmic glycogen was seen on PAS ± diastase special stains. Scattered mitotic figures were also seen. There were areas showing prominent hobnailing of the tumour cells (Figure-1). On immunohistochemistry, tumour cells showed positivity for cytokeratin AE1/AE3 and negativity for vimentin, CD10, placental alkaline phosphatase (PLAP) and CD117 (c-kit). No normal tissue was identified to determine the possible origin of this neoplasm. Based on the morphological and immunohistochemical features, a diagnosis of clear cell adenocarcinoma was made and clinical correlation was recommended for determining the site of biopsy as these tumours can arise from endometrium, cervix or vagina.

With these differential diagnosis, a laparotomy and possible Wertheim's hysterectomy was scheduled. Peroperatively, two uteri were identified opening in a single dilated pouch like structure which was later found out to be the left vagina as this patient had didelphys uterus with double vagina. Both adnexae and bowel loops were normal

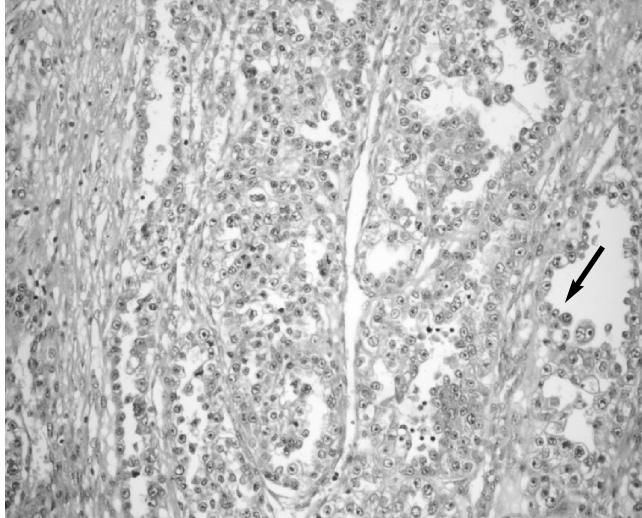


Figure-1: Vaginal clear cell adenocarcinoma showing tubules lined by polygonal clear cells with prominent hobnailing (arrow).

grossly. Pelvic lymph nodes were enlarged. Wertheim's hysterectomy with partial vaginectomy and pelvic lymph node dissection was carried out and specimen was sent for histopathology. Both the ovaries were conserved.

Grossly the specimen consisted of two uteri, two cervixes and two vaginas along with bilateral external iliac and obturator lymph nodes. Right sided uterus, cervix and vagina measured 9.5 X 4 X 2.5cm in the greatest

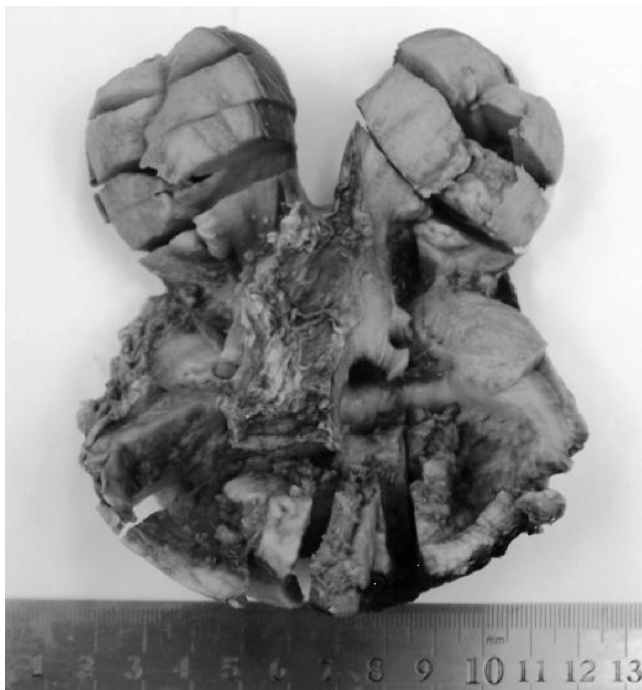

Figure-2: Didelphys uterus with double vagina showing clear cell adenocarcinoma involving left vagina (arrow).

dimensions. Left sided uterus, cervix and vagina measured 10 X 3.5 X 2.5cm in the greatest dimensions. Grossly the tumour was involving the upper left vagina, and was grayish brown, fungating in appearance and was reaching up to the inferior resection margin (Figure-2). The tumour measured 4.4 X 4cm in the greatest dimensions. The left vagina had a blind lower end with a pin-hole opening in the septum through which it was communicating with the grossly unremarkable vagina on the right side. Apart from a small myometrial nodule in the right uterus, both of the uteri, cervixes and right vagina were grossly unremarkable.

Tumour of similar histology as described earlier in the biopsy specimen was seen involving the left vaginal mucosa and underlying fibromuscular tissue however it was not extending to the serosa. The inferior resection margin was microscopically positive for the tumour as well. Sections from both of the uteri, cervixes, right vagina and both fallopian tubes were tumour free. Out of nine pelvic lymph nodes sent for histopathology, only one was involved by metastatic clear cell adenocarcinoma.

Discussion

Clear cell adenocarcinoma most commonly involves ovary, cervix, and urinary tract including kidney.¹ Vaginal clear cell adenocarcinomas (VCCA) account for only 5-10% of all vaginal cancers, the vast majority being squamous cell carcinoma.² VCCA most commonly involves the anterior wall of the upper third of vagina, corresponding to the most frequent site of adenosis, with which it has been associated. The tumour size is variable ranging from microscopic to large. Most of the larger tumours are polypoidal or nodular in appearance and are mostly superficially invasive. Microscopically, the tumour is characterized by solid sheets of clear cells, the clear appearance of cytoplasm being caused by dissolution of glycogen during the processing of the specimen. A second pattern is characterized by tubules and cysts lined by hobnail cells, and by flat cells, or by cells that resemble Müllerian type epithelium to varying degrees.³ In our case, tumour was fungating in gross appearance and was involving the upper part of vagina. The histopathological examination revealed a classical pattern of VCCA including clear cells showing hobnailing.

VCCA is most commonly related to in-utero diethylstilbestrol (DES) exposure.^{1,2,4,5} DES is a synthetic estrogen which was prescribed for threatened or repeated abortions from 1940's to early 1970's.⁶ The absolute risk of clear cell adenocarcinoma of vagina or cervix in the daughters of DES-exposed mothers is 1 in 1000.⁶ Primary VCCA is a rare entity except for this well-known association.¹ There are multiple reported cases of VCCA in which there was no in-utero exposure to DES.^{1,7,8} Apart

from clear cell adenocarcinoma, a number of non-neoplastic changes have also been identified in the genital tract of DES-exposed women, such as adenosis, cervical ectropion, cervicovaginal ridges, and structural anomalies of uterine corpus and fallopian tube.³ In our case, although there was no known history of in-utero DES exposure, still Müllerian duct anomalies such as didelphys uterus with double vagina, were identified along with left sided renal agenesis and situs inversus. The association between Müllerian duct anomalies and renal agenesis has been well documented. Müllerian duct anomalies occur in 1-15% of women associated with renal anomalies especially agenesis or ectopia.⁹ However, like our cases only a few cases have been described in the literature in which a coexistence of such anomalies with VCCA in the absence of any known DES exposure was seen. One such case has been reported by Satou and Takasu⁸ in a 38-year-old female who had not been exposed to DES in-utero. Their patient had a congenital malformation of the genital tract; the uterus was bicornuate and the urinary tract exhibited unilateral renal agenesis.⁸ In another study, Nordqvist et al⁷ reviewed twenty one cases of vaginal and cervical clear cell adenocarcinoma, out of which thirteen had no prior DES exposure. In their study, two of the non-DES related cases had coexisting congenital malformations with double uterus and vagina and unilateral renal agenesis as seen in our case.⁷ Ott et al¹⁰ reported a case of clear cell adenocarcinoma of the upper vagina in a 17-year-old DES non-exposed German girl, who had a history of hypoplasia of the left kidney with an ectopic termination of the ureter in the upper vagina. They have suggested that congenital anomaly of the ureter interfering with the development and the differentiation of the distal Müllerian duct and its epithelium might have provided a similar histological basis for carcinogenesis in their patient to that in those exposed to DES.¹⁰

Conclusion

Based on the cases described previously and the one reported here, it is presumed that a separate group of VCCA exists which is associated with Müllerian duct anomalies in the absence of DES exposure. Also, renal agenesis may directly or indirectly predispose to VCCA. Whether these associations are causal or incidental remains to be determined.

References

1. Guzin K, Eser SK, Yigit A, Zemheri E. Primary clear cell carcinoma of the vagina that is not related to in utero diethylstilbestrol use. *Gynecol Surg* 2006; 3:281-4.
2. Tanaka H, Tabata T, Yanase H, Nishiyama M, Yamawaki T, Toyoda N. Clear cell adenocarcinoma of the vagina in a young female, treated by combination chemotherapy (local and systemic chemotherapy), complicated with chromosomal abnormality. *Gynecol Oncol* 1994; 55: 259-64.
3. Robert JK. *Blaustein's Pathology of Female Genital Tract*. 5th ed. New Delhi (India): Springer 2002; pp 185-7.
4. Novoa Vargas A, Grados Garcia C, Bustillos de Cima R, Malagón Millan B. Vagina cancer in a young woman exposed to diethylstilbestrol: case report and literature review. *Ginecol Obstet Mex* 2005; 73: 666-73.
5. Robboy SJ, Scully RE, Welch WR, Herbst AL. Intrauterine diethylstilbestrol exposure and its consequences: pathologic characteristics of vaginal adenosis, clear cell adenocarcinoma, and related lesions. *Arch Pathol Lab Med* 1977; 101: 1-5.
6. Treffers PE, Hanselaar AG, Helmerhorst TJ, Koster ME, van Leeuwen FE. Consequences of diethylstilbestrol during pregnancy; 50 years later still a significant problem. *Ned Tijdschr Geneesk* 2001; 145: 675-80.
7. Nordqvist SR, Fidler WJ Jr, Woodruff JM, Lewis JL Jr. Clear cell adenocarcinoma of the cervix and vagina. A clinicopathologic study of 21 cases with and without a history of maternal ingestion of estrogens. *Cancer* 1976; 37: 858-71.
8. Satou Y, Takasu K. Clear cell adenocarcinoma in duplicated and imperforated vagina with didelphys uterus a case report. *Journal of Kyoto Prefectural University of Medicine* 1990; 99: 725-38.
9. Trivedi AV, Vaishya KB, Dodiya CK, Gandhi SP, Pandya AJ. Two unique cases of atypical mullerian duct development. *Indian J Radiol Imaging* 2006; 16:887-9.
10. Ott MM, Rehn M, Müller JG, Gruss A, Martius J, Steck T, Muller-Hermelink HK. Vaginal clear cell carcinoma in a young patient with ectopic termination of the left ureter in the vagina. *Virchows Archiv* 1994; 445-8.