



THE AGA KHAN UNIVERSITY

eCommons@AKU

Department of Paediatrics and Child Health

Division of Woman and Child Health

May 2008

A family with acute intermittent porphyria

Abdul Gaffar Billoo
Aga Khan University

Saira Waqar Lone
Aga Khan University

Follow this and additional works at: http://ecommons.aku.edu/pakistan_fhs_mc_women_childhealth_paediatr



Part of the [Pediatrics Commons](#)

Recommended Citation

Billoo, A., Lone, S. (2008). A family with acute intermittent porphyria. *Journal of the College of Physicians and Surgeons Pakistan*, 18(5), 316-8.

Available at: http://ecommons.aku.edu/pakistan_fhs_mc_women_childhealth_paediatr/12

A Family with Acute Intermittent Porphyrria

Abdul Gaffar Billoo and Saira Waqar Lone

ABSTRACT

Porphyrias are inherited defects in heme metabolism that result in excessive secretion of porphyrins and porphyrin precursors. Porphyrias can be classified into acute, (neuropsychiatric), cutaneous and mixed forms.¹ There are seven main types of porphyrias; acute intermittent porphyria and plumboporphyria are predominantly neuropsychiatric; congenital erythropoietic porphyria, porphyria cutanea tarda and erythropoietic protoporphyria have predominantly cutaneous manifestations and hereditary coproporphyria and variegate porphyria are classified as mixed as they both have neuropsychiatric and cutaneous features.² They cause life-threatening attacks of neurovisceral symptoms that mimic many other acute medical and psychiatric conditions. Lack of clinical recognition often delays effective treatment, and inappropriate diagnostic tests may lead to misdiagnosis and inappropriate treatment.³ Although the specific enzyme and gene defect have been identified, diagnosis and treatment of these disorders present formidable challenges because their signs and symptoms mimic other common conditions. We present a case report of a 13 years old girl who suffers from acute intermittent porphyria and the family tree showing all members who suffer from it.

Key words: *Porphyria. Acute porphyrias. Cutaneous porphyrias.*

INTRODUCTION

Acute intermittent porphyria is an autosomal dominant disease that results from defects in the enzyme porphobilinogen-deaminase and manifests itself by abdominal pain, neuropathies, and constipation, but, unlike most types of porphyria, patients with it do not have a rash. It is the most common and most severe of the inherited hepatic porphyrias.⁴ The predominant problem appears to be neurologic damage that leads to peripheral and autonomic neuropathies and psychiatric manifestations. The sequence of events in attacks is usually (1) abdominal pain, (2) psychiatric symptoms and (3) peripheral neuropathies, mainly motor neuropathies. The neurovisceral symptoms result from autonomic neuropathies (e.g. constipation, colicky abdominal pain, vomiting and hypertension), peripheral neuropathy, seizures, delirium, coma and depression.⁵ In most European countries, about 1 in 75000 people suffer from it. The incidence in local adult or paediatric population is unknown. We present a family, diagnosed with acute intermittent porphyria.

CASE REPORT

A 13 years old girl came to our O.P.D. with the complaints of abdominal pain, vomiting, restlessness and jaundice for 5 days. On examination, she was

conscious but very irritable, anemic and jaundiced. Vitals showed a blood pressure of 145/95 mmHg which was above the 95th centile for age and sex. Systemic examination was normal. Her family history was very significant as her mother, maternal grandfather, three maternal aunts and two maternal uncles have been diagnosed as acute intermittent porphyria (Figure 1). The girl was asked about the color of her urine and she confirmed that it was red. She was investigated and her labs showed a normal Hb: T.L.C: and platelets count normal. Electrolytes showed a low sodium of 122 mmol/l. Potassium: 4 mmol/l, bicarbonate: 18 mmol/l, chloride: 98 mmol/l, Calcium: 9.3mg/dl and phosphorus: 3mg/dl. Her urine was positive for ALA (Amino-Levulinic Acid) and porphobilinogen. She was managed with intravenous dextrose, hyponatremia was corrected and propranolol was given for high blood pressure. She was given an adequate calorie diet and

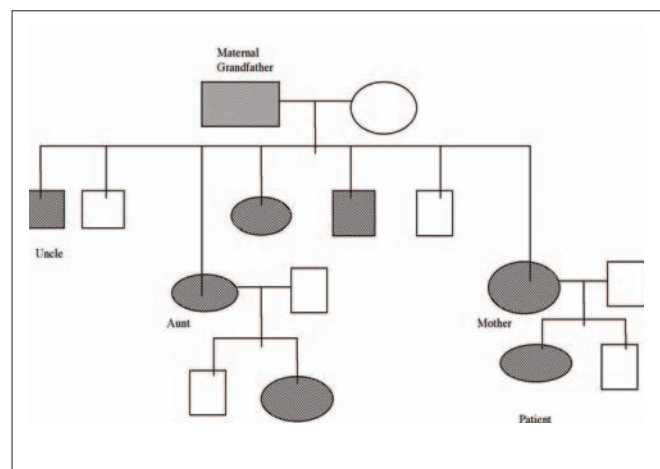


Figure 1: Family tree of acute intermittent porphyria.

Department of Paediatrics, The Aga Khan University Hospital, Karachi.

Correspondence: Dr. Abdul Gaffar Billoo, Professor of Paed. 3-A, Justice Inamullah Road, Hill Park, Karachi-74800. E-mail: gaffar.billoo@aku.edu

Received January 24, 2008; accepted April 21, 2008.

her symptoms and color of urine improved. She was discharged after 4 days of treatment with the advice for a regular follow-up and to avoid long hours of fasting. After discharge, she had two more admissions 3 months apart with similar complaints and it was noted that they coincided with the onset of her menstrual cycle. She was also given a card with the diagnosis and a list of drugs to be avoided.

DISCUSSION

Acute intermittent porphyria is characterized clinically by acute episodes of a variety of gastrointestinal and neuropathic symptoms; between episodes, the patient is healthy. Abdominal pain is the most common presenting symptom, sometimes with constipation and urinary retention; paresthesias and paralysis also occur, and death may result from respiratory paralysis. Acute attacks rarely occur before puberty and they may be precipitated by porphyrinogenic drugs such as barbiturates, sulfonamides, carbamazepine, spironolactone, diclofenac and many others, some of which are known to induce the earlier rate-controlling step in heme synthesis.⁸ About 1% of acute attacks of porphyria may be fatal. Other known precipitants are alcohol, infection, starvation, and hormonal changes; attacks are more common in women.

Our patient was noted to have premenstrual attacks of acute intermittent porphyria and during admissions had hypertension and hyponatremia which needed treatment during that period. Her irritability was because of hypertension and hyponatremia, which resolved when treated. With menstrually related attacks, attempts to regulate the cycles with hormonal preparations may exacerbate porphyria. Some patients have responded well to hormonal suppression with gonadotrophin-releasing hormone agonists, but the safety and efficacy of different regimens need further investigation.¹⁰ Study of patient's suspected of having porphyria should include several steps: (1) clinical evaluation, (2) biochemical study, which enables us to classify the patient to a specific form of porphyria, followed if possible by (3) enzymatic assay(s), and (4) genetic studies to confirm an enzyme deficiency and its level and the causal genetic mutation. Unfortunately, enzyme assays and genetic studies are not available in our setup. Urinary estimation of porphobilinogen is the first step if acute porphyria is suspected. In severe attacks, a 10% glucose infusion is commenced to provide a minimum 300-400 g of carbohydrate/day which helps in recovery.⁶ Hematin and haem arginate are the drugs of choice, administered intravenously as a short infusion at a dose of 3 mg/kg for 4 days and needs to be given early to be effective. These drugs are not curative but shorten and reduce the intensity of attack. If any drug has caused the attack then it should be discontinued. The pain which is extremely severe may require narcotic

analgesics.⁷ Infection should be treated and hyponatremia which occurs as a result of dehydration, nephrotoxicity or occasionally inappropriate antidiuretic hormone secretion requires correction as it may cause convulsions. Seizures often accompany this disease and treatment can be problematic. The knowledge of convulsions in acute intermittent porphyria is very essential because the use of enzyme-inducing antiepileptic drugs can cause worsening of the convulsion leading to death.⁹

Thus, a strong clinical suspicion, early diagnosis and adequate management of convulsions and prevention of further attacks are of paramount importance in reducing the morbidity and mortality. Prompt diagnosis and treatment greatly improves prognosis and may prevent development of severe or chronic neuropathic symptoms. Prevention is important in acute intermittent porphyria, especially in girls as females are more prone to attacks and also have more severe symptoms than males. Information should begin before puberty as attacks in girls are likely to start at that time.

Unfortunately, no curative treatment is available for any of the porphyrias.⁹ Patients should wear a medic alert bracelet and should be fully educated regarding precipitating factors. They should be evaluated by a nutritionist and follow a well balanced diet with sufficient calories to maintain weight. People with porphyria can lead a normal life and the risk of acute attack decreases after forty, but never disappears. When a patient is diagnosed with porphyria, the whole family needs to be screened.

Acute intermittent porphyria should always be considered as the differential diagnosis in a case of acute abdominal pain with neuropsychiatric manifestations, whether family history of it is present or not.

REFERENCES

1. Thadani H, Deacon A, Peters T. Diagnosis and management of porphyria. *BMJ* 2000; **320**:1647-51.
2. Anderson KE, Bloomer JR, Bonkovsky HL, Kushner JP, Pierach CA, Pimstone NR, *et al.* Recommendations for the diagnosis and treatment of the acute porphyrias. *Ann Intern Med* 2005; **142**: 439-50.
3. Lecha M, Herrero C, Ozalla D. Diagnosis and treatment of the hepatic porphyrias. *Dermatol Ther* 2003; **16**: 65-72.
4. Kuo HC, Lee MJ, Chuang WL, Huang CC. Acute intermittent porphyria with peripheral neuropathy: a follow-up study after hematin treatment. *J Neurol Sci* 2007; **260**: 231-5.
5. Meyer UA, Schuurmans MM, Lindberg RL. Acute porphyrias: pathogenesis of neurological manifestations. *Semin Liver Dis* 1998; **18**: 43-52.
6. Sies C, Florkowski C, George P, Potter H. Clinical indications for the investigation of porphyria: case examples and evolving laboratory approaches to its diagnosis in New Zealand. *N Z Med J* 2005; **118** (1222):U1658.

7. De Loughery TG. Acute Intermittent porphyria. e medicine [Internet]. 2006 Jun 30 [cited 2008 Apr 30]. Available from: <http://www.emedicine.com/med/topic1880.htm>
8. Sassa S. Modern diagnosis and management of porphyrias. *Br J Haematol* 2006; **135**: 281-92.
9. A safe and unsafe drugs in acute intermittent porphyria, variegate porphyria and coproporphyria. In: Tobe BA, (edi) Guide to porphyria. Manitoba, Canada: *Canadian Porphyria Foundation*; 2003.
10. Anderson KE, Spitz IM, Bardin CW, Kappas A. A gonadotrophin releasing hormone analogue prevents cyclical attacks of porphyria. *Arch Intern Med* 1990; **150**:1469-74

.....★.....