



THE AGA KHAN UNIVERSITY

eCommons@AKU

Department of Anaesthesia

Medical College, Pakistan

September 2008

# Role of psoas compartment and caudal epidural steroid injection in spinal stenosis patients associated with low back pain and lower limb radiculopathy

Mueen Ullah Khan  
*Aga Khan Univeristy*

S. Zaki Hussain  
*Queen's Medical Centre, UK*

Follow this and additional works at: [http://ecommons.aku.edu/pakistan\\_fhs\\_mc\\_anaesth](http://ecommons.aku.edu/pakistan_fhs_mc_anaesth)

 Part of the [Anesthesiology Commons](#), and the [Surgery Commons](#)

## Recommended Citation

Khan, M., Hussain, S. (2008). Role of psoas compartment and caudal epidural steroid injection in spinal stenosis patients associated with low back pain and lower limb radiculopathy. *Journal of the Pakistan Medical Association*, 58(9), 490-3.

**Available at:** [http://ecommons.aku.edu/pakistan\\_fhs\\_mc\\_anaesth/33](http://ecommons.aku.edu/pakistan_fhs_mc_anaesth/33)

# Role of psoas compartment and caudal epidural steroid injection in spinal stenosis patients associated with low back pain and lower limb radiculopathy

Mueen Ullah Khan<sup>1</sup>, S. Zaki Hussain<sup>2</sup>

Department of Anaesthesia and Intensive Care, Aga Khan University<sup>1</sup>,  
Pain Management Centre, Queen's Medical Centre, Nottingham, United Kingdom<sup>2</sup>

## Abstract

**Objective:** To study the efficacy, safety and patient satisfaction of psoas compartment and caudal epidural steroid injection in patients with spinal stenosis and lumbosacral radiculopathy.

**Methods:** Patients with a diagnosis of spinal stenosis and lumbosacral radiculopathy having visual analogue score (VAS) less than five were included in the study. Bilateral psoas compartment and caudal epidural injection was given to all patients. In group- A patients haemodynamics and complications were examined immediately after injection. In group-B the same patients were examined through a questionnaire after eight weeks, for pain relief, duration of pain relief, reduction in painkillers and overall improvement in activities of daily living.

**Results:** Total 106 patients were examined. In group-A change in haemodynamics before and after twenty minutes of injection was less than 15 percent and no immediate complications were reported. In group B more than 90 percent of patients reported relief of pain and VAS remained below three. Relief of pain lasted for 1-2 weeks, 2-4 weeks, 4-6 weeks and 6-8 weeks in 13 percent, 11 percent, 27 percent and 43 percent of patients respectively. More than fifty percent of patients reported up to 70 percent improvement in activities of daily living (ADL) and reduction in weekly intake of supplemental pain killers. Six percent of the (seven) patients reported no response to treatment.

**Conclusion:** Psoas compartment and caudal epidural steroid injection could be an alternate option for pain relief in patients with spinal stenosis and lumbosacral radiculopathy (JPMA 58:490;2008).

## Introduction

The most common reasons for low back pain (LBP) are radiculopathy, disc herniation and spinal stenosis<sup>1</sup>. Chronic low back pain may account for disability<sup>2</sup> and has emotional and psychological impact. Epidural corticosteroids are commonly employed treatment for patients with various low back or low extremity pain syndromes (or both). In literature, the reports on the use of this type of treatment indicate benefits but with varied results.<sup>1,3,4</sup> The complexity of the clinical problem, and the multifactorial nature of chronic pain have obscured the outcome, assessment and slowed the efforts to optimize the results.

The psoas compartments act as a conduit for nerve roots of the lumbar plexus. This natural gutter acts as a repository for local anaesthetic agents and provides an excellent approach for anterior lower extremity anaesthesia. Profound sensory or motor blockade can be achieved providing surgical anaesthesia as well as long duration postoperative pain relief.<sup>5</sup>

The Para vertebral approach to lumbar and sacral plexus through psoas compartment and caudal epidural blocks has successfully been used in a variety of patients for intraoperative and postoperative pain relief. This technique

is simple, easy to perform and less dangerous if compared to anaesthesia obtained by spinal approach.<sup>6</sup>

Very scanty literature is available regarding therapeutic effectiveness of local anaesthetic with steroids in lumbar Para vertebral injections in patients with spinal stenosis, low back pain and painful lower limb radiculopathies. We did a prospective observational study at the Queens Medical Centre (QMC), Pain Management Centre (PMC) University Hospital, Nottingham, United Kingdom with an objective to assess the efficacy, safety and patient satisfaction following bilateral psoas compartment and caudal epidural local anaesthetic and steroid injection immediately and at eight weeks follow-up.

## Methods

This study was conducted at QMC Pain Management Centre Nottingham UK. Pain Management Centre, offers five procedure rooms equipped with good noninvasive monitoring, and full resuscitation facilities. After approval from the ethical review committee, all patients who attended the QMC for one year with a diagnosis of spinal stenosis on MRI and complained of symptoms of lumbosacral radiculopathy with VAS of more than five and scheduled for bilateral psoas compartment and caudal epidural steroid injection were

included in the study. The written consent for the procedure was taken on the day of procedure.

Bilateral Psoas compartment block and caudal epidural injection was given blindly in all patients according to the anatomical landmarks described by Moore.<sup>7</sup> The patient was placed prone with a pillow under the abdomen and pelvis to help minimize lumbar lordosis and there by highlight the abdominal landmarks. The site of injection at a point 5 cm (about 3 finger breadth) lateral to the L1 vertebral spine was marked. After a sterile preparation and infiltration with lignocaine 1% a 25 gauge 9 cm spinal needle was inserted perpendicular to the skin, and advanced 4-5 cm until it contacted the transverse process of L1. Then the needle was slightly re-directed caudad, and advanced 1-2 cms deep. A 5ml syringe filled with 3ml air was attached to the needle. With light tapping on the plunger, the needle was advanced until resistance to the tapping disappeared. At this point the needle passed through the quadratus lumborum muscle into the psoas compartment. After negative aspiration test for air, blood, CSF or urine bupivacaine 0.25% (9 ml) and 20 milligram methyl prednisolone acetate (1 ml) a total of 10ml solution was injected slowly. The same procedure was performed on the opposite side psoas compartment block.

While the patient was in the same position as for psoas compartment block caudal epidural injection was employed. After full aseptic precautions sacral hiatus was palpated in the same position. A skin wheal was raised, 21-gauge needle was used for localization of caudal epidural space, when a click or a sensation was felt. After negative aspiration for CSF or blood, bupivacaine 0.25% (9ml) with 40 milligram (1ml) of methyl prednisolone and total of 10ml solution was injected. The dose of injectate was fixed for all patients. All procedures were performed by senior anaesthetist with more than twenty years of experience as pain physician.

All patients were divided into two groups.

In Group-A, patients were examined in the clinic immediately after receiving psoas compartment and caudal epidural steroid injection. On arrival in the pain clinic heart rate, systolic, diastolic and mean noninvasive blood pressures were recorded as baseline and then immediately after the procedure and two readings at ten minutes interval. Complications as syncopal attack, hypotension (Systolic blood pressure drop <100mm Hg), aggravation of pain, motor blockade and pain at the site of the injection or any untoward effects were noted on a predesigned form. All patients were kept in the waiting area for at least half an hour before and after the procedure. If the observation results were satisfactory, they were discharged from the clinic.

In Group- B the same patients were examined eight weeks after the psoas compartment and caudal epidural steroid injection in the follow up clinic. A questionnaire was filled by the patients on a predesigned form regarding any local side effects such as bruising haematoma etc and over all improvement in pain on a VAS 0- 10 (0= No pain and 10 = Worst pain). The duration of pain relief in weeks, their ability to reduce pain killers and overall improvement in activities of daily living in percentage terms (0%= No improvement, 100%= fit and normal activity) were recorded. Patients who refused or were unable to understand the questionnaire were excluded from the study.

VAS of less than three, reduction in weekly intake of supplemental pain killers and fifty percent improvement in activities of daily living after six weeks was considered as the success of the procedure.

Paired t-test was applied for comparison of haemodynamics (heart rate, systolic (SBP), diastolic (DAB) and mean arterial blood pressure( MAP)) at base line and after twenty minutes of psoas compartment and caudal epidural steroid injection.

## Results

Total number of patients studied in one year was 106. Data of one patient in group A was found incomplete. Median age of patients studied was 54 (range 24 to 88 years) and male to female ratio was 50:56.

In group-A patients heart rate, SBP, DBP and MAP at base line was 79bpm, 139 mmHg, 86 mmHg and 103 mmHg respectively and after twenty minutes of injections heart rate were 72bpm, SBP 133mmHg, DBP 80mmHg and MAP 98 mmHg. The comparison of mean values of haemodynamics at baseline and after twenty minutes of injections were statistically significant ( $p < 0.001$ ) but the clinical change was less than fifteen percent. None of the patient had any episode of syncopal attack, aggravation of pain, motor blockade or any other complications. Seventy one (68%) patients complained of pain at the site of injection, hundred (94%) patients were satisfied and confident to go home after the procedure and rest of them were not sure about that.

In group B, the patients were examined in the follow up clinic after eight weeks of injections. Pain relief was measured on VAS of 0-10 (0 = No pain and 10 = Worst pain). Six (5%) patients reported complete relief of pain (VAS = 0), ninety three (89%) patients scored VAS less than three and seven (6%) patients reported no response to the treatment. Relief of pain lasted for 1-2 weeks in thirteen patients (13%), 2-4 weeks in twelve (11%), 4-6 weeks in twenty nine (27%) and 6-8 weeks in forty five (43%) patients. Seven (6%) patients reported

no relief of pain (Figure).

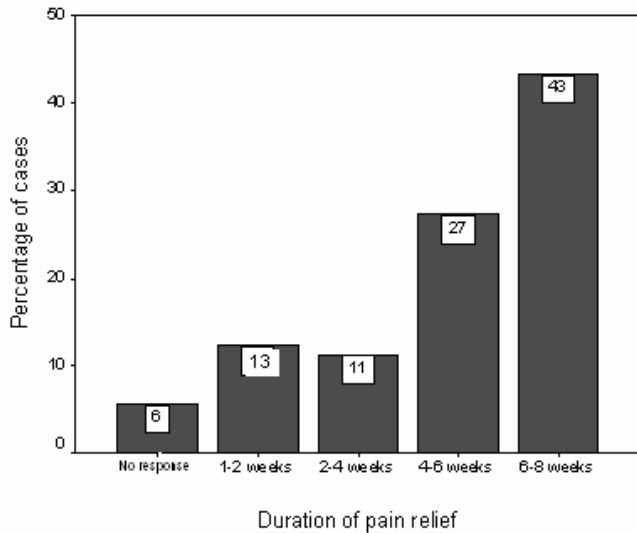


Figure: Group- B -Duration of pain relief after psoas compartment and caudal epidural steroid injection.

Over all improvement in activities of daily living in terms of duration of standing and getting out of the chair/bed was reported in terms of percentage. Seventy four (70%) patients reported fifty to seventy percent improvement, twenty six (24%) patients reported less than fifty percent and six patients reported no improvement in daily activities. Sixty (57%) patients reported that they were able to reduce the weekly intake of supplemental rescue painkillers in addition to routine medications. Thirty five patients reported bruising at the site of injection which did not require any treatment.

## Discussion

Chronic low back pain is a major cause of disability. These patients display common characteristics with reference to pain, functional problems and contact with health care services.<sup>8</sup> Lumbar stenosis results from degenerative changes usually superimposed on a congenitally narrowed spinal canal and can result in significant pain and disability.<sup>6</sup> Narrowing of the vertebral canal, the lateral recess, or the neural foramina can cause lumbar spinal stenosis.<sup>9</sup> Over the years, a number of treatments for persistent low back pain have been developed. Little is known about the efficacy of non operative therapies for lumbosacral radicular pain. The proposed non operative treatment consist of therapeutic exercise, analgesics and epidural steroid injection.<sup>10</sup> The therapeutic value of epidural injection in all lumbar spine disorders remains controversial. Favourable outcome, reported in some controlled studies<sup>11,12</sup> suggests that epidural steroid injection benefit lumbar radicular pain for

various structural disorders. Different studies,<sup>13,14</sup> on epidural steroid injection for the treatment of patients with lumbar spinal stenosis suggests short term benefit<sup>6</sup>. Caudal with unilateral or bilateral Psoas compartment blocks are not new techniques and are used mainly for intraoperative and postoperative pain relief in lower limb surgeries.<sup>6,15</sup> At present few studies showed the effectiveness of Para vertebral blocks and caudal epidural steroid injection in the management of lumbosacral radicular pain syndrome.<sup>16-18</sup>

Our results demonstrate the positive effects of unilateral or bilateral psoas compartment and caudal epidural local anaesthetic plus steroid injection. Efficacy, patient satisfaction and safety of psoas compartment and caudal epidural steroid injection were assessed in terms of overall reduction of pain relief and amount of analgesics, duration of pain relief, and overall improvement in daily activities.

In our study majority of patients (100/106) reported either a marked relief in pain or their pain remained bearable (VAS < 3), for a period of 4 to 8 weeks. Those few cases (6/106) with no response to treatment, had either severe spinal stenosis preventing local drug absorption or neurogenic claudication. Our results are comparable with Hopwood and Abram's<sup>10</sup> study on 212 patients, who had significant improvement after lumbar epidural steroid injection (ESI). A meta analysis by Watts and Silagy<sup>20</sup> on ESI showed that the chance of short term success was more than 75% which lasted up to 60 days. Spaccarelli KC<sup>18</sup> extensively reviewed case reports, of retrospective and prospective studies on use of lumbar and caudal ESI. They concluded that this treatment was more effective in patients with certain lower extremity radicular pain syndromes. Fairly low success of epidural steroid injection is reported in patients with severe spinal stenosis or neural claudication.<sup>19</sup> However anatomical factors, symptomatic presentation, medical comorbidities and psychological factors may strongly influence the patient outcome and also determine the success of non surgical treatment<sup>6</sup>. Myofascial pain syndrome, facet and sacroiliac joint arthrosis often produce pain that radiates into the lower extremity and they are unlikely to respond to this form of therapy.

In our patients we used local anaesthetic for acute pain and short term pain relief and methyl-prednisolone acetate depot for long term relief. The pathologic explanation of corticosteroid therapy stems primarily from the evidence that biochemical and neurochemical inflammatory mediators may play a role in the occurrence of lumbar radiculopathy.<sup>22</sup> Corticosteroids are known to inhibit prostaglandin synthesis, and to repair cell mediated and immunologic responses.<sup>23-24</sup> The other postulated actions of corticosteroids includes membrane stabilizing, suppression of neuropathies, blocking phospholipase A2

activity, and blocking of nociceptive C-fibers conduction.<sup>6</sup> Styczynski T et al<sup>14</sup> report favourable outcomes in their study and suggest that Para vertebral blockade (steroid plus local anaesthetic) injection benefit in patients with shorter lasting lumbar radicular pains. In addition to this corticosteroids have lipolytic and osteoporotic effect that may reduce neural compression effect from adjacent fibrofatty and bony structures.

The frequency of complications after psoas compartment block is not well documented. In literature central complications as extended spinal anaesthesia, acute cardiac arrest or neurological toxic accidents and renal sub capsular haematoma are reported.<sup>25,26</sup>

Serious complications are caused by spread of injectate and/or the penetration of the needle or catheter to the epidural or intrathecal spaces in continuous psoas compartment blocks. We used 25g spinal needle and injected 10 mililitres of volume as bolus in each block. This small quantity cannot spread into the intrathecal or epidural spaces from wide spaced psoas compartment to cause any serious complications. Needle insertion at the level of L 1 was kept with in five centimetres from midline to avoid the risk of penetrating through renal parenchymal tissue, as the hilum of the kidney lies at 7-8 cms from midline.<sup>27</sup> In this study none of our patients had any serious neurological or other complications on follow up requiring therapeutic intervention. However two third of the patients complained of pain at the site of injection for forty eight hours or longer which did not require any intervention except additional intake of non steroidal anti-inflammatory drugs.

The critique on our study could be that the procedure of psoas compartment block and caudal epidural injections were done blindly. Better results would be possible with needle tip localization technique.

A Level I evidence with a double blind cross over study in the management of chronic pain is difficult to achieve. Our observational study results demonstrate a positive effect of psoas compartment and caudal epidural steroid injection in low back pain with lower limb radiculopathies. This procedure is cost effective as it is carried out in the outpatient pain clinic. We suggest that psoas compartment with caudal epidural steroid injection should be considered as an alternate option for the management of low back pain and lower limb radiculopathies due to lumbar sacral stenosis or failed back surgery syndrome.

### Acknowledgement

We acknowledge the assistance of the nursing staff of pain management centre Queen's Medical Centre Nottingham, United Kingdom in collection of data and

Professor Rehana.S. Kamal, Aga Khan University Hospital Karachi, in the preparation of this manuscript.

### References

- 1- Rosen CD, Kahanovitz N, Bernstein R, Viola K. A retrospective analysis of the efficacy of epidural steroid injections. *Clin Orthop Relat Res* 1988 ;228: 270-2
- 2- Kovacs FM, Abraira V, Zamora J, Teresa Gil del Real M, Llobera J, Fernández et al. Correlation between pain, disability, and quality of life in patients with common low back pain. *Spine* 2004; 29: 206-10.
- 3- Brooks DM. Psoas compartment block. *CRNA*. 2000; 11: 62-5.
- 4- Moore DC. *Regional Block*. Fourth Edition. Springfield IL, Charles C. Thomas Publishers; 1967:200-10.
- 5- Cedraschi C, Robert J, Goerg D, Perrin E, Fischer W, Vischer TL. Is chronic non-specific low back pain chronic? Definitions of a problem and problems of a definition. *Br J Gen Pract* 1999; 49: 358-62.
- 6- Storm PB, Chou D, Tamargo RJ. Lumbar spinal stenosis, cauda equina syndrome, and multiple lumbosacral radiculopathies. *Phys Med Rehabil Clin N Am*. 2002; 13: 713-33
- 7- Simotas AC. Nonoperative treatment for lumbar spinal stenosis. *Clin Orthop Relat Res*. 2001;384:153-61.
- 8- Dilke TF, Burry HC, Grahame R. Extradural corticosteroid injection in management of lumbar nerve root compression. *B M J* 1973; 16: 635-7
- 9- Snoek W, Weber H, Jorgensen B. Double blind evaluation of extradural methyl prednisolone for herniated lumbar discs. *Acta Orthop Scand*. 1977; 48: 635-41.
- 10- Ciocon JO, Galindo-Ciocon D, Amaranath L, Galindo D. Caudal epidural blocks for elderly patients with lumbar canal stenosis. *J Am Geriatr Soc* 1994; 42: 593-6.
- 11- Hoogmartens M, Morelle P. Epidural injection in the treatment of spinal stenosis. *Acta Orthop Belg*. 1987; 53: 409-11.
- 12- Baracco E, Verardo T, Gentili M. Lumbosacral plexus block by the paravertebral route. *Cah Anesthesiol* 1993; 41: 649-51.
- 13- Morin AM, Kratz CD, Eberhart LH, Dinges G, Heider E, Schwarz N, et al. Postoperative analgesia and functional recovery after total-knee replacement: comparison of a continuous posterior lumbar plexus (psoas compartment) block, a continuous femoral nerve block, and the combination of a continuous femoral and sciatic nerve block. *Reg Anesth Pain Med* 2005;30: 434-45.
- 14- Styczyński T, Parnarauskiene R, Zarski S, Kaubrys G, Klezys V, Krzemińska-Dabrowska I, et al. The assessment of therapeutic effectiveness of paravertebral blockades in patients with painful radicular syndromes in discopathy and in lumbar spine spondylosis. *Neurol Neurochir Pol*. 1997; 31: 939-49.
- 15- Apáthy A, Penczner G, Licker E, Eiben A, Bálint G, Genti G, et al. Caudal epidural injection in the management of lumbosacral nerve pain syndromes *Orv Hetil*. 1999; 140: 1055-8.
- 16- Spaccarelli KC. Lumbar and caudal epidural corticosteroid injections. *Mayo Clin Proc* 1996; 71: 169-78
- 17- Hopwood MB, Abram SE. Factors associated with failure of lumbar epidural steroids. *Reg Anesth* 1993; 18: 238-43.
- 18- Watts RW, Silagy CA. A meta-analysis on the efficacy of epidural corticosteroids in the treatment of sciatica. *Anaesth Intensive Care* 1995; 23: 564-9.
- 19- Fukusaki M, Kobayashi I, Hara T, Sumikawa K. Symptoms of spinal stenosis do not improve after epidural steroid injection. *Clin J Pain* 1998; 14: 148-51.
- 20- Weinstein JN. *Anatomy and Neurophysiologic Mechanism of Spinal Pain*. In Frymoyer JW (ed). *The Adult Spine*. New York, Raven Press. 1991; pp 29-46.
- 21- Claman HN. Corticosteroids and lymphoid cells. *N Engl J Med* 1972; 24:388-97
- 22- Rinehart JJ, Sagone AL, Balcerzak SP, Ackerman GA, LoBuglio AF. Effects of corticosteroid therapy on human monocyte function. *N Engl J Med* 1975; 30:236-41
- 23- Auroy Y, Benhamou D, Barges L, Ecoffey C, Falissard B, Mercier FJ, et al. Major complications of regional anaesthesia in France: The SOS Regional Anesthesia Hotline Service. *Anesthesiology*. 2002; 97: 1274-80
- 24- Aida S, Takahashi H, Shimoji K. Renal subcapsular hematoma after lumbar plexus block. *Anesthesiology* 1996; 84:452-5.
- 25- P Prithvi Raj, Richard L Rauch and Gabor B. Racz. Autonomic nerve blocks. *Pain medicine* 1996; 20: 227-55.