



THE AGA KHAN UNIVERSITY

eCommons@AKU

---

Section of Neurosurgery

Department of Surgery

---

July 2008

# Role of neurosurgery in the management of stroke

Gohar Javed

*Aga Khan University*

Muhammad Zubair Tahir

*Aga Khan University*

S. Ather Enam

*Aga Khan University, ather.enam@aku.edu*

Follow this and additional works at: [http://ecommons.aku.edu/pakistan\\_fhs\\_mc\\_surg\\_neurosurg](http://ecommons.aku.edu/pakistan_fhs_mc_surg_neurosurg)



Part of the [Surgery Commons](#)

---

## Recommended Citation

Javed, G., Tahir, M., Enam, S. (2008). Role of neurosurgery in the management of stroke. *Journal of the Pakistan Medical Association*, 58(7), 378-84.

**Available at:** [http://ecommons.aku.edu/pakistan\\_fhs\\_mc\\_surg\\_neurosurg/10](http://ecommons.aku.edu/pakistan_fhs_mc_surg_neurosurg/10)

### **Role of neurosurgery in the management of stroke**

Gohar Javed, Muhammad Zubair Tahir, Syed Ather Enam

Department of Neurosurgery, Aga Khan University Hospital, Karachi.

#### **Abstract**

Stroke is the second leading cause of death worldwide. The aim of treatment in stroke patients is to prevent further neurologic deterioration and prevent recurrence. Despite all advances in medical treatment, morbidity and mortality in stroke patients is still very high. The other alternative is surgical treatment, which still lacks class 1 evidence. However there is recent reconsideration of this form of treatment and ongoing trials are showing some promising results. In this review the recent advances in surgical treatment of stroke will be discussed along with recommendations from the latest randomized trials.

#### **Introduction**

Stroke is the second leading cause of death worldwide.<sup>1</sup> The World Health Organization defines stroke clinically as "rapidly developing clinical signs of focal disturbance of cerebral function, lasting for more than twenty four hours or leading to death."<sup>1</sup> We can divide stroke into two broad categories namely, ischaemic stroke and haemorrhagic stroke. Ischaemic stroke or cerebral infarction is the most common, accounting for approximately 70-80% of all strokes.<sup>2</sup> Spontaneous intracranial haemorrhages account for about 20% of all strokes, but they are often devastating, accounting for a disproportionately large proportion of morbidity and mortality among stroke patients. Haemorrhagic stroke comprises of two main types; intraparenchymal haemorrhage (ICH), where there is bleeding within the brain itself and subarachnoid haemorrhage (SAH), which is characterized by vessel rupture in the cerebrospinal fluid filled subarachnoid space surrounding the brain.<sup>3</sup>

The aim of treatment in stroke patients is to prevent further neurological deterioration and prevent recurrence. Strokes can have minor consequences especially lacunar and small cortical strokes or they can be lethal if they involve major arterial distribution such as whole middle cerebral artery (MCA) territory infarction (Figure 1). Despite all advances in medical treatment, mortality in such large infarcts is estimated to be between 50% and 78%.<sup>4</sup> The other alternative is surgical treatment, which still lacks class 1 evidence. However there is recent reconsideration of this form of treatment and ongoing trials are showing some promising results. In this review the recent advances in

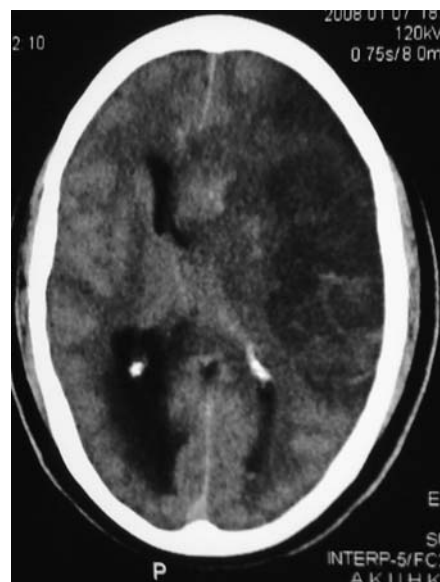


Figure 1. CT Brain showing large right MCA territory infarct with significant midline shift and mass effect.

surgical treatment of stroke along with recommendations from latest randomized trials will be discussed.

#### **Surgical treatment of ischaemic stroke:**

The poor outcome associated with ischaemic stroke is attributed to malignant oedema that causes early rise in intracranial pressure (ICP) and subsequent brain herniation and death.<sup>5</sup> Current available medical treatment of ischaemic stroke includes thrombolysis and anti coagulation. To deal with the lethal complication of malignant oedema and raised ICP, medical treatment offers mannitol, hypertonic saline, barbiturate coma, hypothermia and hyperventilation. However no medical therapy has proven effective in preventing brain herniation and improving patient outcome.<sup>6</sup>

**Decompressive Craniectomy:** As an alternative therapy, surgical decompression techniques have been proposed to relieve the high ICP. This involves removal of large bone flap, Ipsilateral to the side of infarction (hemicraniectomy) followed by dural reconstruction with the help of the flap taken from temporal fascia or any other available graft (duroplasty).<sup>7</sup> No attempt is made to remove the necrotic infarcted brain parenchyma. The rationale of this therapy is to create compensatory space to accommodate the swollen brain, thereby normalizing

intracranial pressure, reverting brain shifts and preventing secondary neuronal insult.

Decompressive surgery was first reported as a potential treatment for large hemispheric infarction in case reports as early as 1956.<sup>7</sup> The largest case series suggested that early decompression reduces mortality and may provide improved outcomes by avoiding the consequences of brainstem compression from transtentorial herniation. Patients who underwent early hemicraniectomy had a mortality rate of 16% compared to 34% for delayed surgery.<sup>8</sup> But this form of treatment remains controversial in the absence of randomized controlled trials.

Recently three multicentre randomized controlled trials have been conducted with favourable outcomes in patients who underwent decompressive craniectomies for the treatment of large MCA ischaemic strokes. These are DESTINY (Decompressive Surgery for the Treatment of Malignant Infarction of the Middle Cerebral Artery) from Germany, DECIMAL (Decompressive Craniectomy In Middle Cerebral Artery Infarcts) from France and HAMLET (Hemicraniectomy After Middle Cerebral Artery Infarction With Life Threatening Odema Trial) from Netherland.<sup>9</sup>

DESTINY is a prospective, multicentre, randomized, controlled, clinical trial based on a sequential design that used mortality after 30 days as the first end point.<sup>10</sup> When this end point was reached, patient enrollment was interrupted as per protocol. A statistically significant reduction in mortality was reached after 32 patients had been included. Fifteen of seventeen (88%) patients randomized to hemicraniectomy versus 7 of 15 (47%) patients randomized to conservative therapy survived after 30 days ( $P = 0.02$ ). After 6 and 12 months, 47% of patients in the surgical arm versus 27% of patients in the conservative treatment arm had a modified Rankin Scale score of 0 to 3 ( $P = 0.23$ ). DESTINY showed that hemicraniectomy reduces mortality in large hemispheric stroke. DESTINY has several shortcomings. First, 81% of patients originated from 2 centres only. As a matter of fact, this makes DESTINY an oligocentre rather than a multicentre trial. In addition DESTINY does not provide data on older patients with malignant MCA infarction. Based on the results of several reports suggesting that patients more than 60 years may not benefit from decompressive surgery, DESTINY only included patients 18 to 60 years of age.

DECIMAL is a Sequential-Design trial conducted in France involving patients between 18 and 55 years of age with malignant MCA infarction to compare functional outcomes with or without decompressive craniectomy.<sup>6</sup> After randomization of 38 patients, the data safety

monitoring committee recommended stopping the trial because of slow recruitment and organizing a pooled analysis of individual data from this trial and the two other ongoing European trials of decompressive craniectomy in malignant MCA infarction. Among the 38 patients randomized, the proportion of patients with a MRS score less than 3 at the 6-month and 1-year follow-up, was 25% and 50%, in the surgery group compared with 5.6% and 22.2%, in the no-surgery group respectively ( $P = 0.18$  and  $P = 0.10$ , respectively). There was a 52.8% absolute reduction of death after craniectomy compared with medical therapy only ( $P < 0.0001$ ). In this trial, early decompressive craniectomy increased by more than half the number of patients with minimal to moderate disability and significantly reduced (by more than half) the mortality rate compared with that after medical therapy.

The other surgical options for ischaemic stroke are embolectomy, carotid endarterectomy, stenting and emergency revascularization. The National Institute of Neurological Disorders and Stroke (NINDS) reported that thrombolytic therapy by intravenous administration of a recombinant tissue plasminogen activator (t-PA) was effective in improving the prognosis of patients with acute cerebral infarction within 3 hours after the onset.<sup>11</sup> However, cases of cerebral infarction due to main-trunk occlusion had a low revascularization rate and a poor prognosis.<sup>12</sup>

**Carotid endarterectomy:** Carotid artery surgery has been shown to significantly decrease the risk of a subsequent stroke compared to the best medical therapy alone.<sup>13</sup> Carotid artery surgery has also been used when the patient has acute carotid occlusion and minor stroke. Possible contraindications to carotid endarterectomy include serious medical risks of anaesthesia and recent large parenchymal infarction.

Carotid artery surgery helps prevent subsequent brain ischaemia secondary to haemodynamic insufficiency, arterial embolism or propagating thrombosis from the diseased artery. The benefits of carotid surgery appear to be durable. Recurrent stenosis occurs at the rate of 5 - 10% per year after operation but is not always symptomatic.<sup>14</sup> Operative mortality is less than 2% and the risk of stroke is less than 4%.<sup>15</sup>

Prospective analyses as the North American Symptomatic Carotid Endarterectomy Trial (NASCET), the Asymptomatic Carotid Atherosclerosis Study (ACAS), and the European Carotid Surgery Trial (ECST) demonstrated superior reduction in the incidence of stroke among symptomatic and a select group of asymptomatic patients undergoing carotid endarterectomy (CEA). These studies established CEA as the therapeutic gold standard for symptomatic carotid atherosclerosis.

However technical innovations in interventional radiology have renewed the debate about the optimal therapy. Although retrospective analyses of angioplasty and stenting suggest that their clinical efficacy is comparable to that of endarterectomy, prospective evaluation is pending. The Carotid Revascularization Endarterectomy versus Stent Trial (CREST) and the Carotid and Vertebral Artery Transluminal Angioplasty Study (CAVATAS) will attempt to address the efficacy of percutaneous angioplasty and stenting compared with CEA.

Revascularization surgery: Bypass surgery provides collateral blood flow to the territory of occluded or severely stenosed cerebral arteries. A large international cooperative study, however, failed to reveal any benefit of external carotid - internal carotid artery (EC-IC) bypass surgery, usually done by end to side anastomosis of superficial temporal artery branch with middle cerebral artery distal to pathological site, in the setting of symptomatic arterial occlusions and inaccessible stenosis.<sup>16</sup> However two particular groups were not addressed: those for whom the best available medical therapy had failed and those with clearly documented haemodynamic compromise.<sup>17</sup>

The current indications of revascularization surgery include patients with impaired collaterals causing regional cerebral blood flow compromise and failed maximal medical therapy. Other clinical situations in which an EC-IC bypass procedure may be considered includes, giant cerebral aneurysms not amenable to direct surgical clipping and reconstruction (where the parent vessel must be sacrificed) and other progressive vasculopathies.

Sakai et al reported their surgical results in patients with acute cerebral main-trunk occlusion in the anterior circulation.<sup>18</sup> Twenty six patients were surgically treated within 24 hours after the onset. The occlusion occurred in the internal carotid artery in 10 patients, in the middle cerebral artery in 15 patients, and in the anterior cerebral artery in 1 patient. Nine patients underwent anastomosis, 14 had an embolectomy, and 3 had a carotid endarterectomy. In all the patients, revascularization was achieved, and neurological improvement was obtained. Their study concluded that early surgical revascularization can be an effective and safe treatment modality in appropriately selected patients with acute cerebral main-trunk occlusion in the anterior circulation.

Revascularization in Moya Moya Disease: Moyamoya disease (MMD) is a rare cerebrovascular condition characterized by progressive, idiopathic occlusion of the bilateral supraclinoid internal carotid arteries (ICA), proximal middle cerebral artery, and anterior cerebral artery (ACA). Since its first description by Takeuchi and Shimizu in 1957 and subsequent angiographic characterization and

naming by Suzuki and Takaku in 1969, several thousand cases have been documented worldwide. Moyamoya disease is diagnosed and staged by using catheter angiography.

With a morbidity rate of >70% in untreated patients, surgical intervention has become the standard therapy in patients with MMD. Surgical interventions have been divided into direct and indirect bypass techniques. The direct bypass techniques proposed include superficial temporal artery - middle cerebral artery (STA-MCA), occipital artery-MCA, and middle meningeal artery- middle cerebral artery (MMA-MCA) anastomoses. The indirect techniques consist of multiple cranial bur holes, omental transposition, encephaloduroarteriosynangiosis (EDAS) and encephaloduroarteriomyosynangiosis (EDAMS), both consist of laying dural flap with intact blood supply directly on to cerebral cortex.

### **Surgical treatment of haemorrhagic stroke**

Intra parenchymal brain haemorrhage is more common than sub arachnoid haemorrhage as a cause of stroke. Sub-arachnoid haemorrhage itself may not require any surgical treatment but some of its causes or complications require surgery. Aneurysms causing sub arachnoid haemorrhage require obliteration by clipping or coiling. Vascular malformations may require surgical excision. Hydrocephalus or malignant oedema developing after sub-arachnoid hemorrhage may also require surgery.

The first question that a surgeon has to address while treating a case of ICH is whether or not surgery is required in a particular case? The answer to this question is better defined in the case of infra-tentorial haematomas than in supra-tentorial clots.

Surgery is required in cerebellar haematomas if there is tight posterior fossa, moderate to severe compression of fourth ventricle, hydrocephalus or a Glasgow coma score of less than 13. Size of the haematoma is a more controversial issue. Vermian haematomas more often require evacuation as compared to hemispheric hematomas of comparable size. Surgery is required for a hemispheric hematoma which is 40 x 30 mm or more and a vermian hematoma which is 35 x 25 mm or more in their largest dimensions. However, a hemispheric haematoma can be observed and managed conservatively, even if it is more than 30 mm in its maximum diameter but is not causing any significant compression of the fourth ventricle.<sup>19,20</sup> Similarly prognosis for brain stem haematomas is poor except in those cases of pontine haemorrhage that are not comatose to begin with, have normal pupils and the size of the haematoma is less than 20 mm.<sup>21</sup> The results of surgery were found to be favorable in 13 out of 20 patients with CT guided

stereotactic aspiration of pontine tegmental hypertensive haemorrhages when compared to the conservative treatment.<sup>22</sup>

The indications of surgery in supra-tentorial ICH are less obvious. This may be because of a paucity of large, randomized, multi-centre studies. Another reason is probably a trend towards minimally invasive surgery with resultant modification of the indications. The only large, randomized, multicentre study addressing this issue is International Surgical Trial for Intra Cerebral Haemorrhage (STICH).<sup>23</sup> In this trial 1033 patients from 83 centres in 27 countries mainly from Europe, Asia and Africa were randomized into two treatment groups. In one group, patients were managed conservatively, while in the other group patients underwent surgery within 24 hours of randomization in addition to conservative treatment. Variables were age, haematoma volume, Glasgow coma score, lobar versus basal ganglia / thalamic haematoma or both, thrombolytic or anticoagulant treatment, severity of neurological deficit and type of intended operation. Prognostic score was calculated as:

$$(10 \times \text{admission Glasgow coma score}) - \text{Age (years)} - (0.64 \times \text{volume [ml]})$$

Primary outcome was death or disability using the extended Glasgow outcome scale 6 month after the ictus. Secondary outcome included mortality, the Barthel index and the modified Rankin scale. Significant benefit of surgery was not found in terms of mortality, modified Rankin scale or Barthel index. Any favorable outcome seen with minimally invasive methods was offset by the craniotomy procedures, which were performed in the majority of the patients. This majority of craniotomies are probably the reason why the only advantage of early surgery observed in this study is for the hematomas located within one centimeter of the surface (easier removal of superficial hematomas through craniotomies). Results of other randomized trials before STICH also failed to show any benefit of surgery in ICH.<sup>23</sup> Does that prove that there are no well defined indications for surgery in supra tentorial ICH? The answer to this question lies in the inclusion criteria of STICH trial. One of the inclusion criteria for this trial is "if the responsible neurosurgeon is uncertain about the benefits of either treatment". So the uncertain results attest to the "uncertainty" of the surgeons. This means that there should be a number of cases in which a surgeon is more certain about the results of surgery. This leads to another question. When should a surgeon be more certain about the decision to operate in a case of supra tentorial ICH? Although there is no support from the literature, no one can wait in a middle aged otherwise fit patient who shows rapid deterioration of level of consciousness due to a

relatively superficial medium size (15-30 cc) clot located in a non eloquent part of the brain. So the best indication of surgery in supra-tentorial hematomas is certainty of the surgeon about the results of surgery according to his/her knowledge, experience and circumstances.

The methods for hematoma evacuation can be divided into two categories: craniotomy / craniectomy and minimally invasive procedures.

**Craniotomy:** In STICH trial, craniotomy and evacuation of ICH has been found to be associated with favorable outcome for the hematomas within 1 cm of the brain surface (Figure 3). The other theoretical consideration is the consistency of the hematoma. A more organized

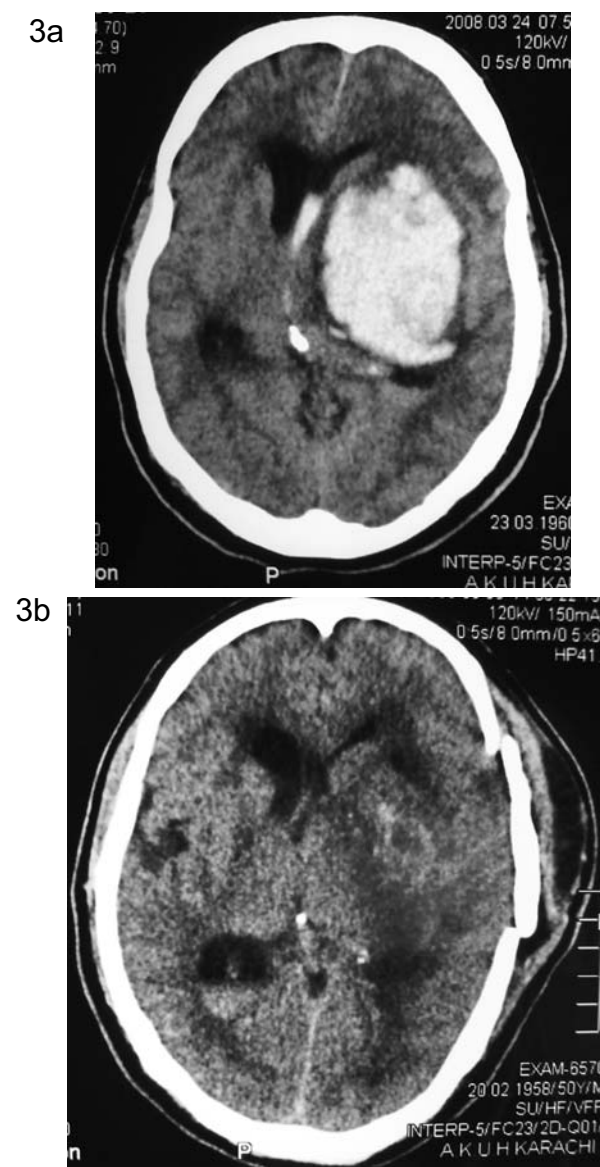


Figure 3. CT Brain showing large left basal ganglia bleed with mass effect and intraventricular spillage of blood. Surgery offered as a life saving procedure after patient developed signs of herniation. a - Preop scan, b - post op scan.

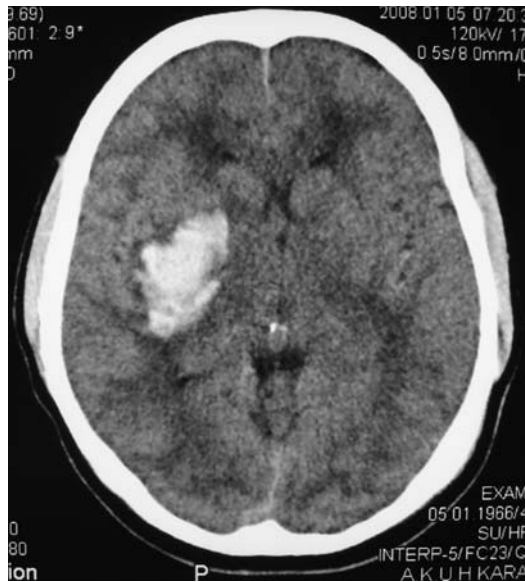

Figure 2. CT Brain showing small deep seated right basal ganglia bleed. Managed non operatively by Neuro observation.

hematoma should be easily evacuated through craniotomy but is resistant to suction without fibrinolysis if operated by minimally invasive procedures. Visibility provided by the combination of craniotomy and operating microscope may be another advantage over blind procedures which form a significant part of minimally invasive surgery. However, a deep seated hematoma in clinically good patients should be observed (Figure 2).

One study from China has prospectively compared endoscopic surgery, stereotactic aspiration and craniotomy in non comatose patients.<sup>24</sup> The three randomized treatment groups (with 30 patients in each group) were compared with respect to waiting time of surgery, length of operation time, blood loss, hematoma evacuation rate and mortality. Neurological outcome was compared with respect to functional independence measure (FIM) score, Barthel index score and muscle power (MP) of affected limbs 6 months after surgery. Stereotactic aspiration had the longest waiting time before evacuation (172.56 +/- 93.18 minutes;  $P < .001$ ). This makes it less suitable for urgent situations. Craniotomy had the longest operating time (229.96 +/- 50.57 minutes;  $P < .001$ ), with most significant blood loss (236.13 +/- 137.45 ml;  $P < 0.001$ ), highest mortality (13.3%) and highest complication rate (16.6%). The most major complications were re bleeding and infection. The FIM score, Barthel index and improvement in muscle power were significantly better in endoscopy group as compared to craniotomy group. Therefore, depending upon the availability and urgency of the situation endoscopic evacuation of the hematoma is preferable over craniotomy.

**Decompressive Craniectomy:** Not much is available on this topic in the literature. A retrospective study

from India has reviewed 12 patients who were treated with decompressive hemicraniectomy with evacuation of hypertensive ICH.<sup>25</sup> Interestingly 11 out of 12 patients were discharged alive. Three out of seven with pupillary abnormalities, 7 of 11 with intra ventricular extension of haematoma and 4 of 8 with haematoma volume greater than 60 cc made good functional recovery. All these are considered to be bad prognostic signs. Therefore decompressive hemicraniectomy with clot evacuation can be life saving with good functional outcome in patients with a large size ICH is extending into the ventricles and is associated with papillary abnormalities.

**Minimally Invasive Surgery:** This can be described in two broad categories namely blind procedures and endoscopy.

**Blind Procedures:** Blind procedures are essentially burr hole aspirations, with or without the help of stereotaxy and fibrinolysis. Stereotaxy adds precision to the procedure while fibrinolysis makes a clot of firm consistency more amenable to suction. Fibrinolysis may be chemical e.g. with urokinase or t-PA or mechanical e.g. with Archimedes screw, ultrasonic aspirator or oscillating cutters. Outcome after fibrinolytic stereotactic evacuation of clot may be comparable to other methods of treatment. It is particularly advantageous for deep seated lesions.<sup>26</sup> In a study evaluating stereotactic treatment of intra cerebral haematoma by means of a plasminogen activator (SICHPA) randomized 70 patients in two groups. In surgical group a stereotactically placed catheter was used to instill urokinase to liquefy and drain the ICH in 6 hourly intervals over 48 hours. In other group the patients were treated conservatively. There was no difference in mortality as well as functional outcome. The only difference was better reduction of haematoma volume over 7 days.<sup>27</sup> Studies have also compared the results of frame based and frameless stereotaxy for the evacuation of supra tentorial ICH. No difference has been found between the two techniques with respect to haematoma volume reduction or outcome.<sup>28,29</sup>

**Neuroendoscopy:** Neuroendoscopy has been found to be better than the stereotaxy and craniotomy for the evacuation of basal ganglia ICH in non comatose patients.<sup>24</sup> Neuroendoscopic evacuation of intra ventricular haemorrhage, when compared to external ventricular drainage alone, was found to be associated with better functional outcome; however, there was no difference in mortality.<sup>30</sup> The surgical technique becomes less invasive with the use of neuroendoscope. A smaller bony opening is required to accommodate a cortical incision, which is usually less than a centimeter in width.<sup>31</sup> Use of a metallic tube allows both endoscope as well as other instruments to be used through the tube at the same time. The tube can be

manoeuvred in different directions. Instead two separate burr holes can be used for the same purpose. Liquid part of the haematoma can be aspirated. More solid part requires dissection and piecemeal removal. Dissection can be done with the help of a metallic instrument separate from the endoscope or it can also be performed with the help of a transparent viewing dissector coupled with endoscope. A water jet can also perform dissection of the haematoma. Flexible endoscope has been introduced through aqueduct for the evacuation of pontine haemorrhage.

**CSF Diversion:** External ventricular drain (EVD) may be required in those cases which develop acute hydrocephalus after spontaneous ICH. This is especially true in those cases in which ICH extends into or compresses the ventricular system. EVD may be life saving in this situation.<sup>31</sup>

Recommendations in recent American Heart Association/American Stroke Association guidelines suggest that operative removal within 12 hours by less invasive methods has some benefit. Ultra early craniotomy (within 12 hours) does not improve functional outcome or mortality rate and on the other hand is associated with increased risk of recurrent bleeding. Delayed craniotomy similarly does not offer any benefit and in fact may worsen the outcome.<sup>32</sup>

Surgery may be required to treat less common causes of haemorrhagic stroke such as spontaneous sub dural haematoma or extra dural haematoma. Craniotomy is required for acute and more solid lesions, while burr hole evacuation is usually sufficient for more liquid and chronic lesions. In addition, surgery may also play a diagnostic role e.g. whenever a biopsy is required in cases of ICH due to vasculitis.

## Conclusion

Majority of the stroke patients do not need neurosurgical involvement but in certain cases where the patient is deteriorating fast with increased ICP, herniation or impending herniation, neurosurgery should be immediately undertaken. Even diseases as devastating as cerebral venous thrombosis can have a remarkable benefit from surgical intervention in certain cases.<sup>33</sup> Although a lot of intervention that was done by neurosurgery has been taken over by interventional radiology, their respective roles have yet to be defined with high quality studies.

Neurosurgery plays an important second-tier role in the management of stroke. It behoves therefore in tertiary centres as well as other hospitals for the neurosurgery and neurology to work together. Appropriate referral can make a remarkable difference for the unfortunate victims of stroke. In many centres the haemorrhagic stroke patients

are admitted by the neurosurgical service and ischaemic stroke patients are managed by Neurologists. Whether this should be practiced in all the centres or an alternate arrangement may be agreed upon, depends on the strength of the neurology and neurosurgical service and their support staff. Physical proximity of the neurology and neurosurgery inpatient beds, clinics and combined academic activity plays a definitive role in improving the quality of stroke patient care.

## References

1. Murray CJ, Lopez AD. Mortality by cause for eight regions of the world: Global Burden of Disease Study. *Lancet*. 1997; 349:1269-76.
2. Sacco RL. Risk factors, outcomes, and stroke subtypes for ischemic stroke. *Neurology*. 1997; 49(Suppl 4):S39-44.
3. Goldstein LB, Simel DL. Is this patient having a stroke? *JAMA*. 2005; 293:2391-402.
4. Hacke W, Schwab S, Horn M, Spranger M, De Georgia M, von Kummer R. "Malignant" middle cerebral artery territory infarction: clinical course and prognostic signs. *Arch Neurol*. 1996; 53:309-15.
5. Ropper AH, Shafran B. Brain edema after stroke. Clinical syndrome and intracranial pressure. *Arch Neurol*. 1984; 41:26-9.
6. Vahedi K, Vicaut E, Mateo J, Kurtz A, Orabi M, Guichard JP, Boutron C, Couvreur G, Rouanet F, Touzé E, Guillon B, Carpentier A, Yelnik A, George B, Payen D, Boussier MG; DECIMAL Investigators. Sequential-design, multicenter, randomized, controlled trial of early decompressive craniectomy in malignant middle cerebral artery infarction (DECIMAL Trial). *Stroke*. 2007; 38 :2506-17.
7. Gupta R, Connolly ES, Mayer S, Elkind MS. Hemispherectomy for massive middle cerebral artery territory infarction: a systematic review. *Stroke*. 2004; 35 :539-43.
8. Schwab S, Steiner T, Aschoff A, Schwarz S, Steiner HH, Jansen O, Hacke W. Early hemispherectomy in patients with complete middle cerebral artery infarction. *Stroke*. 1998; 29 :1888-93.
9. Major ongoing stroke trials. *Stroke*. 2006 37:e18-e26.
10. Jüttler E, Schwab S, Schmiedek P, Unterberg A, Hennerici M, Woitzik J, Witte S, Jenetzky E, Hacke W; DESTINY Study Group. Decompressive Surgery for the Treatment of Malignant Infarction of the Middle Cerebral Artery (DESTINY): a randomized, controlled trial. *Stroke*. 2007; 38 :2518-25.
11. Marler JR. NINDS clinical trials in stroke: lessons learned and future directions. *Stroke*. 2007 ; 38 :3302-7.
12. Kim YS, Garami Z, Mikulik R, Molina CA, Alexandrov AV; CLOTBUST Collaborators. Early recanalization rates and clinical outcomes in patients with tandem internal carotid artery/middle cerebral artery occlusion and isolated middle cerebral artery occlusion. *Stroke*. 2005; 36 :869-71.
13. Clinical alert: benefit of carotid endarterectomy for patients with high-grade stenosis of the internal carotid artery. National Institute of Neurological Disorders and Stroke Stroke and Trauma Division. North American Symptomatic Carotid Endarterectomy Trial (NASCET) investigators. *Stroke*. 1991; 22 :816-7.
14. Clagett GP, Rich NM, McDonald PT, Salander JM, Youkey JR, Olson DW, Hutton JE Jr. Etiologic factors for recurrent carotid artery stenosis. *Surgery*. 1983; 93:313-8.
15. Awad IA, Little JR. Patch angioplasty in carotid endarterectomy. Advantages, concerns, and controversies. *Stroke*. 1989; 20 :417-22.
16. Failure of extracranial-intracranial arterial bypass to reduce the risk of ischemic stroke. Results of an international randomized trial. The EC/IC Bypass Study Group. *N Engl J Med*. 1985; 313 :1191-200.
17. Awad IA, Spetzler RF. Extracranial-intracranial bypass surgery: a critical analysis in light of the International Cooperative Study. *Neurosurgery*. 1986; 19 :655-64.
18. Sakai K, Nitta J, Horiuchi T, Ogiwara T, Kobayashi S, Tanaka Y et al.. Emergency revascularization for acute main-trunk occlusion in the anterior circulation. *Neurosurg Rev*. 2008; 31 :69-76.
19. Kirolos RW, Tyagi AK, Ross SA, van Hille PT, Marks PV. Management of spontaneous cerebellar hematomas: a prospective treatment protocol.

- Neurosurgery 2001; 49 : 1378-86.
20. Salvati M, Cervoni L, Raco A, Delfini R. Spontaneous cerebellar hemorrhage: clinical remarks on 50 cases. *Surg Neurol* 2001; 55 : 156-61.
  21. Masiyama S, Niizuma H, Suzuki J. Pontine hemorrhage: a clinical analysis of 26 cases. *J Neurol Neurosurg Psychiatry* 1985; 48 : 658-62.
  22. Shitamichi M, Nakamura J, Sasaki T, Suematsu T, Tokuda S. Computed tomography guided stereotactic aspiration of pontine hemorrhages. *Stereotact Funct Neurosurg* 1990; 54-55: 453-6.
  23. Mendelow AD, Gregson BA, Fernandes HM, Murray GD, Teasdale GM, Hope DT, Karimi A et al. Early surgery versus initial conservative treatment in patients with spontaneous supra tentorial intra cerebral hematomas in the international surgical trial in intra cerebral hemorrhage (STICH): a randomized trial. *Lancet* January 2005; 365: 387-97.
  24. Cho DY, Chen CC, Chang CS, Lee WY, Tso TM. Endoscopic surgery for spontaneous basal ganglia hemorrhage: comparing endoscopic surgery, stereotactic aspiration, and craniotomy in non comatose patients. *Surg Neurol* 2006; 65 : 547-55.
  25. Murthy JM, Choudary GV, Murthy TV, Bhasha PS, Naryanan TJ. Decompressive craniectomy with clot evacuation in large hemispheric hypertensive intra cerebral hemorrhage. *Neurocrit Care* 2005; 2 :258-62.
  26. Singh RVP, Prusmack CJ, Morcos JJ. Spontaneous intra cerebral hemorrhage: non arteriovenous malformation, non aneurysm. In: Winn HR (ed). *Youmans Neurological Surgery*, Fifth edition, 2004; Saunders: 1753-55. City
  27. Teernstra OPM, Evers SMAA, Lodder J, Leffers P, Franke CL, Blaauw G. Stereotactic treatment of intra cerebral hematoma by means of a plasminogen activator. A multi center randomized control trial (SICHPA). *Stroke* April 2003; 34:968-74.
  28. Kim IS, Son BC, Lee SW, Sung JH, Hong JT. Comparison of frame-based and frameless stereotactic hematoma puncture and subsequent fibrinolytic therapy for the treatment of supra tentorial deep seated spontaneous intra cerebral hemorrhage. *Minim Invasive Neurosurg.* 2007; 50 : 86-90.
  29. Thiex R, Rohde V, Rohde I, Mayfrank L, Zeki Z, Thron A et.al. Frame-based and frameless stereotactic hematoma puncture and subsequent fibrinolytic therapy for the treatment of spontaneous intra cerebral hemorrhage. *J Neurol* 2004; 251:1443-50.
  30. Zhang Z, Li X, Liu Y, Shao Y, Xu S, Yang Y. Application of Neuroendoscopy in the treatment of intra ventricular hemorrhage. *Cerebrovasc Dis.* 2007; 24 :91-6.
  31. Sumer MM, Acikgoz B, Akpinar G. External ventricular drainage for acute obstructive hydrocephalus developing following spontaneous intra cerebral hemorrhages. *Neurol Sci* 2002; 23 : 29-33.
  32. Broderick J, Connolly S, Feldmann E, Hanley D, Kase C, Krieger D, Mayberg M et al. Guidelines for the management of spontaneous intra cerebral hemorrhage in adults. A guideline from the American Heart Association/American Stroke Association stroke council, High Blood Pressure Research Council, and the Quality of Care and Outcomes in research interdisciplinary Working Group. *Stroke.* 2007; 38:2001-23.
  33. Enam SA. Role of surgery in cerebral venous sinus thrombosis. *J Pak Med Assoc.* 2006 56 :543-7.