



THE AGA KHAN UNIVERSITY

eCommons@AKU

---

Section of Neurosurgery

Department of Surgery

---

November 2010

# Intracranial cavernous angiomas

Syed Faraz Kazim  
*Aga Khan University*

Atta-ul-Aleem Bhatti  
*Aga Khan University*

S. Ather Enam  
*Aga Khan University, ather.enam@aku.edu*

Follow this and additional works at: [http://ecommons.aku.edu/pakistan\\_fhs\\_mc\\_surg\\_neurosurg](http://ecommons.aku.edu/pakistan_fhs_mc_surg_neurosurg)

 Part of the [Neurology Commons](#), and the [Surgery Commons](#)

---

## Recommended Citation

Kazim, S., Bhatti, A., Enam, S. (2010). Intracranial cavernous angiomas. *Journal of the College of Physicians and Surgeons Pakistan*, 20(11), 738-743.

**Available at:** [http://ecommons.aku.edu/pakistan\\_fhs\\_mc\\_surg\\_neurosurg/1](http://ecommons.aku.edu/pakistan_fhs_mc_surg_neurosurg/1)

# Intracranial Cavernous Angiomas

Syed Faraz Kazim, Atta-ul-Aleem Bhatti and Syed Ather Enam

## ABSTRACT

**Objective:** To describe the clinical presentation, diagnosis, and management of patients presenting with intracranial cavernous angiomas (CAs) at a tertiary care hospital in Pakistan.

**Study Design:** Case series.

**Place and Duration of Study:** Section of Neurosurgery, The Aga Khan University Hospital (AKUH), Karachi, from January 1990 to September 2008.

**Methodology:** A retrospective case note review of all patients diagnosed with intracranial CAs at AKUH during the study period. The studied variables included patient demographics, clinical presentation, family history of intracranial CAs or other space occupying lesions, modality of diagnosis, management, and outcome. Results were described as frequency percentages.

**Results:** During the review period, 18 patients (11 males and 7 females) were diagnosed with intracranial CAs. The median age at diagnosis was 28.5 years. The most common location of malformations was cerebrum (n=13) followed by brain stem (n=3), and cerebellum (n=2). Nine patients had multiple lesions. Family history was present in 2 patients. Seizures and focal neurologic deficits were the main clinical manifestations. The detection rate was 93.8% with magnetic resonance imaging, but less with angiography and computerized tomography. Ten cases were treated surgically; 8 were managed conservatively. The outcome was satisfactory except for one patient, who died within 6 months of diagnosis. Surgery was performed for gross haemorrhage, rapidly increasing neurologic deficits, and intractable or long-standing seizures.

**Conclusion:** Cavernomas tend to occur at younger age in females than males. This data raises a possibility of a higher frequency of multiple cavernomas in Pakistani patients. The main clinical manifestations are seizures and focal neurologic deficits. MRI is most sensitive and specific neuroradiologic modality for detecting this vascular malformation.

**Key words:** Intracranial cavernous angiomas. Neuroradiology. MRI. Haemorrhage. Seizure. Focal neurologic deficit.

## INTRODUCTION

The four main central nervous system (CNS) vascular malformations are arteriovenous malformations, cavernous angiomas (CAs), venous angiomas, and capillary telangiectasias.<sup>1</sup> The intracranial CAs are well circumscribed benign hamartomatous berry-like collection of irregular thick and thin walled sinusoidal vascular channels located within the brain but lacking intervening neural parenchyma.<sup>2,3</sup> They are usually 1-5 cm in size; multiple in 7-24% of patients.<sup>2,3</sup> The periphery of the lesions may contain cavernous lobules invading adjacent brain tissue. Intracranial CAs have no connective tissue capsule, but are usually well delimited by peripheral gliosis. Thrombosis and haemorrhage may occur within these lesions leading to calcification. Cholesterol and haemosiderin deposits may also be found.<sup>3,4</sup> Since intracranial CAs are low flow vascular lesions, their angiographic appearance is avascular, and

they are classified as 'cryptic' or 'angiographically occult' CNS vascular malformations.<sup>3</sup> Cavernous angiomas comprise 5-13% of all CNS vascular malformations.<sup>4-7</sup> They are usually located in supratentorial compartment (70-80%), preferably in the white matter, but 10-20% are located in the posterior fossa with a predilection for the pons; 5-10% are found in the spine as well.<sup>4-7</sup> Cavernous angiomas of the pineal region, cavernous sinus, suprasellar region, third ventricle, lateral ventricle, and dura have also been reported.<sup>4-8</sup> Intracranial CAs are sporadic or hereditary. They are usually asymptomatic, but when symptoms are present, they depend on the location and size of the lesion. Seizures, progressive neurologic deficits, and haemorrhage are the most frequent clinical manifestations.<sup>4,6</sup> Computerized tomography (CT) and magnetic resonance imaging (MRI) have proved to be useful diagnostic tools for intracranial CAs. T2 weighted MRI is the most sensitive test for the diagnosis of intracranial CAs.<sup>9,10</sup> Surgical excision is recommended for accessible lesions with focal deficit or haemorrhage.<sup>11</sup>

Intracranial CAs have remained unexplored in Pakistan. No clinical data is available regarding the clinical manifestations, neuroradiology, and prognosis of intracranial CAs in Pakistan. The aim of this study was to describe experience with CAs of the brain at a tertiary care hospital in Pakistan.

*Section of Neurosurgery, Department of Surgery, The Aga Khan University Hospital, Karachi.*

**Correspondence:** Dr. Syed Ather Enam, Section of Neurosurgery, Department of Surgery, The Aga Khan University Hospital, Stadium Road, P. O. Box. 3500, Karachi-74800.  
E-mail: ather.enam@aku.edu

Received September 16, 2009; accepted September 01, 2010.

## METHODOLOGY

Cases of intracranial CAs were evaluated in a retrospective, case note review of all patients presenting with intracranial CAs at The Aga Khan University Hospital (AKUH), Karachi, Pakistan, over a period of 18 years from January 1990 to September 2008. The hospital's computerized database with ICD-9-CM (International classification of diseases, Ninth revision, clinical modification) coding system was queried to identify patients with intracranial CAs. The case notes of all identified patients were retrieved and reviewed. All data were collected on a proforma specifically designed for the purpose. The study variables included patient demographics, presenting signs and symptoms, comorbidities, family history of intracranial CAs or other space occupying lesions, modality of diagnosis, management, and outcome of treatment of particular note were the indication for surgery. The results were described in terms of descriptive statistics.

## RESULTS

The hospital database revealed 18 patients [11 (61.1%) males and 7 (38.9%) females] of intracranial CAs admitted during 1990-2007. Majority of patients were in the age group 21 - 35 years (12 out of 18, 66.67%). The median age at presentation was 28.5 years (range 2 - 67 years).

Table I shows the symptomatic checklist, mode of diagnosis, and outcome of each patient. Intracranial CAs were located in the following sites: 13 in cerebral hemispheres (4 each in frontal, temporal and parietal lobes, 1 occipital lobe), 3 in the brain stem, 2 in the cerebellum, 2 in the caudate nucleus and 1 each in the

basal ganglia, thalamus, cerebellopontine angle and hypothalamus. Nine patients (50%) had multiple lesions. Family history of intracranial CAs was present in 2 patients.

The clinical manifestations in 18 patients with intracranial CAs were seizures (n=10, 55.5%), focal neurologic deficits (n=8, 44.5%), headache (n=7, 38.8%), brain stem syndromes (n=3, 16.7%), hemiplegia (n=1, 5.5%), and cerebellar syndromes (n= 3, 16.7%). Haemorrhage occurred in 6 (33.4%) of the cases. Two patients (Patient 16 and 18 in Table I) had a recurrent episode of intracranial bleeding, 6 months and 2 months after the initial haemorrhage respectively.

Only 1 of the 8 angiograms carried out showed specific findings such as staining in the capillary phase while the remaining 7 showed non-specific findings such as vascular displacement and early drainage. Computed tomography allowed detection in 5 out of the 10 patients in whom it was used. Magnetic resonance imaging was carried out in 16 out of 18 patients and revealed specific findings of CAs in 15 (93.8%) patients and non-specific in one patient.

Ten patients underwent surgical excision whereas remaining 8 patients were managed conservatively. Surgery was performed for gross haemorrhage, rapidly increasing neurologic deficits, intractable or long-standing seizures. The outcome was good in all patients except for one patient with multiple cavernomas in cerebellum and in the region of fourth ventricle who died within 6 months of diagnosis. This patient was managed conservatively. The reason of death was cardio-pulmonary arrest. No mortality was noted in the patients who were treated surgically.

**Table I:** Clinical characteristics of 18 patients with intracranial cavernous angiomas.

Case	Age (years)	Gender	Location of lesion(s)	Presenting signs and symptoms	Duration of symptoms	Mode of diagnosis	Management	Outcome
1	28	Female	Caudate nucleus	Seizures, headache	3 years	MRI	Conservative	Good
2	27	Male	Frontal lobe, cerebral peduncles	Headache, Right-sided weakness	1 year	MRI	Surgical	Good
3	30	Female	Brain stem	Weakness of cranial nerves VII, VIII, and IX	6 months	CT	Conservative	Good
4	23	Female	Hypothalamus	Headache	1 year	MRI	Conservative	Good
5	62	Male	Cerebello-pontine angle, fourth ventricle	Dizziness, slurred speech, severe vomiting, in coordination	2 years	CT and MRI	Surgical	Good
6	35	Male	Parietal lobe	Headache	3 years	MRI	Surgical	Good
7	65	Male	Parietal and occipital lobes	Seizures, left-sided weakness	1 month	CT	Conservative	Good
8	27	Male	Temporal lobe, basal ganglia, thalamus	Seizures	2 months	MRI	Conservative	Good
9	26	Female	Caudate nucleus, lateral ventricle	Seizures, headache, weakness	4 years	MRI	Conservative	Good
10	2	Male	Parietal lobe	Seizures	7 days	MRI	Surgical	Good
11	33	Female	Cerebellum, fourth ventricle	Incoordination	3 months	MRI	Conservative	Expired
12	67	Male	Temporal lobe	Seizures, right-sided weakness	5 years	CT and MRI	Conservative	Good
13	58	Male	Frontal lobe	Seizures, left lower limb weakness	15 days	MRI	Surgical	Good
14	27	Male	Temporal lobe	Seizures, fainting episodes	7 years	MRI	Surgical	Good
15	7	Male	Frontal and parietal lobes	Seizures, hemiplegia	2 days	Angiography, CT, and MRI	Surgical	Good
16	29	Female	Temporal lobe	Seizures, headache	1 year	MRI	Surgical	Good
17	28	Male	Brain stem, cerebellum	Headache, Left sided cranial nerve VII palsy	2 months	MRI	Surgical	Good
18	31	Female	Brain stem	Right-sided weakness, cranial nerves VII, VIII, and IX palsies	7 months	MRI	Surgical	Good

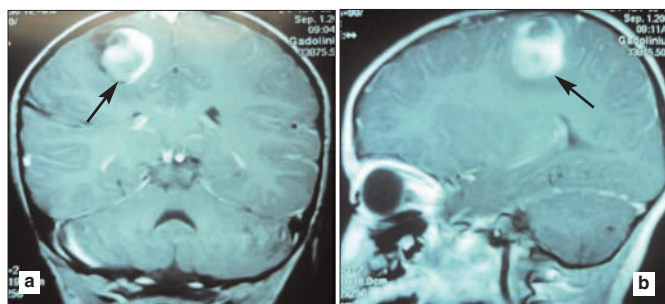
**Abbreviations:** CT=Computed tomography; MRI=Magnetic resonance imaging.

**Table II:** Current series in the context of published literature on intracranial cavernous angiomas.

Authors (reference)	No. of cases	M/F	Location of lesions	Clinical features	Mode of diagnosis	Treatment
Requena <i>et al.</i> <sup>14</sup>	47	21/26	Cerebral hemisphere (FL=4, TL=13, PL=8, OL=2), pons=10, cerebellum=6, thalamus=4, cerebral peduncles=4, medulla=2, spinal cord=1	Seizures=16, brainstem syndromes=14, focal neurologic deficits=5, SAH=1, cerebellar syndromes=2, intra-cranial hypertension=1, spastic paraparesis=1	No detection with 24 angiograms done, CT-scan detected in 40 of 45 patients in whom it was used, MRI showed 56 cavernomas in 47 patients studies, 6 had multiple lesions	Surgical removal performed in 18 cases.
Attar <i>et al.</i> <sup>11</sup>	35	25/10	Cerebral hemisphere=21, Cerebellum=6, thalamus=4, lateral ventricle=4	Headache=18, seizures=13, focal neurological deficits=9, brain stem syndromes=2	Angiography detected 3 cases out of 28 in whom it was done, CT 10 out of 26, and MRI 26 out of 28.	Surgical removal in all 35; good outcome in 34 patients, 1 died.
Pozatti <i>et al.</i> <sup>12</sup>	18	5/13	Cerebral hemispheres (FL=4, TL=1, PL=1, OL=1), thalamus=4, cerebellum=3, diencephalon=2, caudate nucleus=2 brain stem=1.	Hemiparesis=6, Seizures=4, acute cerebellar syndrome=3, hemisensory deficit=1, brain stem syndrome=1, hypothalamic syndrome=1, asymptomatic=1.	Angiography negative in all; all cases detected by CT and MRI	Surgical removal in 12, conservative management in 6. Good outcome in 10 patients, minor deficit in 6, 1 dependent, 1 died.
Wurm <i>et al.</i> <sup>25</sup>	15	8/7	Cerebral hemispheres (FL=3, TL=5, OL=1), insular cortex=2, brain stem=1, cerebellum=1, paraventricular=1, caudate nucleus=1.	Seizures=9, headache=2, dizziness=2, ataxia=1, asymptomatic=1.	All cases detected by MRI.	Surgical resection in all 15; recurrence in 3 cases.
Current series	18	11/7	Cerebral hemispheres (FL=4, TL=4, PL=4, OL=1), brain stem=3, cerebellum=2, caudate nucleus=2, basal ganglia=1, thalamus=1, cerebellopontine angle=1, hypothalamus=1.	Seizures=10, focal neurological deficits=8, headache=7, brain stem syndromes=3, cerebellar syndromes=3, hemiplegia=1	Angiography detected 1 out of 8, CT 5 out of 10, and MRI 16 out of 18 in whom carried out	Surgical excision in 10 cases; conservative management in 8. Good outcome in all except one who died.

Abbreviations: FL=Frontal lobe, TL=Temporal lobe, PL=Parietal lobe, OL=Occipital lobe

The MRI scans of a patient with CA in the parietal lobe (patient number 10 in the Table I) are shown in Figure 1. Table II compares the results of this study with some of the previously published case series of intracranial CAs.



**Figure 1a and b:** Magnetic resonance imaging demonstrating the intracranial cavernous angioma in the right parietal lobe as a hyperintense lesion surrounded by edema in contrast-enhanced T1 weighted images (arrows). Flow voids can be identified in the periphery of the lesion. The scans are of Case no. 10 in Table I.

## DISCUSSION

Intracranial CAs belong to a group of vascular malformations that are developmental malformations of the vascular bed. They consist of thin walled sinusoids with no intervening neural tissue. These congenital vascular malformations frequently enlarge over time. The growth patterns of intracranial CAs are mainly related to repeated intralesional haemorrhage and thrombosis, to the expansion of haemorrhagic cyst cavities, to the deposition of haemosideric pigments, and to the

reactive gliosis that enlarges with time.<sup>2,12,13</sup> Intracranial CAs vary from several millimeters to several centimeters (usually < 3 cm) in diameter.

Familial occurrence has been reported by some studies in up to 50% of patients.<sup>1-3</sup> However, other studies have found a lower occurrence of familial intracranial CAs. Requena *et al.* have reported a 4.3% incidence of familial cavernomas.<sup>14</sup> Similarly Attar *et al.* reported that only one patient in their series of 35 intracranial CAs patients had a familial occurrence.<sup>11</sup> Family history of intracranial CAs was found in 2 out of 18 (11%) patients in current series. The vast difference in various studies regarding the familial occurrence can also be attributed to methodological issues. With retrospective chart note reviews, like this case series, there is always a chance of underestimation of variables like familial occurrence, because these studies do not systematically investigate the families of the patients. Family screening has been reported to increase the number of diagnosis of familial cavernomas.<sup>15</sup>

Past studies have reported the incidence of intracranial CAs to be equal for either gender,<sup>5</sup> greater in males than females,<sup>16</sup> and greater in females than males.<sup>17</sup> In the current series, the number of males (n=11, 61%) was more than the number of females (n=7, 39%). Requena *et al.* have reported a trend of an earlier clinical manifestation in young male patients.<sup>14</sup> In their study, 52% of male patients were diagnosed before the age of



30 years, compared with only 11.5% of female patients. In the present series, 6 (54.5%) of male patients were diagnosed before the age of 30 years, whereas 4 (57%) of female patients were diagnosed with age less than 30 years. However, none of the females in this series were more than 40 years of age as compared to male cases, among which 2 were in 50s and 2 in 60s. Hormonal factors have been speculated to play some role in the biology of cavernomas.<sup>12,14</sup> The metabolic activity of cerebral CAs can be altered by estrogens, which may induce platelet-mediated thrombosis.<sup>18</sup> Recent findings indicate that the growth and the progression of the clinical picture of hemangioblastomas may be accelerated by sex hormones.<sup>12,18</sup> The size of cavernous malformations is known to increase during pregnancy and to decrease after delivery.<sup>19</sup> The increase in the blood volume occurring during pregnancy might be an important factor in angioma rupture.<sup>6</sup> However, endocrine factors may influence their haemorrhagic tendency, particularly in the first trimester, which is characterized by vascular proliferation of the endometrium associated with secretion of human chorionic gonadotropin, progesterone, and estrogen.<sup>20</sup>

The haemorrhagic capacity of intracranial CAs is obvious. Acute gross haemorrhage, small subclinical bleeding, or even slow extravasation of red blood cells may occur.<sup>12</sup> It is known that CAs may be found incidentally during surgery in patients who apparently have intracerebral hematomas.<sup>21</sup> There is also a risk of subsequent haemorrhage after the initial bleeding. Pozzati *et al.* have reported the recurrence duration from 1 week to 3 years, with a median time of 11 months.<sup>12</sup> Others have also reported an interval from initial haemorrhage to first recurrence ranging from 1 to 60 months (average, 12 months).<sup>22</sup> Six out of 18 patients, 4 females and 2 males, in this series had haemorrhage. Recurrence occurred in 2 patients (both females) with a duration range of 2-6 months. Zimmerman *et al.* have reported a series of 16 patients (13 females and 3 males) with brain stem cavernous malformations characterized by repeated bleeding that sometimes occurred in the weeks ensuing the first haemorrhage.<sup>23</sup> The patient in this series who had a recurrent episode of bleeding within 2 months had also a brain stem cavernoma.

The reported incidence of multiple intracranial CAs is 7-24%.<sup>1-3</sup> Nine out of 18 (50%) patients in this series had multiple lesions. Our data raises a possibility of a higher incidence of multiple intracranial CAs in this part of the world. However, a single center data is not sufficient to justify such claims. We need similar reports from other centers to verify this finding.

The location of intracranial CAs has been speculated to play a role in the natural behaviour of CAs. Cavernomas of the third ventricle sometimes demonstrate rapid

and extensive growth; a possible explanation is strong hormonal influence due to the site.<sup>19</sup> The high mortality of brain stem and basal ganglia CAs can be related to the high sensitivity of these regions even to small bleedings.<sup>12</sup>

The clinical manifestations of cavernous angiomas are reported to be seizures in 60-70% of the cases, headache in 25-50%, progressive neurological deficits in 20-50%, and haemorrhage in < 20%.<sup>5,16</sup> In this study, there were seizures in 55.5%, focal neurologic deficits in 44.5%, headache in 38.8%, brainstem syndromes in 16.7%, cerebellar syndromes in 16.7% and haemiplegia in 5.5%. The location of the cavernomas generally correlated well with the clinical presentations. Majority of the present patients had supra tentorial lesions; seizures were thus the most common clinical manifestation in this series. A solitary cavernoma in the hypothalamus, however, interestingly presented with headache only, no hypothalamic or pituitary dysfunction was noted.

Most cavernous malformations are angiographically occult, and when they are evident on angiograms, the findings are non-specific.<sup>14,16</sup> Although intracranial CAs may be apparent and can be diagnosed with CT scans, it is not the imaging modality of choice.<sup>9,10</sup> Computed tomography findings are compatible not only with intracranial CAs but also with low-grade tumours, among other entities.<sup>9,10</sup> The sensitivity of MRI to flowing blood and blood products of varying ages, as well as the greater contrast resolution of MRIs, greatly increases the specificity of MRI compared with that of CT.<sup>10,24</sup> Combining multiple MRI sequences has largely eliminated misdiagnosis of intracranial CAs, because they have relatively specific signal characteristics. Additionally, gradient - echo imaging, with its increased sensitivity to susceptibility artifact, is useful in the detection of smaller and concomitant lesions, which may not be detected with traditional sequences.<sup>10,24</sup>

Computed tomography and magnetic resonance imaging can both be used in the follow-up monitoring of patients with known intracranial CAs, particularly when haemorrhagic events are suspected.<sup>10,24</sup> Although the MRI appearance of intracranial CAs is not helpful in predicting future bleeds, MRI is the method of choice for the long-term follow-up of patients with intracranial CAs and for the assessment of family members in whom similar lesions are suspected.<sup>24</sup> In addition, MRI is extremely helpful in pre-surgical planning to assess the extent of the lesion, define borders, and plan the surgical approach and exposure.<sup>24</sup>

All patients in this series underwent neuroradiological studies including angiography, CT, and MRI; sometimes multiple modalities were used. Angiography failed to reveal cavernoma in 7 of the 8 cases in which it was

performed. The CT scan was not always diagnostic, whereas MRI showed typical features of cavernomas in 93.8% of the patients in whom it was used.

Surgical removal of intracranial CAs is recommended for intractable seizures, rapidly increasing neurological deficits, and also to prevent gross haemorrhage and lesion growth.<sup>11,25</sup> Surgical excision of an intracranial CA prevents its growth, and thus terminates the related clinical manifestations. It also helps in confirming the diagnosis when there are doubts regarding the underlying pathology.<sup>11,25</sup> Ten patients in this series underwent surgical removal of intracranial CAs, with modest outcomes.

This series of 18 intracranial CA cases is the largest by far from Pakistan. This small number for a 19 years record at one of the largest tertiary care hospital in Pakistan suggests that either the prevalence of intracranial CAs is low in the country, or that the disorder is seldom brought to clinical attention. The latter could be supported on the grounds that Pakistan, like its neighbouring regions, is burdened with the wrath of communicable diseases, which are responsible for the major share of infant, childhood, and adult mortality, and hence obscure the actual incidence of non-communicable diseases.

## CONCLUSION

Intracranial cavernous angiomas are developmental malformations of the vascular bed. Familial occurrence is variable. Although, there may not be any specific gender predilection, but hormonal factors may play a role in the biology of intracranial CAs. The number of multiple lesions was noted to be higher in this series as compared to reports from other geographical areas. Seizures, focal neurological deficits, headache, and haemorrhage constitute the most common clinical manifestations and indeed the reasons for surgery. Angiography is unsuitable for detecting this vascular malformation. Magnetic resonance imaging remains the modality of choice, with high sensitivity and specificity for detecting intracranial CAs.

## REFERENCES

- Stein BM, Mohr JP. Vascular malformations of the brain. *N Engl J Med* 1988; **319**:368-9.
- Simard JM, Garcia-Bengochea F, Ballinger WE Jr, Mickle JP, Quisling RG. Cavernous angiomas: a review of 126 collected and 12 new clinical cases. *Neurosurgery* 1986; **18**:162-72.
- Yasargil MG. Venous, cavernous and occult angiomas. In: Yasargil MG, editor. *Microneurosurgery*. Stuttgart: Georg Thieme Verlag; 1988.p. 405-38.
- Porter PO, Willinsky RA, Harper W, Wallace MC. Cerebral cavernous malformations: natural history and prognosis after clinical deterioration with or without haemorrhage. *J Neurosurg* 1997; **87**:190-7.
- Voigt K, Yasargil MG. Cerebral cavernous haemangiomas or cavernomas. Incidence, pathology, localization, diagnosis, clinical features, and treatment. Review of the literature and report of an unusual case. *Neurochirurgia* 1976; **19**:59-68.
- Wilkins RH. Natural history of intracranial vascular malformations: a review. *Neurosurgery* 1985; **16**:421-30.
- Acciarri N, Padovani R, Giulioni M, Gaist G, Acciarri R. Intracranial and orbital cavernous angiomas: a review of 74 surgical cases. *Br J Neurosurg* 1993; **7**:529-39.
- Vaquero J, Leunda G, Martinez R, Bravo G. Cavernomas of the brain. *Neurosurgery* 1983; **12**:208-10.
- Kramer RA, Wing SD. Computed tomography of angiographically occult cerebral vascular malformations. *Radiology* 1977; **123**:649-52.
- New PF, Ojemann RG, Davis KR, Rosen BR, Hero R, Kjellberg RN, et al. MR and CT of occult vascular malformations of the brain. *AJR Am J Roentgenol* 1986; **147**:985-93.
- Attar A, Ugur HC, Savas A, Yüceer N, Egemen N. Surgical treatment of intracranial cavernous angiomas. *J Clin Neurosci* 2001; **8**:235-9.
- Pozzati E, Acciarri N, Tognetti F, Marliani F, Giangaspero F. Growth, subsequent bleeding, and de novo appearance of cerebral cavernous angiomas. *Neurosurgery* 1996; **38**:662-9; discussion 669-70.
- Steiger HJ, Markwalder TM, Reulen HJ. Clinicopathological relations of cerebral cavernous angiomas: Observations in eleven cases. *Neurosurgery* 1987; **21**:879-84.
- Requena I, Arias M, López-Ibor L, Pereiro I, Barba A, Alonso A, et al. Cavernomas of the central nervous system: clinical and neuroimaging manifestations in 47 patients. *J Neurol Neurosurg Psychiatry* 1991; **54**:590-4.
- Allard JC, Hochberg FH, Franklin PD, Carter AP. Magnetic resonance imaging in a family with hereditary cerebral arteriovenous malformations. *Arch Neurol* 1989; **46**:184-7. Comment in: *Arch Neurol* 1989; **46**(12):1273.
- Giombini S, Morello G. Cavernous angiomas of the brain. Account of fourteen personal cases and review of the literature. *Acta Neurochirurgica* 1978; **40**:61-82.
- Yamasaki T, Handa H, Yamashita J, Paine JT, Tashiro Y, Uno A, et al. Intracranial and orbital cavernous angioma: a review of 30 cases. *J Neurosurg* 1986; **64**:197-208.
- Comair Y, LeBlanc R, Robitaille Y. Effects of estrogen on cerebral arteriovenous malformations *in vitro*: towards a new paradigm. *J Neurosurg* 1990; **72**:337A.
- Katayama Y, Tsubokawa T, Maeda T, Yamamoto T. Surgical management of cavernous malformations of the third ventricle. *J Neurosurg* 1994; **80**:64-72.
- Robinson JL, Hall CJ, Sedzimir CB. Sub-arachnoid haemorrhage in pregnancy. *J Neurosurg* 1972; **36**:27-33.
- Wakai S, Ueda Y, Inoh S, Nagai M. Angiographically occult angiomas: a report of thirteen cases with analysis of the cases documented in the literature. *Neurosurgery* 1985; **17**:549-56.
- Tung H, Giannotta SL, Chandrasoma PT, Zee CS. Recurrent intraparenchymal haemorrhages from angiographically occult

- vascular malformations. *J Neurosurg* 1990; **73**:174-80. Comment in: *J Neurosurg* 1991; **74**:527-8.
23. Zimmermann RS, Spetzler RF, Lee KS, Zabramski JM, Hargraves RW. Cavernous malformations of the brainstem. *J Neurosurg* 1991; **75**:32-9.
24. Rigamonti D, Drayer BP, Johnson PC, Hadley MN, Zabramski J, Spetzler RF. The MRI appearance of cavernous malformations (angiomas). *J Neurosurg* 1987; **67**:518-24.
25. Wurm G, Schnizer M, Fellner FA. Cerebral cavernous malformations associated with venous anomalies: surgical considerations. *Neurosurgery* 2005; **57**:42-58; discussion 42-58. Comment in: *Neurosurgery* 2007; **61**:390-404; discussion 404-6.

