

# Hydatid disease of the breast

Masroor I, Azeemuddin M, Khan S, Barakzai A

## ABSTRACT

Cystic hydatid disease is caused by the parasite *Echinococcus granulosus*. Humans are the accidental intermediate hosts of this organism. Hydatid disease is endemic in countries in which raising sheep and cattle constitutes an important means of livelihood. The most commonly affected organs are the liver and lungs. Involvement of the kidney, bone, brain and other organs is rare. Breast involvement in this disease is also very rare. A case of isolated hydatid cyst of the breast is presented, along with a review of the literature and a discussion on the pertinent clinical and radiological aspects of the disease.

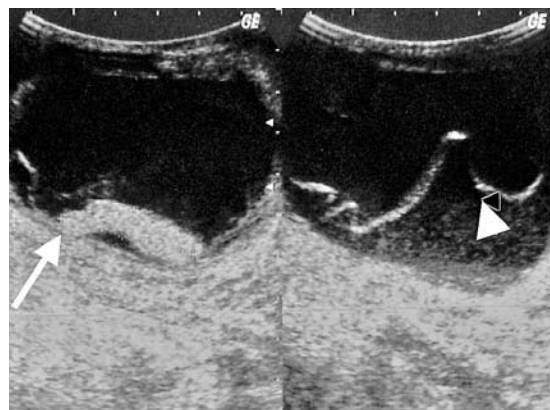
**Keywords:** breast, *Echinococcus*, endemic disease, hydatid cyst, ultrasound

*Singapore Med J 2010;51(4):e72-e75*

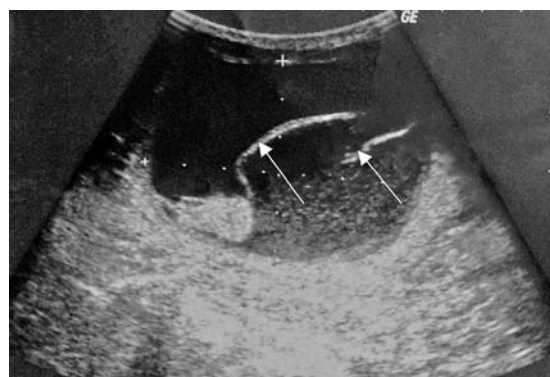
## INTRODUCTION

Hydatid cysts are a manifestation of infection at the larval stage of *Echinococcus granulosus*. Echinococcosis is caused by the larval stage of the tapeworm. There are four species, and the majority of human infestations are caused by *Echinococcus granulosus*, which causes cystic echinococcosis. *Echinococcus multilocularis* causes alveolar disease, which is seen less frequently in human beings. In cystic echinococcosis, the human is an aberrant host and is infected by the oral ingestion of excreta from an infected dog.<sup>(1)</sup>

Hydatid disease is found in all continents, with the highest prevalence in parts of Eurasia (especially in Mediterranean countries, the Russian Federation and its adjacent independent states, as well as China), north and east Africa, Australia and South America.<sup>(2)</sup> The most commonly involved organs are the liver (75%) and lungs (15%), with only 10% of cases occurring in other parts of the body.<sup>(3,4)</sup> The breast is a very rare site of infestation, constituting only 0.27% of all infections.<sup>(5)</sup> The typical findings in this disease are well established, but findings pertaining to its complications and presentation at unusual anatomical locations have not been adequately reported in the literature. In the breast, cystic hydatid may present as a well-circumscribed lesion, and the differential diagnoses include a simple cyst, fibroadenoma, phyllodes tumour, or even rarely, an intracystic carcinoma. In endemic



**Fig. 1** Ultrasonographic images of the axial section show a cystic structure with thick echogenic debris at the bottom (arrow) and a thin undulating detached germinal layer (arrow head).



**Fig. 2** Ultrasonographic image of the longitudinal section shows multiple swirling membranes within the cyst (arrows).

areas, it should be a differential diagnosis of a well-circumscribed breast mass. Due to the increasing ease of travel between countries, it should also be included as a differential diagnosis of a well-circumscribed breast mass in non-endemic countries. This is important so as to avoid complications and morbidity associated with an undiagnosed disease.

## CASE REPORT

A 20-year-old Afghan woman presented to the surgery clinic with a lump in her left breast for the past three years. The lump had gradually increased in size and had become painful. On examination, the overlying skin of the left breast was erythematous, and the lump was tender, with a thickening of the overlying skin and peau d'orange. There was a palpable lumpy area in the upper half of the left breast. The lump was aspirated twice in

Department of  
Radiology,  
Aga Khan  
University Hospital,  
Stadium Road,  
Karachi 74800,  
Pakistan

Masroor I, MBBS,  
FCPS  
Assistant Professor

Azeemuddin M,  
MBBS, FCPS  
Associate Professor

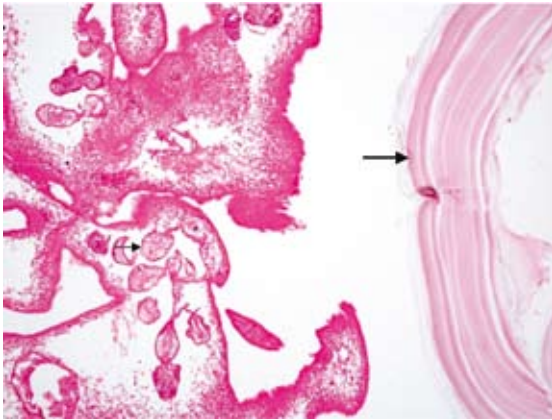
Department of  
Surgery

Khan S, MBBS,  
FRCS  
Professor

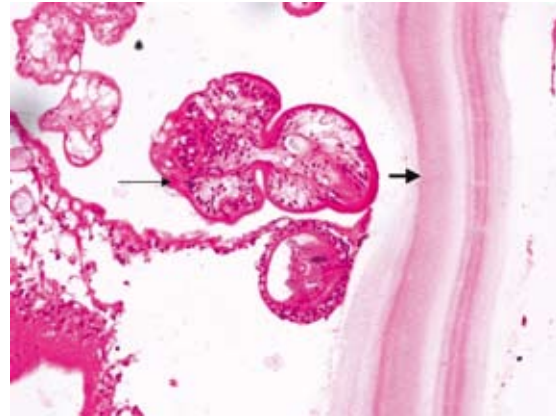
Department of  
Pathology

Barakzai A, MBBS,  
FCPS  
Assistant Professor

**Correspondence to:**  
Dr Imrana Masroor  
Tel: (92) 21 4862052  
Fax: (92) 21 4934294  
Email: imrana.  
masroor@aku.edu



**Fig. 3** Photomicrograph of the hydatid cyst shows amorphous densely-staining laminated chitinous material at the right-hand corner (thick arrow). Daughter cysts and brood capsules with scolices can be observed in the centre (thin arrow) (Haematoxylin & eosin,  $\times 100$ ).



**Fig. 4** Photomicrograph of the hydatid cyst shows amorphous densely-staining laminated chitinous material at the right-hand corner (thick arrow). Daughter cysts and brood capsules with scolices can be observed in the centre (thin arrow). (Haematoxylin & eosin,  $\times 400$ ).

Afghanistan to reduce its size, and to alleviate the pain and associated inflammation. The patient wanted to have the lump removed.

An ultrasonography was performed, which showed a well-defined lesion in the upper outer quadrant of the left breast, extending from the 11–3 o'clock position. The lesion was cystic with thick echogenic debris, and a thick echogenic area was also observed in the dependent portion (Fig. 1). Multiple swirling membranes were also identified within the lesion (Fig. 2). The lesion measured 10 cm  $\times$  7.3 cm. A few lymph nodes were also observed in the left axilla with intact echogenic hilum and measuring less than 1 cm in the short-axis diameter. A diagnosis of breast abscess was made. An incision and drainage of the abscess was performed in the operating theatre under general anaesthesia.

During the procedure, clear fluid was aspirated from the swelling. Upon making the incision, a white membranous cyst was observed inside a thick cavity. The cyst was removed intact, and the wound was packed after irrigation with normal saline. Postoperatively, the patient was put on albendazole and a daily dressing routine with 4% formalin. The histopathology report confirmed the diagnosis and noted features that were compatible with hydatid cysts along with daughter cysts (Figs. 3 & 4).

Following the removal of the cyst, the patient developed wound dehiscence, and wound debridement was performed under general anaesthesia. A corrugated drain was left in place. The patient was put on 400 mg albendazole four times a day. After two weeks, the wound healed well and the drain was removed. The patient was put on three cycles of 400 mg albendazole four times a day for two weeks, followed by an interval of two weeks. Postoperatively, the chest radiography and ultrasonography of the abdomen were normal. The

patient underwent a breast ultrasonography at the one-year follow-up, which was reported to be normal. She was disease free for three years after the initial treatment.

## DISCUSSION

Hydatid disease is an endemic illness in many parts of the world and a major public health concern. As a result of increased affluence and migration, hydatid disease has even spread to non-endemic areas. It can occur almost anywhere in the body and demonstrates a variety of imaging features that vary depending on the growth stage, associated complications and affected tissue. Radiologic findings range from a purely cystic lesion to a completely solid appearance. The breast can be a part of the disseminated disease or the only primary site, which is very rare, with a reported incidence of only 0.27%.<sup>(5)</sup> Most instances of this disease that have been reported in the literature are isolated case reports. Hydatid cysts of the breast are rarely part of large patient series of systemic hydatid disease.<sup>(6)</sup> Breast hydatid mostly occurs in women aged 30–50 years old.<sup>(7)</sup> In our case, the patient was 20 years of age. Typically, the patient presents with a breast lump of a long duration, as in our case (three years).

The imaging method selected for screening depends on the affected organ and the growth stage of the cyst. Routine chest radiography, ultrasonography, computed tomography (CT) and magnetic resonance (MR) imaging can all depict hydatid cysts. However, ultrasonography is the screening method of choice for the classification of cysts.<sup>(8)</sup> As our patient was young, mammography was not performed, and the patient was subjected to a breast ultrasonography instead. The results showed a breast cyst with thick echogenic debris at the bottom of the cyst and multiple swirling membranes within the lesion.

As hydatid disease of the breast is very rare, a diagnosis of breast abscess was made, and incision and drainage were recommended. In the literature, the sonographic appearances that have been described are similar to the appearance of hydatid disease elsewhere in the body, ranging from a purely cystic lesion to a completely solid-appearing mass. Floating membranes, daughter cysts and vesicles are also demonstrated on ultrasonography, while mammography usually shows a well-circumscribed soft tissue density mass. The differential diagnoses include cyst, fibroadenoma, phyllodes tumours, and rarely, circumscribed carcinomas. Due to the rarity of this condition, the diagnosis was missed on ultrasonography. This is a well-reported occurrence in the literature. The diagnosis is usually made on aspiration cytology or perioperatively.<sup>(9)</sup>

The CT appearance of a hydatid cyst is of a low attenuation cystic mass with a high attenuation periphery, and it may reveal multiple cysts and a solid component. CT is the best imaging modality for cyst wall calcification, revealing the internal cystic structure posterior to calcification, especially in cases of liver hydatid. MR imaging typically shows a cyst or a cyst within a cyst, a peripheral hypointense ring around the cyst, collapse of the germinative layer due to the death of the scolices and hexacanth embryo, and no production of cystic fluid or damage by aspiration or trauma.<sup>(10)</sup>

Treatment should be provided for symptomatic disease, and even for asymptomatic cysts, or if the vital anatomical structures are affected. Regarding drug treatment, there is a controversy with respect to the most suitable drug regime. High-dose albendazole was first used in 1970; however, it was toxic and ineffective.<sup>(11)</sup> Several studies that have been conducted on the efficacy of albendazole have shown that it is only effective if administered in repeated doses. Mohamad et al have suggested that a combination of albendazole and praziquantel, compared with the administration of albendazole alone, decreases the duration of therapy. At present, a combination of albendazole and praziquantel 50 mg/kg seems to be the most suitable medical treatment, but no drug regime has yet been standardised.<sup>(12)</sup>

The benzimidazole compounds, albendazole and mebendazole have been the cornerstone of therapy for cystic echinococcosis. Treatment with albendazole results in the disappearance of up to 48% of cysts and a substantial reduction in size of a further 24%.<sup>(13)</sup> Mebendazole has been found to be less efficacious than albendazole.<sup>(13)</sup> Surgery is reserved for large cysts as well as those that are superficial and likely to rupture, or if they are exerting a substantial mass effect. Cystectomy

is the preferred treatment method and has been found to be universally curative.<sup>(14,15)</sup> Recurrence is usually due to either incomplete cyst removal or previously unidentified cysts. The reported recurrence rates range from 2%–25%.<sup>(16)</sup>

In conclusion, although breast hydatidosis is rare, it should be considered as a differential diagnosis of breast lumps presenting in endemic areas and among migrant populations from endemic areas. In the breast, it may mimic a simple cyst, fibroadenoma, chronic abscess, phyllodes tumour, or even a carcinoma. Radiologists and surgeons should both be aware of this rare but potentially serious breast disease. Radiological imaging findings can generally help to establish the diagnosis, but the occurrence of hydatid disease at an atypical location with unusual imaging findings may make the differential diagnosis difficult. Nevertheless, familiarity with the imaging findings, especially among patients living in endemic regions, is advantageous in this context.

## REFERENCES

1. Kurt Y, Sücüllü I, Filiz AI, Urhan M, Akin ML. Pulmonary echinococcosis mimicking multiple lung metastasis of breast cancer: the role of flouro-deoxy-glucose positron emission tomography. *World J Surg Oncol* 2008; 6:7.
2. Eckert J, Schantz P, Gasser R, et al. Geographic distribution and prevalence. In: Eckert J, Gemell MA, Meslin FX, Pawlowski ZS, eds. WHO/OIE Manual on Echinococcosis in Humans and Animals: a Public Health Problem of Global Concern. Paris: World Organization for Animal Health, 2001:100-41.
3. Engin G, Acunaş B, Rozanes I, Acunaş G. Hydatid disease with unusual localization. *Eur Radiol* 2000; 10:1904-12.
4. Kireşi DA, Karabacakolu A, Odev K, Karaköse S. Uncommon locations of hydatid cysts. *Acta Radiol* 2003; 44:622-36.
5. Abi F, el Fares F, Khaiz D, Bouzidi A. 1989. [Unusual localizations of hydatid cysts. Apropos of 40 cases]. *J Chir (Paris)* 1989; 126:307-12. French.
6. Safioleas M, Misiakos EP, Kakisis J, et al. Surgical treatment of human echinococcosis. 2000; 85:358-65.
7. Ouedraogo EG. [Hydatid cyst of the breast. 20 cases]. 1986 *J Gynecol Obstet Biol Reprod (Paris)* 1986; 15:187-94. French.
8. WHO Informal Working Group. International classification of ultrasound images in cystic echinococcosis for application in clinical and field epidemiological settings. *Acta Trop* 2003; 85:253-61.
9. Kurul S, Tenekeci N, Topuzlu C. Case report: an unusual mass in the breast: the hydatid cyst. *Clin Radiol* 1995; 50:869-70.
10. Chevalier X, Rhamouni A, Bretagne S, Martigny J, Larget-Piet B. Hydatid cyst of subcutaneous tissue without other involvement. MR imaging features. *Am J Roentgenol* 1994; 163:645-6.
11. Unal AE, Ulukent SC, Bayar S, Demirkan A, Akgül H. Primary hydatid cyst of the axillary region: report of a case. *Surg Today* 2001; 31:803-5.
12. Mohamed AE, Yasawy MI, Al Karawi MA. Combined albendazole and praziquantel versus albendazole alone in the treatment of hydatid disease. *Hepatogastroenterology* 1998; 45:1690-4.
13. Horton RJ. Albendazole in treatment of human cystic echinococcosis: 12 years of experience. *Acta Trop* 1997;

- 64:79-93.
14. Franciosi CM, Romano F, Porta G, et al. Surgical treatment of hydatid disease of the liver. An experience from outside the endemic area. *Chir Ital* 2002; 54:667-72.
  15. Tükel S, Erden I, Ciftçi E, Koçak S. Hydatid cyst of breast: MR imaging findings. *Am J Roentegenol* 1997; 168:1386-7.
  16. Ammann RW, Eckert J. Cestodes: Echinococcus. *Gastroenterol Clin North Am* 1996; 25:655-89.