



THE AGA KHAN UNIVERSITY

eCommons@AKU

Department of Radiation Oncology

Medical College, Pakistan

June 2012

# FIGO IVB (para-aortic lymph adenopathy) squamous cell carcinoma of uterine cervix associated with a left pelvic kidney: a therapeutic challenge

Nasir Ali  
*Aga Khan University*

Farrok Karsan  
*Aga Khan University*

Ahmed Nadeem Abbasi  
*Aga Khan University*

Zakaur Rehman Khan  
*Aga Khan University*

Follow this and additional works at: [http://ecommons.aku.edu/pakistan\\_fhs\\_mc\\_radiat\\_oncol](http://ecommons.aku.edu/pakistan_fhs_mc_radiat_oncol)

 Part of the [Oncology Commons](#)

## Recommended Citation

Ali, N., Karsan, F., Abbasi, A., Khan, Z. (2012). FIGO IVB (para-aortic lymph adenopathy) squamous cell carcinoma of uterine cervix associated with a left pelvic kidney: a therapeutic challenge. *Journal of the Pakistan Medical Association*, 62(6), 615-6.

**Available at:** [http://ecommons.aku.edu/pakistan\\_fhs\\_mc\\_radiat\\_oncol/2](http://ecommons.aku.edu/pakistan_fhs_mc_radiat_oncol/2)

## FIGO IVB (Para-aortic lymph adenopathy) squamous cell carcinoma of uterine cervix associated with a left pelvic kidney: A therapeutic challenge

Nasir Ali, Farrok Karsan, Ahmed Nadeem Abbasi, Zakaur Rehman Khan  
 Department of Radiation Oncology, Aga Khan University Hospital, Karachi, Pakistan.  
 Corresponding Author: Nasir Ali. Email: nasir.ali@aku.edu

### Abstract

The standard of care for locally advanced carcinoma of uterine cervix is concurrent chemoradiation therapy followed by intracavitary brachytherapy, when there is para-aortic lymphadenopathy, radiation field needs to be extended to para-aortic region. In the latter case dose limiting organs are spinal cord, kidneys and small intestine. We present a challenging case of FIGO IVB squamous cell carcinoma of cervix and a pelvic kidney. This patient received chemoradiation to pelvis and para-aortic field, brachytherapy was not performed as patient already had undergone attempted hysterectomy. Treatment, outcome and challenges encountered in this case are presented and literature is reviewed.

**Keywords:** Ectopic kidney, Cervical cancer, Chemoradiation therapy.

### Introduction

The standard of treatment of locally advanced cervical cancer is concurrent chemoradiation and brachytherapy.<sup>1</sup> Cervical cancer and pelvic kidney is an uncommon condition and to the best of our knowledge there have been few reported cases of the simultaneous occurrence of these two conditions. Our case is probably the first of its kind, having locally advanced cervical cancer, paraaortic adenopathy and a pelvic kidney.

The radiation tolerance of kidney is 2000 cGy. The normally positioned kidneys are outside the standard pelvic and para aortic fields, but the ectopic pelvic kidney is at risk of radiation nephritis. Also, late complication of renal irradiation is the development of hypertension refractory to medical treatment sometimes necessitating nephrectomy of radiated kidney.<sup>2</sup> We report the case of FIGO IVB cervical squamous cell cancer with left pelvic kidney which was treated with extended field pelvic and paraaortic chemoradiation.

### Case Report

A 54 year patient (Para 6) and a known case of left pelvic kidney, presented with postmenopausal vaginal bleeding; she was otherwise in good health.

General physical examination was unremarkable. Pelvic examination revealed 5x6 cm fungating mass at vaginal vault invading adjacent fornices and bilateral parametria. Cystoscopy and proctosigmoidoscopy was unremarkable. Preoperative pelvic CT scan showed a 5x5 cm cervical mass and left pelvic kidney. She had undergone an attempted hysterectomy at another hospital and histopathology was consistent with squamous cell carcinoma, with positive resection cervical margins. Staging PET/CT scan revealed 1.8 cm lymph node (SUV 6.5) in the left para aortic region at L3/4 interspace and malpositioned/malrotated left pelvic kidney. No distant metastases were detected on PET/CT scan. The case was discussed in Gynaecologic-Oncology tumor board, and chemoradiation was recommended. A urologist was consulted for possibility of transposing the kidney into abdomen which was deemed unfeasible. The risks of long term complication of renal irradiation were explained to the family. Patient was planned with 3-D conformal CT planning. Dimcicpto succinic acid (DMSA) renal scan revealed the relative function of right normally placed kidney 57% and that of left pelvic kidney 43%.

### Technique Of Extended Field Pelvic And Para Aortic Radiation Therapy:

Treatment was planned on Eclipse (3-D) treatment planning system. Isocenter was placed at L 4/5 interspace. In phase I, para-aortic field was planned using AP/PA fields and the pelvis was planned using four fields. The dose prescribed was 45 Gy at 1.8 Gy/fraction five days a week using 18 MV photon energy. In phase II, pelvis was boosted to a total dose of 50.4 Gy along a separate small field to the paraaortic nodal area. In phase III cervical mass was boosted to a total dose of 65 Gy (Figure-1). She received weekly Cisplatin at 40 mg/m<sup>2</sup> for 6 weeks. The 2/3rd of left kidney received 32 Gy and 8 % of right normally positioned kidney received <12 Gy. Tolerance remained well throughout treatment.

### Results

Pelvic examination was done fortnightly to see the interim response of disease. Eight weeks after completion of

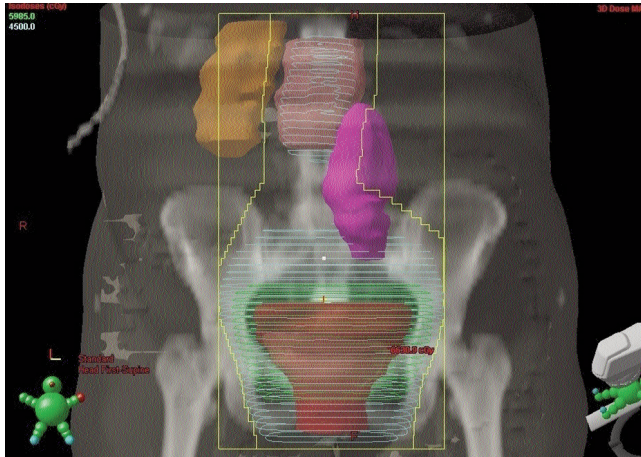


Figure: Location of left pelvic kidney (pink) and Isodose lines of radiation doses.

chemoradiation, PET/CT scan revealed complete resolution of the paraaortic lymph nodes and > 80% reduction in the size of primary cervical mass. She received adjuvant three cycles of Carboplatin and Paclitaxel chemotherapy. At 24 month follow up, she is free of recurrence and her irradiated kidney continues to show good excretion of contrast on PET/CT scan. She will continue to have pelvic examinations regularly at two monthly intervals.

### Discussion

The simultaneous occurrence of locally advanced cervical cancer and an ectopic pelvic kidney is an uncommon condition that presents a challenge to oncologists. The management requires evaluation of the renal function before therapy. In this case both kidneys were normally functioning. However, as she received radical chemoradiotherapy, the left ectopic kidney was sacrificed.

There is paucity of guidelines of treating such cases,

three reported cases of pelvic kidney and advanced cervical cancer, two patients with renal transplant and a case of rectal cancer with pelvic kidney could be found in literature.<sup>2,3</sup> But none of the cases needed extended field pelvic and para aortic field radiation therapy.

Lataifah reported a case of left pelvic kidney with FIGO IIB cervical cancer which was successfully treated with pelvic chemoradiotherapy and brachytherapy.<sup>2</sup> Ripley reported the treatment of locally advanced cervical cancer in a patient with renal transplant at M D Anderson Cancer center, who subsequently developed local recurrence after 22 months.<sup>3</sup> This case being presented had para aortic lymph adenopathy and posed a unique challenge for treatment, as we had to treat the left pelvic kidney while keeping the dose to a minimal for the right normally positioned kidney and at the same time delivering tumoricidal dose to the para-aortic region.

Prognosis of this stage of disease is reported to be reasonably good, being two year disease free survival 46% and overall survival 60% in one study<sup>4</sup> and three year disease free survival 63% in another study.<sup>5</sup>

### References

1. Rose PG, Bundy BN, Watkins EB, Thigpen JT, Deppe G, Maiman MA, et al. Concurrent cisplatin-based radiotherapy and chemotherapy for locally advanced cervical cancer. *N Engl J Med* 1999; 340: 1144-53.
2. Lataifah I, Amarin Z, Jaradat I. Stage IIB carcinoma of the cervix that is associated with pelvic kidney: A therapeutic dilemma. *Am J Obstet Gynecol* 2007; 197: e8-10.
3. Ripley D, Levenback C, Eifel P, Lewis RM. Adenocarcinoma of the cervix in a renal transplant patient. *Gynecol Oncol* 1995; 59: 151-5.
4. Small W, Jr., Winter K, Levenback C, Iyer R, Hymes SR, Jhingran A, et al. Extended-field irradiation and intracavitary brachytherapy combined with cisplatin and amifostine for cervical cancer with positive para-aortic or high common iliac lymph nodes: results of arm II of Radiation Therapy Oncology Group (RTOG) 0116. *Int J Gynecol Cancer* 2011; 21: 1266-75.
5. Grigsby PW, Heydon K, Mutch DG, Kim RY, Eifel P. Long-term follow-up of RTOG 92-10: cervical cancer with positive para-aortic lymph nodes. *Int J Radiat Oncol Biol Phys* 2001; 51: 982-7.