



THE AGA KHAN UNIVERSITY

eCommons@AKU

General Surgery, East Africa

Medical College, East Africa

January 2007

Reverse sural island flap in coverage of defects lower third of leg: a series of nine cases

S. O. Khainga
University of Nairobi

B. Githae
University of Nairobi

V. M. Mutiso
University of Nairobi

R. Wasike
Aga Khan University

Follow this and additional works at: http://ecommons.aku.edu/eastafrica_fhs_mc_gen_surg



Part of the [Surgery Commons](#)

Recommended Citation

Khainga, S. O., Githae, B., Mutiso, V. M., Wasike, R. (2007). Reverse sural island flap in coverage of defects lower third of leg: a series of nine cases. *East African Medical Journal*, 84(1), 38-43.

Available at: http://ecommons.aku.edu/eastafrica_fhs_mc_gen_surg/11

East African Medical Journal Vol. 84 No. 1 January 2007

REVERSE SURAL ISLAND FLAP IN COVERAGE OF DEFECTS LOWER THIRD OF LEG: A SERIES OF NINE CASES
S.O. Khainga, MBChB, MMed (Surg), FPRS (SA), B. Githae, MBChB, MMed (Surg), V.M. Mutiso, MBChB, MMed (Surg),
Department of Surgery, College of Health Sciences, University of Nairobi, P.O. Box 19676-00202, Nairobi, Kenya and
R. Wasike, MBChB, MMed (Surg), Aga Khan University Teaching Hospital, P.O. Box 30270-00100, Nairobi, Kenya

Request for reprints to: Dr. S.O. Khainga, Department of Surgery, College of Health Sciences, University of Nairobi,
P.O. Box 19676-00202, Nairobi, Kenya

REVERSE SURAL ISLAND FLAP IN COVERAGE OF DEFECTS LOWER THIRD OF LEG: A SERIES OF NINE CASES

S.O. KHAINGA, B. GITHAЕ, V.M. MUTISO and R. WASIKE

SUMMARY

The distally based sural island flap was first described by Masquelet, *et al*, in 1992. It is a skin island flap supplied by the vascular axis of the sural nerve. The aim of this paper is to demonstrate that it can be applied in coverage of difficult wound in the lower third of the leg. We treated nine patients with nine distally based sural island flaps. All the flaps survived, most of the flaps had venous congestion. The largest flap was 10 x 8 cm and Doppler was used in only one flap. This technique is easy and quick to execute without sacrificing major arteries.

INTRODUCTION

Soft tissue defects of the lower third of the leg presents a challenging problem because of the tightness and poor circulation of the skin. Various forms of coverage including muscle flaps (1), fascial flaps (2,3), septo cutaneous flaps (4-6), axial flaps (7-9) and free flaps (10), each have their specific indications and inherent disadvantages.

Reverse sural island flap is one of the recently described neurocutaneous flaps. We have successfully elevated eight reverse sural island flaps based on the vascular axis of the sural nerve, to cover defects in the leg resulting from varied causes. This paper presents our experience as well as the reliability of surgery using this flap.

MATERIALS AND METHODS

Case	Age	Sex	Aetiology	Site of Defect	Size of flap(cm)	Complications
1	Adult	M	Motor vehicle accident	Dorsum of foot	10 x 6	Nil
2	Adult	M	Diabetic ulcer	Lateral malleolar	7 x 5	Nil
3	43	M	Motor vehicle accident	Calcaneum	7 x 5	Nil
4	Adult	M	Motor vehicle accident	Dorso-plantar foot + calcaneum	10 x 8 + STSG	Nil
5	37	M	Motor vehicle accident	Lateral aspect of leg	8 x 6	Necrosis edge of flaps
6	65	M	Varicose ulcer	Lateral aspect of leg	9 x 6	Ulceration of edges
7	38	F	Varicose ulcer	Lateral aspect of leg	8 x 5	Debulking recommended
8	43	M	Motor vehicle accident	Medial aspect of leg	7 x 5	Nil
9	66	M	Motor bike accident	Right foot tendoachilles and calcaneum	8 x 6	Necrosis distal edge of flap

OPERATIVE PROCEDURE

Figure 1

Diagram of the sural nerve (N) and the superficial sural artery (A) showing the relation of the nerve to the short saphenous vein (V). The nerve is lateral to the vein. In the circle the magnification is shown.

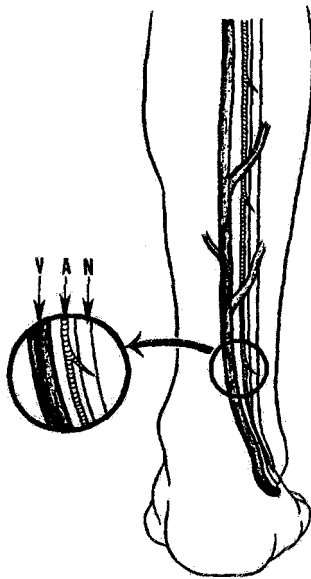


Figure 2

The design of the distally based superficial sural artery flap on the posterior aspect of the leg. The skin island can be raised anywhere in the lower two-thirds of the leg. The pivot point of the pedicle must be at least 5 cm above the lateral malleolus to keep the anastomoses with the peroneal artery

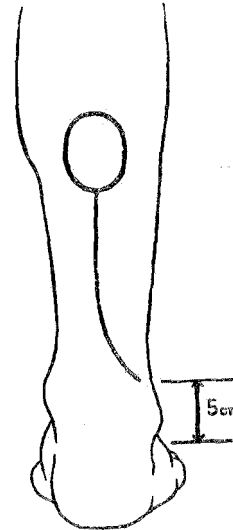


Figure 3

The skin island is raised with the deep fascia. The subcutaneous fascial pedicle is elevated, keeping a width of 2 cm to include the sural nerve (N) and the short saphenous vein (V).

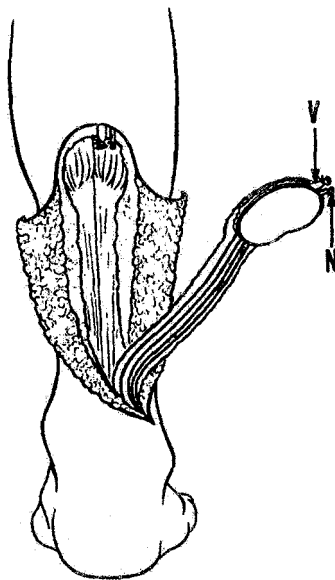
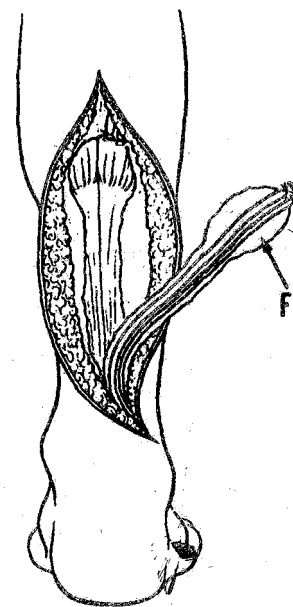


Figure 4

The fascial flap supplied by the superficial sural vessels. The deep fascia (F) without a skin island can be elevated safely



The flap is supplied by the superficial sural artery that accompanies the sural nerve (Figure 1). The artery gives off small branches to the skin in the lower two thirds of the leg. In the lower part of the tibio-fibular space, the superficial sural artery anastomoses with the septo cutaneous branches from the peroneal artery.

The flap can be raised anywhere in the lower two thirds of the leg, provided that the centre of the flap is along the centre of line of the posterior aspect of the leg. With the patient in the prone position, a skin island is marked according to a previously prepared pattern of the recipient defect. The pivot point of the pedicle must be at least 5cm above the lateral malleolus to allow anastomosis with the peroneal artery (Figure 2).

Skin incision is begun along the line in which the fascial pedicle will be taken. The sub-dermal layer is dissected to expose the sural nerve with the accompanying superficial sural vessel and the short saphenous vein. The subcutaneous fascial pedicle is elevated with a width of 2-5 cm to include the nerve and these vessels at the proximal margin of the flap; the vein is ligated and severed together with the nerve and accompanying vessels. The skin island is carefully elevated with deep fascia. The fascia is transfixed onto the skin at intervals to ensure that it does not get damaged or left out. If a thin flap is preferred, the deep fascia without the skin island can be elevated and the fascial flap is covered with a split thickness skin graft (Figure 4).

The donor site defect is covered with a split thickness skin graft. A smaller donor site defect can be closed directly.

RESULTS

All the nine flaps survived though most of them showed venous congestion, which cleared up in the two weeks. In case 5, where the flap covered an exposed plate, a blister developed on the antero-inferior edge of the flap, which was inadvertently punctured and excised by nurses. This exposed the underlying dermis which then necrosed and had to be excised. The resultant wound healed by secondary intention. In case 4, the flap was used to cover the exposed calcaneum, while the rest of the wound was covered by a split thickness skin graft. The rest of the defects were adequately covered by the flaps.

CASE REPORTS

Case 1: Figures 5, 6, 7

An adult male sustained a degloving injury on the left antero-lateral aspect of the dorsum of the foot following a motor vehicle accident. After a series of debridements, the wound was covered by a 10 x 6 cm distally base reverse island flap. The donor site was covered by a slit thickness skin graft. The post operative course was uneventful.

Figure 5

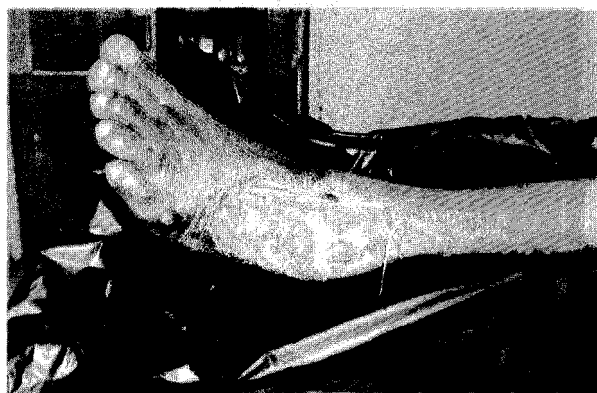

Figure 6

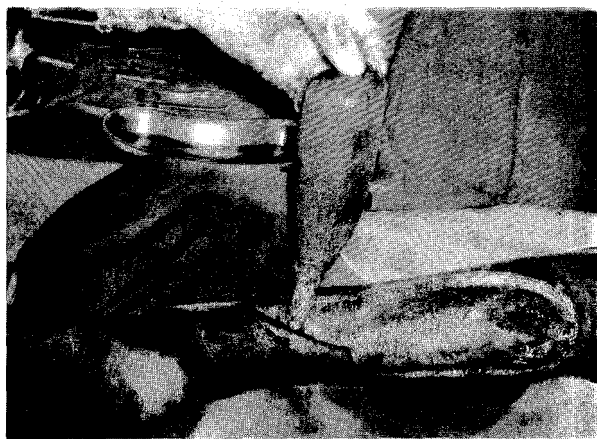
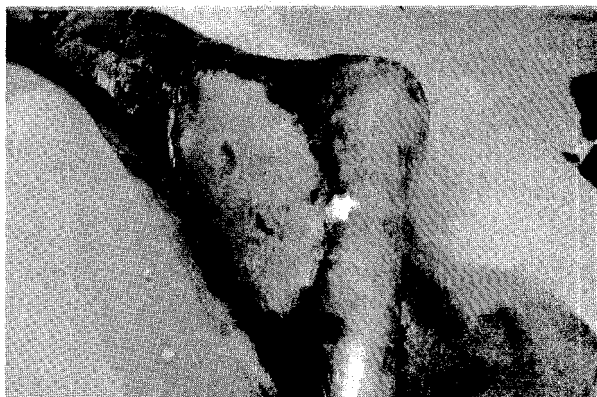

Figure 7



Case 2

A male adult who was diabetic developed a chronic left lateral malleolar ulcer, approximately 5 cm in diameter. The ulcer was covered by a 7 x 5 cm distally based reverse sural island flap. The donor site was covered with a split thickness skin graft. His post operative recovery was uneventful.

Case 3

A 43-year old man was involved in a motor vehicle accident and sustained a degloving injury with exposed calcaneum of the right foot. After debridement and a series of dressings of the wound, a 7 x 5 cm distally based reverse sural flap was used to completely cover the wound and exposed calcaneum. The donor site was closed with a slit thickness skin graft. The flap healed uneventfully.

Case 4

An adult male was involved in a motor vehicle accident and sustained a huge degloving injury of the right foot, mainly involving the plantar aspect. Following a series of debridement procedures, the wound was covered by a 10 x 8 cm reverse distally based sural island flap. The flap was used to cover the exposed calcaneum and part of the wound. The rest of the wound coverage was with a split thickness skin graft. The donor site was covered with a split thickness skin graft. The post operative period was uneventful.

Case 5

A 37 year-old male was involved in a motor vehicle accident and sustained multiple injuries that included a Weber C fracture of the right tibia-fibula. The fracture was plated nine days after the accident and a dynacast applied. After three weeks the patient developed wound sepsis with wound dehiscence that exposed the plate and screws.

The fourth week after plating of the fracture, a reverse sural island flap of 8 x 6 cm was used to cover the wound and exposed plate. The donor site was covered with a skin graft. A week post operatively, a blister developed on the antero-inferior aspect of the flap. The blister was broken by ward nurse and the exposed underlying dermis necrosed. It was excised and the edge of the wound allowed to heal by granulation.

Case 6

A 65 year-old man with a chronic varicose right leg ulcer on lateral aspect. A sural island flap of 9 x 6 cm was used to close the defect after excision of the ulcer. Ulceration at the edge of flap healed by second intention.

Case 7

A 38 year-old female with a chronic right leg ulcer on lateral aspect was closed with a 8 x 5 cm sural island flap. The flap was very thick due to fat. Recommended for debulking.

Case 8

A 43-year-old man was involved in a motor vehicle accident and sustained a compound fracture of the right tibia-fibula with loss of a significant amount of tibial bone. Using the doppler to confirm presence of perforators following earlier surgery of the leg, a 7 x 5 cm reverse sural island flap was elevated to cover the wound and an iliac bone graft inserted to fill the tibial defect. The donor site was covered by a split thickness skin graft. Three weeks in the post-operative period, a discharge from the distal end of the flap grew *Staphylococcus aureus*, which was sensitive to Augmentin. The flap, subsequently healed without further sequelae.

Case 9

A 66-year-old male whose right foot was trapped in the rear wheel of a motor bike and he sustained cut tendoachilles with degloving injury to the right calcaneum.

Wound was debrided and tendoachilles repaired and covered with skin flap which broke exposing calcaneum and distal end of tendoachilles. Further debridement was done and a 8 x 6 cm reverse island sural flap inset into defect. There was slight necrosis to distal edge of flap, which granulated and healed by second intention.

DISCUSSION

From the time Taylor and Ham (12) introduced the concept of vascularised nerve grafts in 1976, the blood supply pattern of sensitive superficial nerves has been studied in order to get a donor vascularised nerve graft (13-16). Masquelet *et al* (11) gave attention to the blood supply of the skin by

arteries accompanying these nerves. In 1992, using coloured latex injection studies, he reported that these arteries gave off cutaneous branches in the suprafascial course and described the concept of a neuro skin island flap. They also demonstrated the possibility of raising a distally based island flap based on the vascular axis of the sural nerve.

We elevated nine flaps successfully, to cover wounds of varied aetiologies in the lower third of the leg and demonstrated the reliability of this flap as an alternative to other available options.

The arterial blood supply to the flap comes from the superficial sural artery. According to Masquelet *et al* (11), the artery descends to the ankle in 65% of cases and, in the remaining 35%, it forms an interlacing suprafascial network. However, in both cases, the superficial sural artery anastomoses with the septo cutaneous artery issuing from the peroneal artery through the suprafascial network. Therefore, the distally based superficial sural artery is vascularised by the peroneal artery and the pedicle of the flap must include the deep fascia thus preserving the anastomosis of the suprafascial plane. In all our procedures, we carefully elevated the flaps with the deep fascia. This then explains the reason why we had a 100% success rate.

The venous drainage in the reverse flow forearm flap (17) and reverse flow peroneal flap (18) has been studied. In these flaps, there are many bypasses and communicating channels among the venae comitantes around the arteries and therefore venous drainage passes through these bypasses and channels.

The venous drainage of the distally based superficial sural artery flap has not been demonstrated. Maybe it passes through the suprafascial venous network of superficial sural vein, short saphenous vein and septo cutaneous veins of peroneal vein.

The largest flap we raised was about 10 x 8 cm in case 4 and we noted that there was more significant oedema in this flap than the rest of the flaps. We also noted that breaking of a blister, thus exposing the underlying dermis resulted in necrosis of the edge of flap. We, therefore, recommend if puncturing of the blister should be done, the skin should not be excised to expose dermis.

We noted the following advantages of this procedure:

(i) Easy and quick surgery once the experience is gained.

(ii) The flap can be designed easily without use of a doppler. In case 8, we found use of a doppler significant due to previous surgeries in the area of peroneal artery perforators.

(iii) There is no sacrifice of major arteries and therefore this surgery can be performed on a traumatic leg that has damaged major arteries.

The main disadvantage in the distally based sural island flap is the sacrifice of the sural nerve resulting in hypoesthesia and numbness in the lateral aspect of the foot (19). This was a complication recorded in all the nine patients in this series. In an obese patient the flap can be bulky. In case 7, the female patient with varicose ulcer, the flap was so bulky that the debulking was recommended but the patient declined. In such cases, the fascial flap and skin graft would be preferred.

All the donor sites were closed using a skin graft. We noted that the initial crater defect after the skin grafting filled up with underneath granulation and that resultant deformity was insignificant from three months onwards.

In summary, the distally based reverse sural island flap: has a reliable blood supply; elevation is quick and easy, and major arteries are not sacrificed and thus we recommend it as an option in appropriate circumstances for closure of wounds of lower third of the leg.

REFERENCES

1. Fayman M.S., Orak F., Hugo B. and Benson S.D. The distally based split soleus muscle flap. *Brit. J. Plastic Surg.* 1987; 40: 20.
2. Donsk P.K. and Fodgestam I. Distally based fasciocutaneous flap from the sural region: A preliminary report. *Scand. J. Plast. Reconstr. Surg.* 1983; 17: 191.
3. Amarante J., Costa H. and Soares R. A new distally based fasciocutaneous flap of the leg. *Brit. J. Plast. Surg.* 1986; 39: 338.
4. Yoshimura M., Shimada T., Imura S., Shimamura K. and Yamauchi S. Peroneal island flap for skin defects in the lower extremity. *J. Bone Joint Surg.* 1985; 67A: 935.
5. Tonii S., Namiki Y. and Hayashi Y. Anterolateral leg island flap. *Brit. J. Plast. Surg.* 1987; 40: 236.
6. Wee J.T.K. Reconstruction of the lower leg and foot with the reversed-pedicled anterior tibial flap: Preliminary report of a new fasciocutaneous flap. *Brit. J. Plast. Surg.* 1986; 39: 327.

7. Grabb W.C. and Argenta L.C. The lateral calcaneal artery skin flap. *Plast. Reconst. Surg.* 1981; **68**: 723.
8. Yanai A., Park S., Iwao T. and Nakamura N. Reconstruction of a skin defect of the posterior heel by a lateral calcaneal flap. *Plast. Reconst. Surg.* 1985; **75**: 642.
9. Masquelet A.C., Bevenidge J., Romana C. and Gerber C. The lateral supramalleolar flap. *Plast. Reconst. Surg.* 1988; **81**: 74.
10. Serafinm D., Georgiade N.G. and Smith D.H. Comparison of free flaps with pedicled flaps for coverage of defects of the leg or foot. *Plast. Reconst. Surg.* 1977; **59**: 492.
11. Masquelet A.C., Romana M.C. and Wolf G. Skin island flaps supplied by the vascular axis of the sensitive superficial nerves: Anatomic study and clinical experience in the leg. *Plast. Reconst. Surg.* 1992; **89**: 1115.
12. Taylor G.I. and Ham F.J. The free vascularised nerve graft. *Plast. Reconst. Surg.* 1976; **57**: 413.
13. Fachinelli A., Masquelet A., Restrepo J. and Gilbert A. The vascularised sural nerve: Anatomy and surgical approach. *Int. J. Microsurg.* 1981; **3**: 57.
14. Doi K., Kuwata N., Kawakami F., et al. The free vascularised sural nerve graft. *Microsurgery.* 1984; **5**: 175.
15. Breidenbach W.C. and Terzis J.K. The anatomy of free vascularised nerve grafts. *Clin. Plast. Surg.* 1984; **11**: 65.
16. Breidenbach W.C. and Terzis J.K. The blood supply of vascularised nerve grafts. *J. Reconst. Microsurg.* 1986; **3**: 43.
17. Lin S.D., Lai C.S. and Chiu C.C. Venous drainage in the reverse forearm flap. *Plast. Reconst. Surg.* 1984; **74**: 508.
18. Torii S., Namiki Y. and Mori R. Reverse-flow island flap: Clinical report and venous drainage. *Plast. Reconst. Surg.* 1987; **79**: 600.
19. Morimasa H., Shulei T., Hisakazu Z. and Shigeru E. The distally based superficial sural artery flap. *Plast. Reconst. Surg.* 1994; **93**: 1012.