



THE AGA KHAN UNIVERSITY

eCommons@AKU

Department of Radiology

Medical College, Pakistan

March 2010

# Magnetic resonance imaging findings in patients with schizophrenia

Waseem Akhtar  
*Aga Khan University*

Haider A Naqvi  
*Aga Khan University*

Sajjad Hussain  
*Aga Khan University*

Arif Ali  
*Aga Khan University*

Nadeem Ahmad  
*Aga Khan University*

Follow this and additional works at: [http://ecommons.aku.edu/pakistan\\_fhs\\_mc\\_radiol](http://ecommons.aku.edu/pakistan_fhs_mc_radiol)

 Part of the [Radiology Commons](#)

## Recommended Citation

Akhtar, W., Naqvi, H., Hussain, S., Ali, A., Ahmad, N. (2010). Magnetic resonance imaging findings in patients with schizophrenia. *Journal of the College of Physicians and Surgeons Pakistan*, 20(3), 167-70.  
**Available at:** [http://ecommons.aku.edu/pakistan\\_fhs\\_mc\\_radiol/7](http://ecommons.aku.edu/pakistan_fhs_mc_radiol/7)

# Magnetic Resonance Imaging Findings in Patients with Schizophrenia

Waseem Akhtar<sup>1</sup>, Haider A. Naqvi<sup>2</sup>, Sajjad Hussain<sup>2</sup>, Arif Ali<sup>3</sup> and Nadeem Ahmad<sup>1</sup>

## ABSTRACT

**Objective:** To determine structural abnormalities in the brain of patients with schizophrenia by Magnetic Resonance Imaging (MRI).

**Study Design:** Comparative study.

**Place and Duration of Study:** The Departments of Radiology and Psychiatry, the Aga Khan University Hospital, Karachi, from January 2007 to June 2008.

**Methodology:** Thirty-three cases of schizophrenia (n=33) and thirty-three age-matched controls, (n=33) were enrolled for this study. Screening Magnetic Resonance Imaging (MRI) of brain was done in order to see structural changes in brain matter. Findings were compared among groups using chi-square and Fisher's exact test with significance at  $p < 0.05$ .

**Results:** Among the total of 66 (n=66) MRI films studied for brain abnormalities, brain atrophy, presence of septum pellucidum and enlarged Virchow-Robins spaces were significantly associated with schizophrenia ( $p < 0.001$ ). There was no significant difference between cases and controls for ventricular dilatation ( $p=0.5$ ). Sinusitis was mostly associated with controls and well correlated with their symptoms ( $p < 0.001$ ).

**Conclusion:** Brain atrophy was the most commonly seen brain change in the studied sample of patients with schizophrenia. MRI brain can be used to identify structural abnormalities in patients with schizophrenia.

**Key words:** Schizophrenia. MRI. Brain. Atrophy. Structural changes. Psychosis.

## INTRODUCTION

Schizophrenia is a psychiatric disorder characterized by delusions, perceptual abnormalities and deterioration of cognitive functions resulting from diffuse gray matter abnormalities. The disease did not gain medical importance until the 19th century in the fields of both psychiatry and neurology. At the end of the 20th century, research has shown monumental discoveries regarding the neuropathology of the disease; reduced symmetry of the brain, changes in cerebral ventricles, limbic system, prefrontal cortex, thalamus, basal ganglia and cerebellum are some of the findings observed in patients with schizophrenia.<sup>1</sup>

The lifetime risk of developing schizophrenia is between 0.7-0.9% per 1000 individuals. The point prevalence of schizophrenia in European countries is probably between 0.25-0.53% per 1000 individuals. Collaborative studies of WHO have shown that prevalence of schizophrenia, when assessed in comparable ways, is similar in different countries. Prevalence estimate of schizophrenia from studies in low-income countries

varies from as low as 0.8% reported from rural China to as high as 3.8% in Sri Lanka and 5.9% in Calcutta, India.<sup>2</sup>

A longitudinal study of brain morphology in patients with first-episode schizophrenia established the findings of ventricular enlargement and anterior hippocampal volume reduction.<sup>3</sup> Another longitudinal study, conducted over 3 years from initial evaluation to follow-up, concluded that there is an accelerated enlargement in cortical sulci in the early phase of the disease.<sup>4</sup> They also showed that patients with poorer outcome had a greater enlargement of the lateral ventricles.<sup>4</sup>

Besides functional imaging for the assessment of neurological pathways in schizophrenia, many studies have proven that among the structural brain abnormalities, most consistent findings are enlarged lateral ventricles, reduced medial temporal and prefrontal lobe volumes.<sup>5,6</sup> These can be assessed very well with MRI which is the most commonly used neuroimaging modality where available.

There are studies on structural and functional brain changes associated with schizophrenia which helps in diagnosis and prognosis of the disease process.<sup>7,8</sup> However, no such data is available regarding the structural brain abnormalities of patients with schizophrenia from developing countries especially South East Asia. Therefore, this study was designed to determine the structural brain abnormalities in patients with schizophrenia.

*Department of Radiology<sup>1</sup>/Psychiatry<sup>2</sup>/Community Health Science<sup>3</sup>, the Aga Khan University Hospital, Karachi.*

**Correspondence:** Dr. Waseem Akhtar, Department of Radiology The Aga Khan University Hospital, Karachi-75800.

E-mail: waseem.mirza@aku.edu

Received November 10, 2008; accepted October 20, 2009.

## METHODOLOGY

This study was carried out collaboratively in the Department of Radiology and Psychiatry, the Aga Khan University Hospital, Karachi, from July 2007 to June 2008.

Thirty three patients with the ICD-10 diagnosis of schizophrenia consented to be enrolled as cases for this study. Patients with schizoaffective disorder or co-morbid substance abuse, mental retardation and organic mental disorders were excluded from the study. We enrolled an equal number of controls. Controls were selected from the list of patients' referred to department of radiology for MRI brain with non-specific symptoms; they had no primary psychiatric or neurological disorder. Controls were matched for the age in order to compare the difference in the structural changes and abnormalities. Purposive sampling was done for induction of cases and controls to fulfill the objectives of the study.

The study was conducted in compliance to ethical principles for medical research involving human subjects' of Helsinki Declaration and formal approval was taken from Ethical Review Committee of the Hospital. Written informed consent was obtained before MRI procedure in all participants.

All patients were seen by consultant psychiatrist and diagnosis was made according to World Health Organization (WHO) based international classification of disease diagnostic criteria (ICD-10). In order to measure the onset and course of psychosis 'Interview for Retrospective Assessment of Age at Onset in Schizophrenia' was applied (IROAS).<sup>9</sup> As part of the protocol, all cases were given the option of free-of-cost MRI scan through research grant.

MRI's were obtained on a Siemens 1.5-T scanner. Volumes of interest were acquired by using T2-weighted scans with 1.2 mm contiguous axial slices (TE=98 msec, TR=4000 msec, flip angle=30°, field of view=256256 mm) and single midline sagittal image was also obtained for better delineation of corpus-callosum. Interpretation was done on dedicated reporting console and on hard copies. Structural brain abnormalities including atrophy, ventricular dilatation, presence of septum pellicudum, corpus-callosum abnormalities, prominent Virchow Robin (VR) spaces and additional findings were evaluated subjectively.<sup>10</sup> Two consultant radiologists having experience of neuroimaging made the final report. Patients having metallic implants, pace-makers or contraindication to MRI were excluded from the study.

Data was entered and analyzed in SPSS version 16. Considering the brain abnormalities as an outcome of schizophrenia the cases and controls were compared by applying chi-square and Fisher exact test at the statistical significance of 95% confidence level; p-value of less than 0.05 was considered as significant.

## RESULTS

There were 66 subjects, 33 were cases (16 men and 17 women) while 33 were age - matched controls (17 men and 16 women). Mean age of male patients was  $34 \pm 10.4$  years, while for female patients it was  $31 \pm 10$  years. All patients with schizophrenia were taking psychotropic medications and mean duration of treatment was  $10 \pm 9.7$  months.

Most pronounced psychiatric symptoms identified on IROAS were depressed mood (66%), worries (65%), tension (63%), auditory hallucinations (61%), delusion of persecution (43%), irritability (43%), sleeplessness (43%) withdrawal/mistrust (54%), sleeplessness (43%) and loss of self-confidence (53%). Positive symptoms of psychosis were present in 57% subjects while negative symptoms were present in 30% subjects.

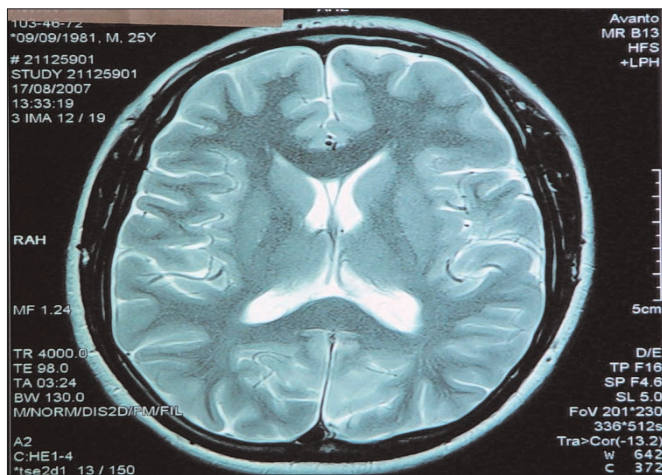
There was no significant gender difference between cases and controls (Table I). Brain atrophy was the most commonly seen structural abnormality in schizophrenia ( $p=0.001$ ), seen in 13 (39%) cases and conspicuously absent in controls. Presence of septum pellicudum was noted in 10 (30%) cases of schizophrenia and not seen in any control. Prominent Virchow Robin spaces (VR) were seen in 10 (30%) cases with schizophrenia and not seen in any control.

**Table I:** Comparison of characteristic between cases and controls.

variables	Cases		Controls		Chi-square	p-value
	n	%	n	%		
Gender					0.061	NS
Male	16	48.5	17	51.5		
Female	17	51.5	16	48.5		
Brain atrophy					16.189	< 0.001
No	20	60.6	33	100		
Yes	13	39.4	0	0		
Ventricular dilatation					-	NS*
Normal	29	87.9	31	93.9		
Present	4	12.1	2	6.1		
Septum pellicudum					11.78	0.001
Absent	23	69.7	33	100		
Present	10	30.3	0	0		
Sinusitis					8.73	0.003
Absent	23	69.7	11	33.3		
Present	10	30.3	22	66.7		
VR spaces					-	< 0.001*
Non prominent	23	69.7	33	100		
Prominent	10	30.3	0	0		

NS = not statistically significant; \*Fisher's exact test.

Ventricular dilatation was identified in 4 (12%) of cases and 2 (6%) controls. Brain atrophy, presence of septum pellicudum and prominent VR spaces were significantly associated with schizophrenia as compared to controls ( $p < 0.05$ ). Figure 1 depicts prominent septum pellicudum in a 25 years old male patient with schizophrenia. Sinusitis was noted in 22 (67%) controls subjects. This corresponded with their non-specific symptom of headache. This corpus callosum was normal in all patients with history of schizophrenia.



**Figure 1:** T2W axial Image showing prominent cavum septum pellucidum in 25 years old male patient of schizophrenia.

## DISCUSSION

This is the first study from Pakistan reporting structural brain changes in patients with schizophrenia. In this study, brain atrophy was identified in 39% of patients which is consistent with an earlier study by Nelson and Wright *et al.*<sup>11,12</sup> In the present study, this atrophy was found to be mostly diffuse and not limited to hippocampus or parahippocampal area alone. Cavum septum pellucidum was noted in 30% of cases. This frequency is lower than the earlier reports in the literature. Presence of cavum septum pellucidum has been reported in 92% studies on structural brain abnormalities on patients with schizophrenia.<sup>13,14</sup> VR spaces were prominent in 30% of cases, which could very well be a non-specific finding, associated with neuroleptics use, since most of these patients were on medications.<sup>15</sup> Ventricular dilatation was seen in 12% of patients with schizophrenia and it was not significantly different from controls. This finding is not consistent with Shenton *et al.* who reported it in 80% of cases of schizophrenia.<sup>16</sup> Many studies have shown corpus callosum related abnormalities associated with schizophrenia,<sup>10-12,17</sup> but in this study sample corpus callosum was normal in all cases of schizophrenia. This finding could be an artifact of small sample size as well as absence of pediatric age patients in this sample.

In this sample, the positive and negative symptoms of schizophrenia were assessed using IROAS, any specific pattern of brain changes could not be identified with symptoms-presentation. IROAS was originally developed within the framework of the ABC (mnemonic for age, beginning and course) schizophrenia study (Häfner *et al.* 1998) for systematic research on the onset of schizophrenia.<sup>9</sup> It is one of the most robust, widely used instruments in the schizophrenia-research. IROAS examines the social course, course of the symptoms, disability and treatment from the first signs or indicators of illness until the time of interview. There is some

evidence that regional neuropathology related to certain symptoms of schizophrenia may be sexually dimorphic. Cowell *et al.* determined for schizophrenic women that greater frontal lobe volume was associated with more severe disorganization and suspicious-hostility; in schizophrenic men, smaller frontal lobe volume was associated with more severe disorganization and did not correlate with suspicious hostility.<sup>18</sup>

In a quantitative meta-analysis of 40 volumetric studies, Lawrinc *et al.* concluded that a number of differences in brain structure were present between schizophrenic and normal groups but there were few significant differences between male and female schizophrenics. Their analysis revealed that, compared to controls, schizophrenic patients had smaller whole brain, temporal lobe and amygdala/hippocampal complex volumes, more CSF, larger ventricles and reduced gray matter volumes.<sup>19</sup>

Traditionally, schizophrenia is divided into five sub-types based on the phenomenological symptoms. This categorization does have its utility in being able to predict treatment and prognosis. However, the major stumbling block for researchers may be the definition of disease phenotype. Though the classical clinical picture of schizophrenia based on delusions and hallucinations can be vivid, one contributing factor to the failure to identify a susceptible gene and uncovering the etiology of schizophrenia, may be that classical symptoms-based disease phenotype is too narrowly defined and too heterogeneous and, classical disease phenotype are not stable over time. This problem led many researchers to propose employment of heritable neurobiological traits correlated with the disease as the phenotype. Such intermediate or endo-phenotypes, sometimes referred as biomarkers, are proposed to have simplistic utility, improved operational definitions, and for some, more objective diagnosis.<sup>20</sup>

Although this proposition is still in its infancy, an emerging consensus among investigators is that the most useful candidate biological marker for schizophrenia are those that are more frequent in patients than control population; that are stable over time and insensitive to age, gender, and medication status; that are more frequent in non-schizophrenic members of multiply affected families than control populations. Possible candidates for biological markers include abnormalities on structural neuro-imaging and cognition (impairment in attention).<sup>21</sup> One of the applications of this study is that it serves to establish the presence of structural brain changes as an endo-phenotype in a sample of patients with schizophrenia. This could pave the way for further research on the etiology of this disorder.

There were several limitations to this study. The relatively small study sample, subjective assessment of finding and screening MRI might have limited the ability to find the



spectrum of ventricular dilation and brain atrophy across the full range of patients with schizophrenia. Additionally, there was no assessment of inter-observer agreement amongst the radiologist for interpretation of MRI.

Patients were enrolled with diagnosis of schizophrenia already being treated. Since their previous imaging was unavailable for comparison, causal association of schizophrenia with observed brain changes cannot be assessed, some of the observed findings may be an effect of the neuroleptic medicines. Understanding the complexity of schizophrenia regarding the diagnosis and treatment is studied in a detailed manner by functional and anatomical imaging, mainly by MRI. Larger longitudinal studies with functional imaging are required in order to establish the association between schizophrenia and structural abnormalities of brain.

### CONCLUSION

Brain atrophy and presence of septum pellucidum were commonly associated structural brain changes in patients with schizophrenia. MRI is a useful and accurate modality in identifying these structural brain changes and can be used in the diagnosis and prognosis of patients with schizophrenia.

**Acknowledgement:** Part of this project was funded by Seed Money Research Grant of the Aga Khan University Research Council. This study was a part of larger research project, aimed to explore the pathways to care and help seeking behaviour in patients with schizophrenia.

### REFERENCES

1. Sadock BJ, Sadock BA. Kaplan and Sadocks synopsis of psychiatry-behaviour science/clinical psychiatry. 10th ed. New York: Lippincott Williams & Wilkins; 2007.
2. Jablensky A, Sartorius N, Ernberg G, Anker M, Korten A, Cooper JE, et al. Schizophrenia: manifestation, incidence and course in different cultures. A World Health Organization ten-country study. *Psychol Med Monogr Suppl* 1992; **20**:1-97.
3. Liberman J, Chakos M, Wu H, Alvir J, Hoffman E, Robinson D, et al. Longitudinal study of brain morphology in first episode schizophrenia. *Biol Psychiatry* 2001; **49**:487-99.
4. Ho BC, Andreasen NC, Nopoulos P, Arndt S, Magnotta V, Flaum M. Progressive structural brain abnormalities and their relationship to clinical outcome: a longitudinal magnetic resonance imaging study early in schizophrenia. *Arch Gen Psychiatry* 2003; **60**:585-94.
5. Staal WG, Hulshoff Pol HE, Schnack HG, Hoogendoorn MLC, Jellema K. Structural brain abnormalities in patients with schizophrenia and their healthy siblings. *Am J Psychiatry* 2000; **157**:416-4212.

6. Weinberger DR, DeLisi LE, Neophytides AN, Wyatt RJ. Familial aspects of CT scan abnormalities in chronic schizophrenic patients. *Psychiatry Res* 1981; **4**:65-71.
7. Cannon TD, van Erp TG, Huttunen M, Lonnqvist J, Salonen O, Valanne L, et al. Regional gray matter, white matter, and cerebrospinal fluid distributions in schizophrenic patients, their siblings, and controls. *Arch Gen Psychiatry* 1998; **55**:108-91.
8. Dauphinais ID, DeLisi LE, Crow TJ, Alexandropoulos K, Colter N, Tuma I, et al. Reduction in temporal lobe size in siblings with schizophrenia: a magnetic resonance imaging study. *Psychiatry Res* 1990; **35**:137-47.
9. Hafner H, Maurer K, Loffler W, An der Heiden W, Munk-Jorgensen P, Hambrecht M, et al. The ABC schizophrenia study: a preliminary overview of the results. *Soc Psychiatry Epidemiol* 1998; **33**:380-6.
10. Liddle PF, Pantelis C. Brain imaging in schizophrenia. In: Hirsch SR, Weinberger DR, editors. Schizophrenia. 2nd ed. Oxford: Blackwell Science; 2003. p. 403-17.
11. Nelson MD, Saykin AJ, Flashman LA, Riordan HJ. Hippocampal volume reduction in schizophrenia as assessed by magnetic resonance imaging: a meta-analytic study. *Arch Gen Psychiatry* 1998; **55**:433-40. Comment in: *Arch Gen Psychiatry* 2000; **57**:511-2.
12. Wright IC, Rabe-Hesketh S, Woodruff PW, David AS, Murray RM, Bullmore ET. Meta-analysis of regional brain volumes in schizophrenia. *Am J Psychiatry* 2000; **157**:16-25.
13. Choi JS, Kang DH, Park JY, Jung WH, Choi CH, Chon MW, et al. Cavum septum pellucidum in subjects at ultra high risk for psychosis: compared with first degree relatives of patients with schizophrenia and healthy volunteers. *Prog Neuropsychopharmacol Biol Psychiatry* 2008; **32**:1326-30. Epub 2008 Apr 22.
14. Dickey CC, McCarley RW, Xu ML, Seidman LJ, Voglmaier MM, Niznikiewicz MA, et al. MRI abnormalities of the hippocampus and cavum septi pellucidi in females with schizotypal personality. *Schizophr Res* 2007; **89**:49-58. Epub 2006 Oct 5.
15. Heier LA, Bauer CJ, Schwartz L, Zimmerman RD, Morgello S, Deck MD. Large Virchow-Robin spaces: MR-clinical correlation. *Am J Neuroradiol* 1989; **10**:929-36.
16. Shenton ME, Dickey CC, Frumin M, McCarley RW. A review of MRI findings in schizophrenia. *Schizophr Res* 2001; **49**:1-52.
17. Kubicki M, Styner M, Bouix S, Gerig G, Markant D, Smith K, et al. Reduced interhemispheric connectivity in schizophrenia-tractography based segmentation of the corpus callosum. *Schizophr Res* 2008; **106**:125-31.
18. Cowell PE, Kostianovsky DK, Gur RC, Turetsky BI, Gur RE. Sex differences in neuroanatomical and clinical correlation of schizophrenia. *Am J Psychiatry* 1996; **153**:799-805.
19. Lawrie SM, Abukmeil SS. Brain abnormalities in schizophrenia: a systematic and quantitative review of volumetric magnetic resonance imaging studies. *Br J Psychiatry* 1998; **172**:110-20. Comment in: *Br J Psychiatry* 1999; **175**:388-9.
20. Pearlson GD. Neurobiology of schizophrenia. *Ann Neurol* 2000; **48**:556-66.
21. Naqvi HA. Schizophrenia: a concept. *J Pak Med Assoc* 2008; **58**:133-7.

